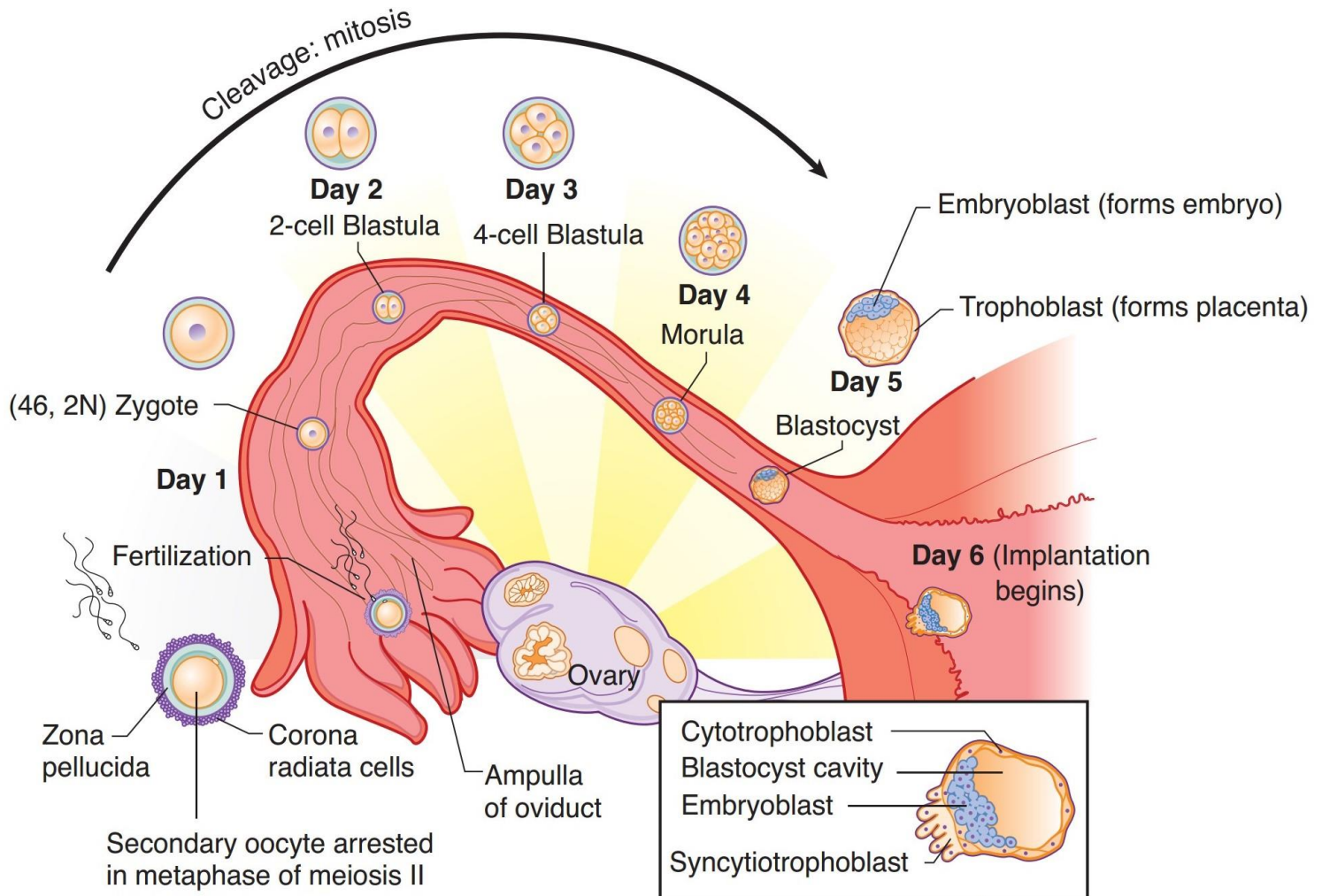


# CHAPTER 1

# Embryology

## Early fetal development



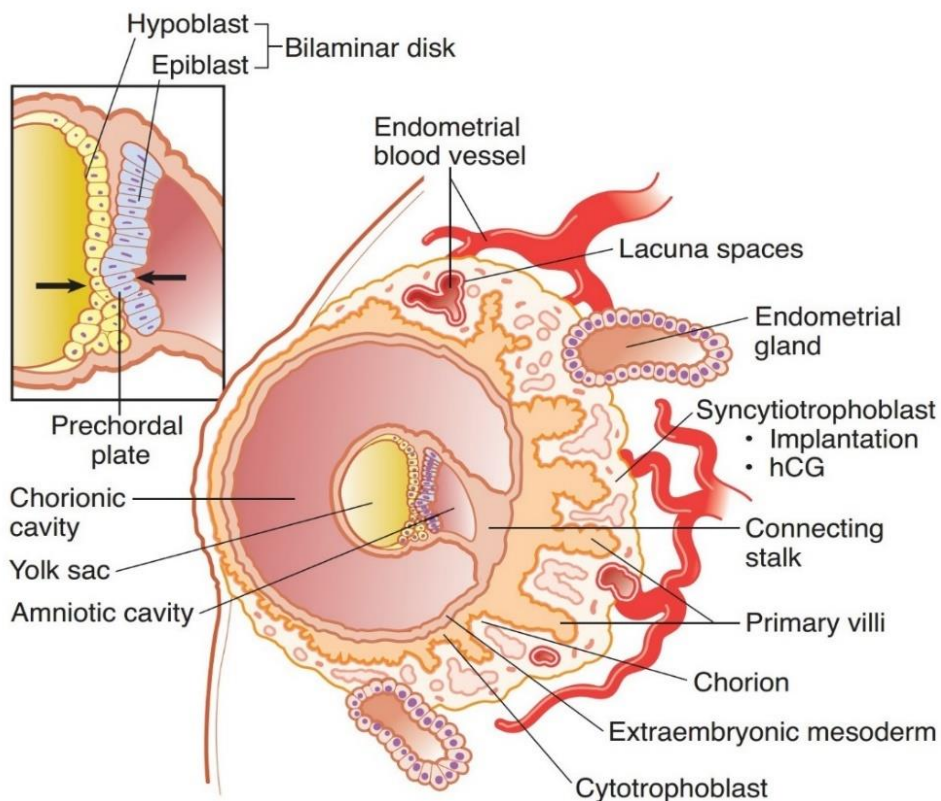
## Week 1: Beginning of Development

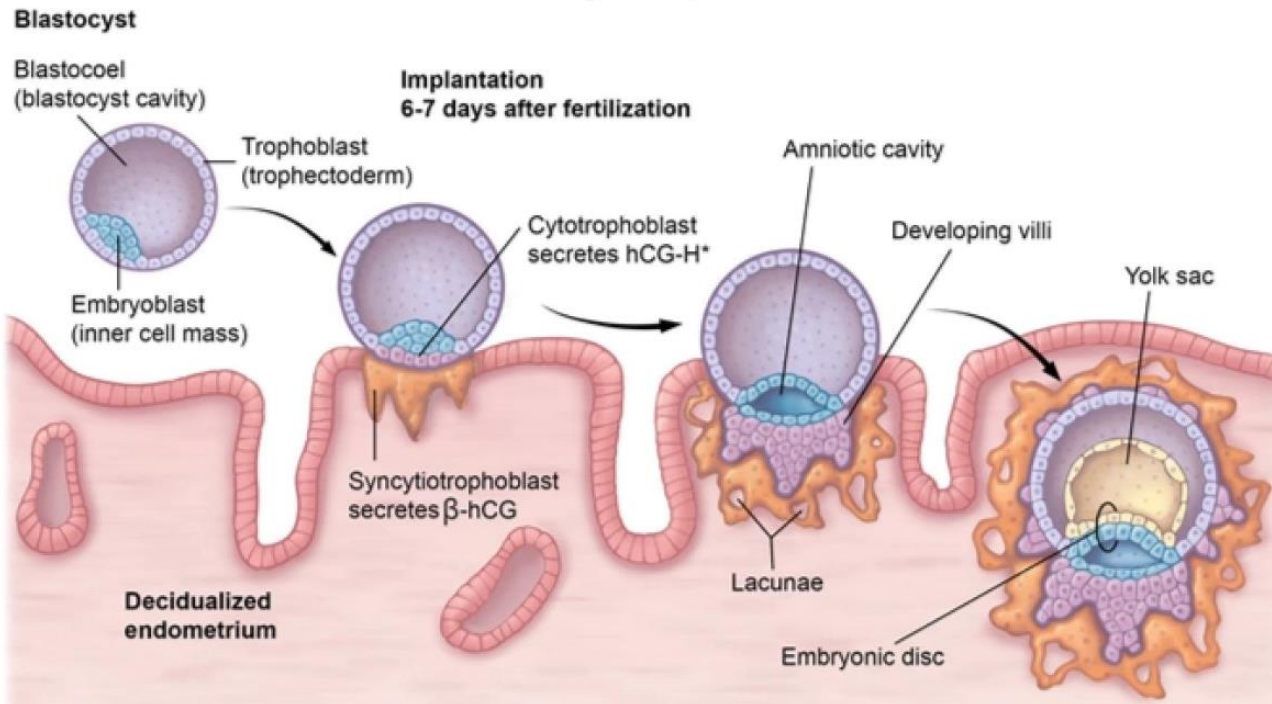
- Fertilization occurs in the ampulla of the uterine tube when the male and female pronuclei fuse to form a zygote.
- After fertilization, the zygote travels through the isthmus of the oviduct and enters the uterus as a 2- to 8-celled embryo or multicellular morula on day 3-4 post-ovulation.
- The morula then develops into a blastocyst which remains freely floating in the uterine cavity until 5-6 days after ovulation.

- $\beta$ -hCG produced by the human conceptus becomes detectable in maternal serum **only after the blastocyst successfully implants**. Implantation generally occurs **on day 6 after ovulation**.
- $\beta$ -hCG is produced by the syncytiotrophoblast after implantation, which generally occurs 6-7 days after fertilization at the earliest.  **$\beta$ -hCG typically is detectable in the maternal serum approximately 8 days after fertilization**, whereas it is detectable in the urine 14 days after fertilization. Therefore, a serum pregnancy test will be positive before a urine pregnancy test.

## Week 2

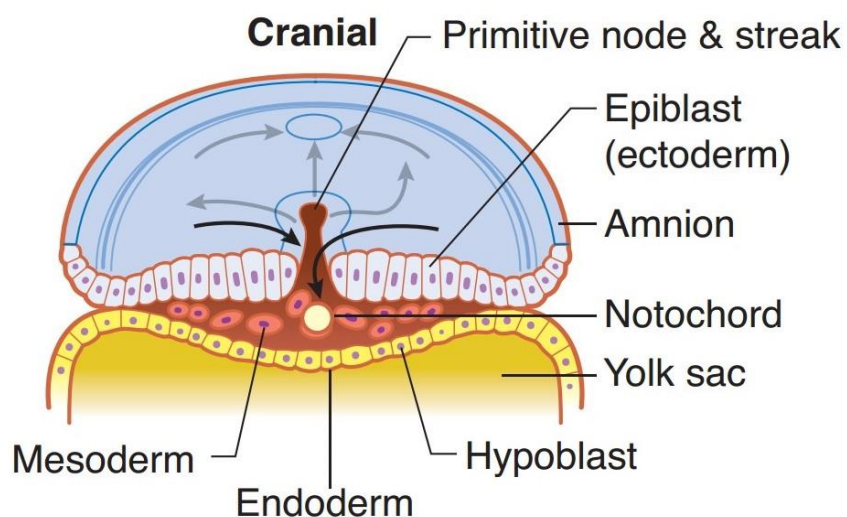
- Formation of the Bilaminar Embryo (2 weeks = 2 layers).
- The embryoblast differentiates into the **epiblast and hypoblast**, forming a **bilaminar embryonic disk**.
- The epiblast forms  $\rightarrow$  the amniotic cavity and hypoblast cells migrate to form  $\rightarrow$  the primary yolk sac.
- The prechordal plate, formed from fusion of epiblast and hypoblast cells, is **the site of the future mouth**.
- The syncytiotrophoblast continues its growth into the endometrium to make contact with endometrial blood vessels and glands.





### Week 3

- **Gastrulation:** process that produces the 3 primary germ layers: ectoderm, mesoderm, and endoderm (3 weeks = 3 layers).
- It begins with the formation of the primitive streak within the epiblast (**invagination of epiblast**).
- Ectoderm forms neuroectoderm and neural crest cells.





### Embryonic Period (Weeks 3-8)

- Neural tube formed by neuroectoderm and closes by week 4.
- **Organogenesis**: all major organ systems begin to develop during the embryonic period (weeks 3-8).
- By the end of this period, the embryo begins to look human.
- **Extremely susceptible to teratogens.**

### Week 4

- Heart begins to beat.
- Upper and lower limb buds begin to form.
- **4 weeks = 4 limbs and 4 heart chambers.**

### Week 6

- Fetal cardiac activity visible by transvaginal ultrasound.

### Week 8

- Fetal movements start (**Gait** at week **8**).

### Week 10

- Genitalia have male/female characteristics. **Tenitalia.**
- Prior to week 10, genitalia look similar for males/females.
- Ultrasound identification of gender: usually week 15 to 20.

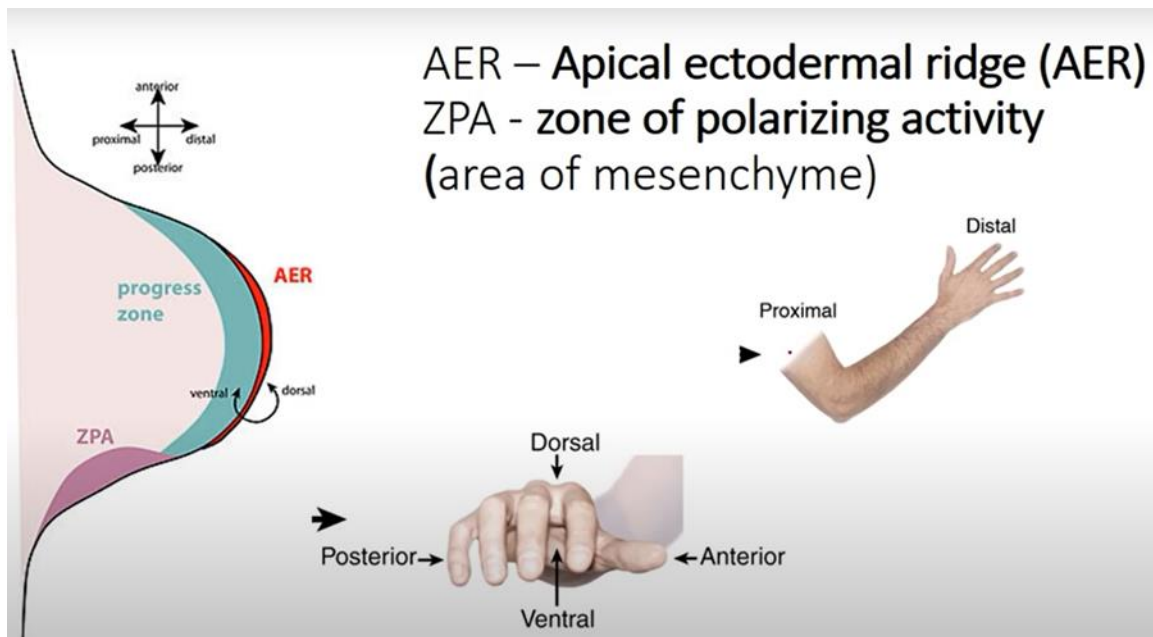
## Embryologic derivatives

Ectoderm		External/outer layer
<b>A. Surface ectoderm</b>	Epidermis; <b>adenohypophysis (from Rathke pouch)</b> ; lens of eye; epithelial linings of oral cavity, sensory organs of ear, and olfactory epithelium; anal canal below the pectinate line; parotid, sweat, mammary glands.	
<b>B. Neuroectoderm</b>	Brain (neurohypophysis, CNS neurons, oligodendrocytes, astrocytes, ependymal cells, pineal gland), retina, spinal cord.	Neuroectoderm: <b>think CNS</b> .
<b>C. Neural crest</b>	<b>Melanocytes, Odontoblasts, Tracheal cartilage, Enterochromaffin cells, Leptomeninges (arachnoid, pia), PNS ganglia (cranial, dorsal root, autonomic), Adrenal medulla, Schwann cells, Spiral membrane (aorticopulmonary septum), Endocardial cushions (also derived partially from mesoderm), Skull bones.</b>	<b>MOTEL PASSES</b>  Neural crest: <b>think PNS</b> and non-neural structures nearby.
<b>Mesoderm</b>	Muscle, bone, connective tissue, serous linings of body cavities (peritoneum, pericardium, pleura), spleen (develops within foregut mesentery), cardiovascular structures, lymphatics, blood, wall of gut tube, upper vagina, kidneys, adrenal cortex, dermis, testes, ovaries, microglia.  Notochord induces ectoderm to form neuroectoderm (neural plate); its only postnatal derivative is the nucleus pulposus of the intervertebral disc.	<b>Middle/"meat" layer.</b> Mesodermal defects = <b>VACTERL</b> : <b>V</b> ertebral defects <b>A</b> nal atresia <b>C</b> ardiac defects <b>T</b> racheo- <b>E</b> sophageal fistula <b>R</b> enal defects <b>L</b> imb defects (bone and muscle)
<b>Endoderm</b>	Gut tube epithelium (including anal canal above the pectinate line), most of urethra and lower vagina (derived from urogenital sinus), luminal epithelial derivatives (lungs, liver, gallbladder, pancreas, eustachian tube, thymus, parathyroid, thyroid follicular cells).	<b>"Enternal" layer.</b>

## ❖ N.B:

- Adrenal **cortex** is derived from **mesoderm**, while adrenal **medulla** is derived from **neural crest cells**.
- Anterior pituitary originates from the Rathke's pouch (surface ectoderm)**, which is an embryonic invagination of the pharyngeal epithelium, while **posterior pituitary** is derived from **neuroectoderm**.

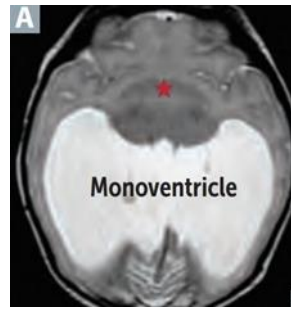
## Important genes of embryogenesis



- Limbs develop along three planes:
  - Proximal to distal: humerus → radius → wrist.
  - Dorsal to ventral axis: (dorsal: Extensors, Ventral: Flexors).
  - Anterior-posterior axis:
    - Anterior: towards thumb.
    - Posterior: towards ulnar fingers.

## Sonic hedgehog (SHH) gene

- Makes Sonic Hedgehog protein.
- Embryonic signaling protein.
- Many embryonic roles (CNS and Limb development):
  - A. CNS development:
    - Formation of forebrain (prosencephalon).
    - Signaling to separate right and left brain → Establishes midline.
    - Mutation can cause **holoprosencephaly (Single-lobed brain)**.



#### B. Limb development:

- Produced at base of limbs in **zone of polarizing activity**.
- Involved in patterning along **anteroposterior axis**.

#### Fibroblast growth factor (FGF) gene

- Produced at **apical ectodermal ridge**:
  - Area of limb bud formation.
  - Ectoderm overlying mesoderm.
  - Removal → Limb stops growing.
  - Influences underlying mesodermal growth.
- Stimulates mitosis of underlying mesoderm, **providing for lengthening of limbs** (proximal to distal development).
- Look at that **Fetus, Growing Fingers**.

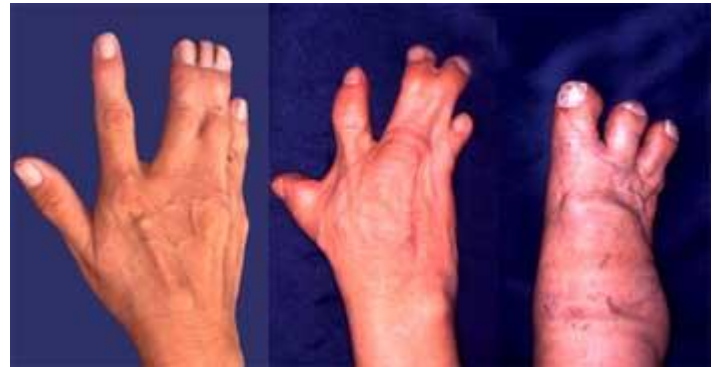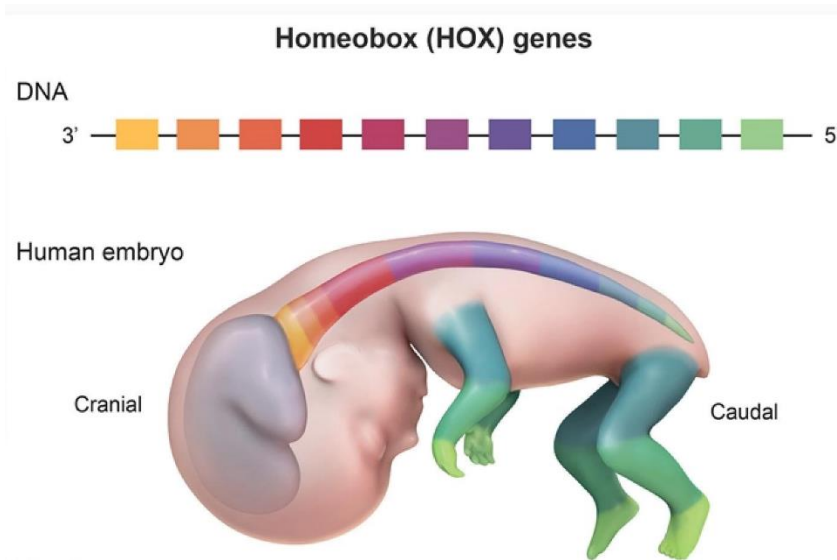
#### Wnt-7 gene

- Produced at **apical ectodermal ridge** (thickened ectoderm at distal end of each developing limb).
- Necessary for **proper organization along dorsal-ventral axis** (dorsalizes limb).

#### Homeobox (Hox) genes

- Code for transcription factors.
- These genes typically code for **transcription factors** that bind to regulatory regions on DNA, **altering the expression of genes involved in the segmental organization of the embryo**.
- **Proper morphogenesis ensures that tissues, organs, and structural elements of the body are formed in the correct position along the cranio-caudal axis.**
- Involved in **segmental organization of embryo in a craniocaudal direction**.
- Regulators of **AP axis development of the limb**.

- Homeobox gene mutations interrupt this developmental process, often resulting in severe abnormalities such as skeletal malformations and improperly positioned limbs and appendages:
  - Polydactyly (extra fingers/toes).
  - Syndactyly (fused fingers/toes).



Limb axis	Area	Involved gene
Proximal to distal	Apical ectodermal ridge	Fibroblast growth factor gene.
Dorsal-ventral	Apical ectodermal ridge	Wnt-7 gene.
Anterior-posterior	Zone of polarizing activity	Sonic hedgehog gene, Homeobox genes (also craniocaudal).



## Types of errors in organ morphogenesis

### A. Interinsic:

- Failure of embryo to develop **due to abnormal genes or other internal processes**.
- Examples:
  1. Agenesis:
    - **Absent** organ due to **absent primordial tissue**.
    - Example: renal agenesis.
  2. Aplasia:
    - **Absent** organ despite **presence of primordial tissue**.
    - Example: thymic aplasia.
  3. Hypoplasia:
    - **Incomplete organ development**; primordial tissue **present**.
    - Example: microcephaly.
  4. Malformation:
    - Describes a primary defect in the cells or tissues that form an organ (an **intrinsic** developmental abnormality).
    - **Occurs during embryonic period** (weeks 3-8).
    - Example: **Arnold Chiari malformation**.

### B. Extrinsic:

- External force impacts normal development.
- The pressure applied by the uterus is one of the most common external forces.
- Examples:
  1. Disruption:
    - Describes **secondary breakdown of a previously normal tissue or structure**.
    - Example: amniotic band syndrome, rupture of the amnion during fetal development may produce amniotic bands which can compress or even amputate fetal limbs.
  2. Deformation:
    - Describes fetal structural anomalies that occur due to **extrinsic** mechanical forces.
    - **Occurs after embryonic period**.
    - Example: potter syndrome (**clubbed feet and flat facies**) secondary to extrinsic compression by the uterus.

## Teratogens

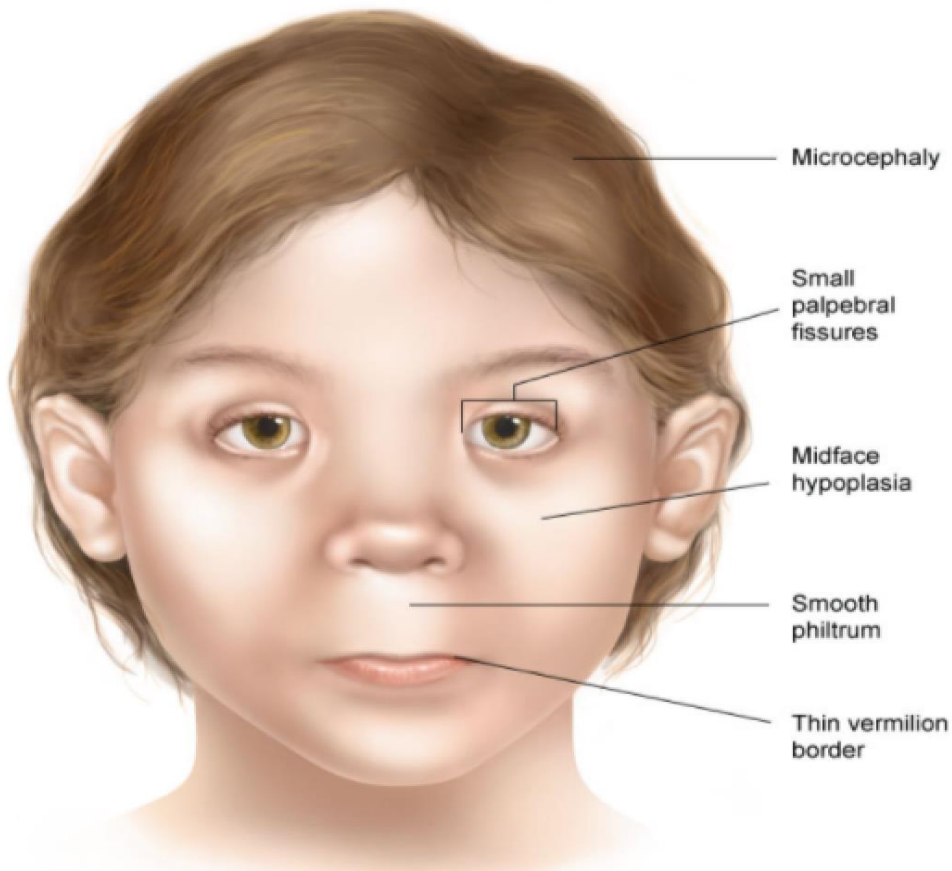
- Most susceptible in 3<sup>rd</sup> - 8<sup>th</sup> weeks (**embryonic period of organogenesis**) of pregnancy.
- Before** week 3 → “**all-or-none**” effects.
- After** week 8 → **growth and function affected, but usually no birth defect**.

Teratogen	Effects on fetus	Notes
<b>Medications</b>		
<b>ACE inhibitors</b>	<b>Renal failure</b> , oligohydramnios, hypocalvaria.	Angiotensin II is <b>necessary for normal renal development</b>
<b>Alkylating agents</b>	Absence of digits, multiple anomalies	
<b>Aminoglycosides</b>	Ototoxicity	A <b>mean guy</b> hit the baby in the ear.
<b>Antiepileptic drugs</b>	<b>Neural tube defects</b> , cardiac defects, cleft palate, skeletal abnormalities (phalanx/nail hypoplasia, facial dysmorphism)	<b>High-dose folate supplementation recommended.</b>  Most commonly valproate, carbamazepine, phenytoin, phenobarbital.
<b>Diethylstilbestrol</b>	Vaginal clear cell adenocarcinoma, congenital Müllerian anomalies	
<b>Fluoroquinolones</b>	Cartilage damage	
<b>Folate antagonists</b>	Neural tube defects	Includes trimethoprim, methotrexate, antiepileptic drugs.
<b>Isotretinoin</b>	Multiple severe birth defects	Contraception is mandatory.
<b>Lithium</b>	Ebstein anomaly (apical displacement of tricuspid valve)	
<b>Methimazole</b>	Aplasia cutis congenita (congenital absence of skin, particularly on scalp)	
<b>Tetracyclines</b>	Discolored teeth, inhibited bone growth	“ <b>Teeth</b> racyclines”
<b>Thalidomide</b>	Limb defects (phocomelia, micromelia “flipper limbs”)	Limb defects with “tha- <b>limb</b> -domide.”
<b>Warfarin</b>	Bone deformities, fetal hemorrhage, abortion, ophthalmologic abnormalities	Do not wage <b>warfare</b> on the baby; keep it <b>heppy</b> with <b>heparin</b> (does not cross placenta).
<b>Substance abuse</b>		
<b>Alcohol</b>	Common cause of birth defects and intellectual disability; fetal alcohol syndrome	
<b>Cocaine</b>	Low birth weight, preterm birth, IUGR, placental abruption	Cocaine → vasoconstriction.
<b>Smoking (nicotine, CO)</b>	Low birth weight (leading cause in developed countries), preterm labor, placental problems, IUGR, SIDS	Nicotine → vasoconstriction. CO → impaired O <sub>2</sub> delivery.

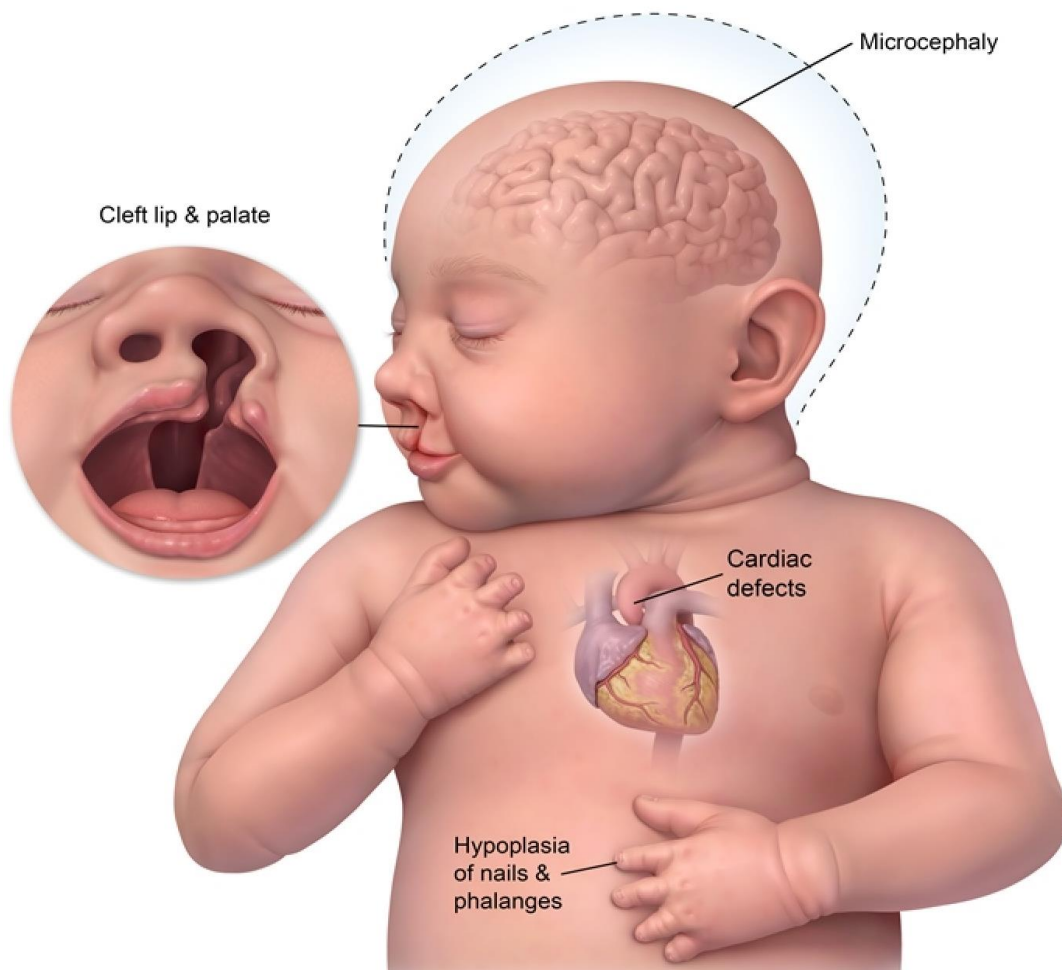
Other		
<b>Iodine (lack or excess)</b>	Congenital goiter or hypothyroidism (cretinism)	
<b>Maternal diabetes</b>	Caudal regression syndrome, cardiac defects (VSD), neural tube defects, macrosomia, neonatal hypoglycemia (due to islet cell hyperplasia), polycythemia.	
<b>Methylmercury</b>	Neurotoxicity	Highest in swordfish, shark, tilefish, king mackerel.
<b>Vitamin A excess</b>	Extremely high risk for spontaneous abortions and birth defects (cleft palate, cardiac)	
<b>X-rays</b>	Microcephaly, intellectual disability	Minimized by lead shielding.

### Fetal alcohol syndrome

- Fetal alcohol syndrome (FAS) is **one of the leading preventable causes of birth and neurodevelopmental problems**.
- Alcohol cross the placenta (teratogenic) → cross the Blood-Brain barrier of the fetus.
- **Although in utero alcohol exposure may result in no apparent sequelae for some fetuses, others may suffer from FAS or be stillborn.** Women who are pregnant or trying to conceive should be advised to abstain completely from alcohol as there is **no known safe amount of prenatal alcohol consumption**.
- FAS is characterized by 3 pathognomonic facial dysmorphisms:
  - **Small palpebral fissures.**
  - **Smooth philtrum** (vertical groove above the upper lip).
  - **Thin vermilion border.**
- **Microcephaly is often present, and these children suffer from cognitive and behavioral disorders.** The phenotypic range of neurodevelopmental problems is wide and includes intellectual disability, attention-deficit hyperactivity disorder, social withdrawal, and delays in motor and language milestones.
- One mechanism is due to **impaired migration of neuronal and glial cells**.
- Heart defects (Heart-lung fistulas in most severe form).
- Early diagnosis is critical for affected children to **benefit from aggressive speech, physical, and occupational therapies**.

**Fetal alcohol syndrome****Fetal hydantoin syndrome**

- Fetal hydantoin syndrome occurs due to **in utero exposure to an antiepileptic (phenytoin, carbamazepine, valproate)**.
- Multiple antiepileptics have teratogenic effects **due to their ability to cross the placenta, resulting in low folate levels and high oxidative metabolites levels in the fetus**.
- The likely combined effects result in the associated **clef lip and palate, wide anterior fontanelle, distal phalange hypoplasia, and cardiac anomalies (pulmonary stenosis, aortic stenosis)**.
- **The associated neural tube defects and microcephaly** can also result in developmental delay and poor cognitive outcomes.
- Therefore, to minimize the risk of congenital malformation, patients who require antiepileptics during pregnancy **should be titrated to the lowest dose for seizure control prior to conception and started on high-dose (4 mg) folic acid supplementation**.

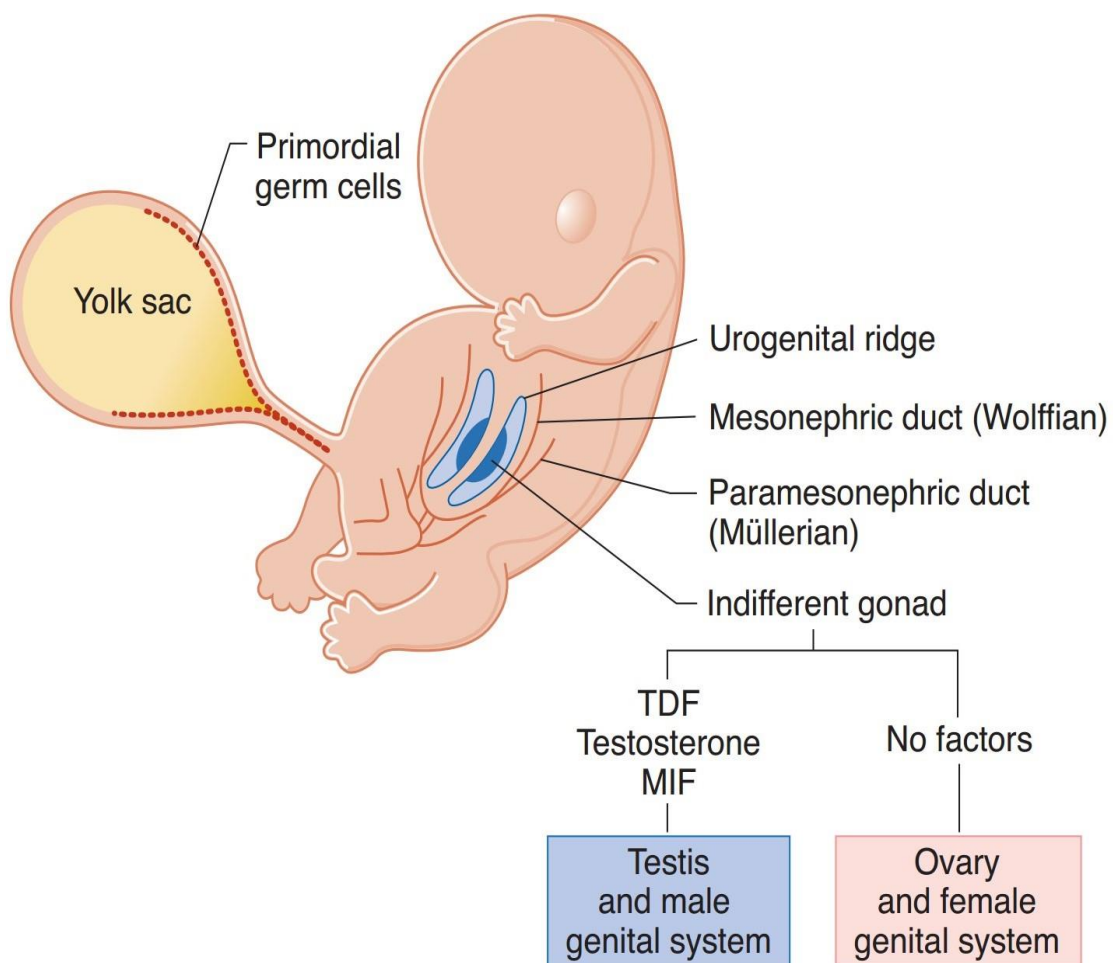
**Fetal hydantoin syndrome****Neonatal abstinence syndrome**

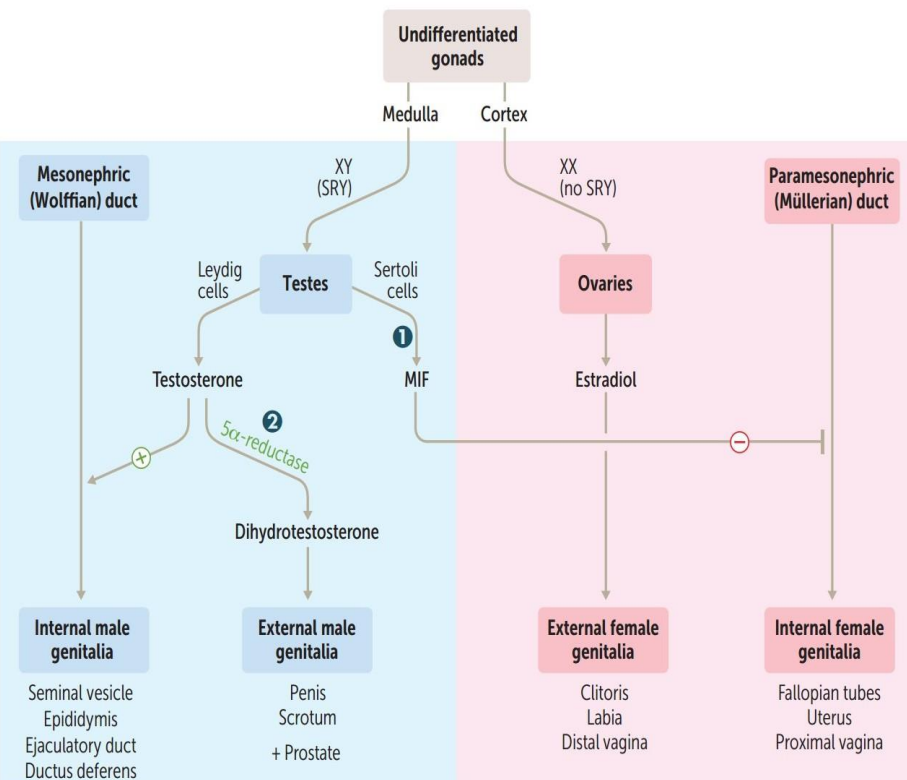
- Complex disorder involving CNS, ANS, and GI systems.
- Secondary to maternal substance use/ abuse (**most commonly opioids**).
- Universal screening for substance abuse is recommended in all pregnant patients.
- Newborns may present with **uncoordinated sucking reflexes, irritability, high-pitched crying, tremors, tachypnea, sneezing, diarrhea, and possibly seizures**.
- Treatment (for opiate abuse): methadone, morphine, buprenorphine.



### Gonad development

- Although the genetic sex is determined at fertilization, the gonads and external genitalia are initially undifferentiated.
- During the first six weeks of gestation, the embryo has gonads (a pair of primitive indifferent gonads), paramesonephric (mullerian) ducts and mesonephric (wolffian) ducts, a genital tubercle (phallus), urethral folds and genital swellings.
- The indifferent gonads develop in a longitudinal elevation or ridge of intermediate mesoderm called the urogenital ridge.
- Primordial germ cells arise from the lining cells in the wall of the yolk sac.
- At week 4, primordial germ cells migrate into the indifferent gonad and provide a critical inductive influence on gonad development.
- Differentiation of the reproductive system occurs in the following sequence: gonadal development, genital duct development, and external genitalia development.



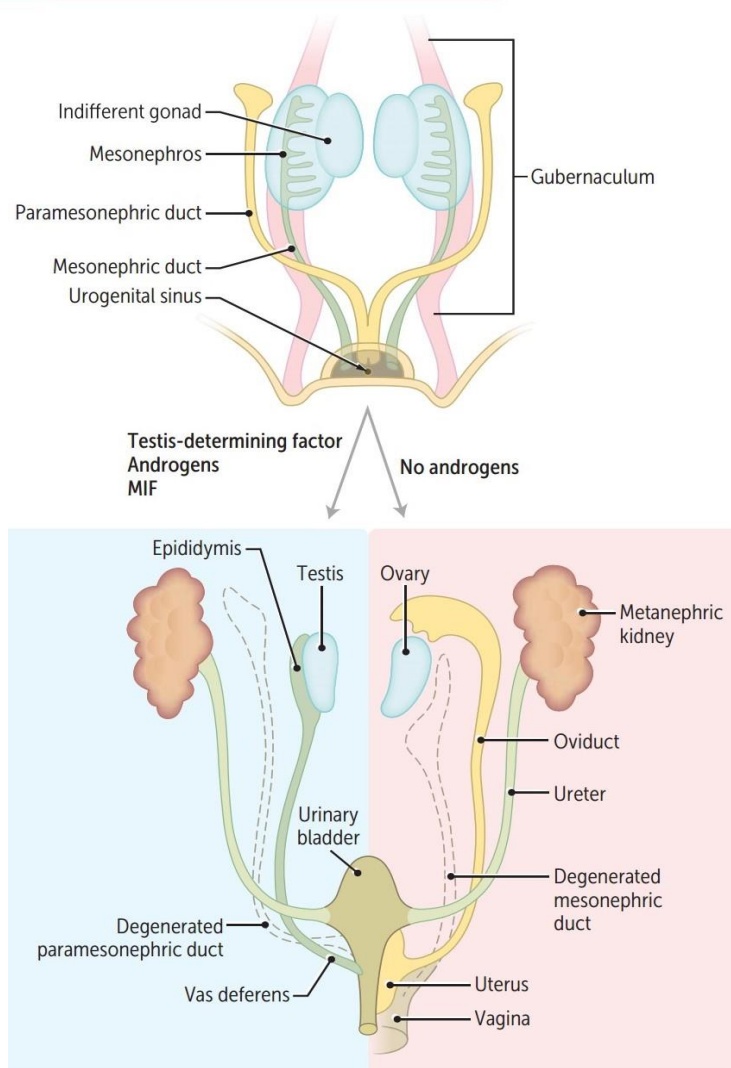


- 1 Absence of Sertoli cells or lack of Müllerian inhibitory factor  $\rightarrow$  develop both male and female internal genitalia and male external genitalia (streak gonads)
- 2 5 $\alpha$ -reductase deficiency—inability to convert testosterone into DHT  $\rightarrow$  male internal genitalia, ambiguous external genitalia until puberty (when  $\uparrow$  testosterone levels cause masculinization)

In the testes:

**L**eydig **L**eads to male (internal and external) sexual differentiation.

**S**ertoli **S**huts down female (internal) sexual differentiation.



**1. Gonadal stage:**

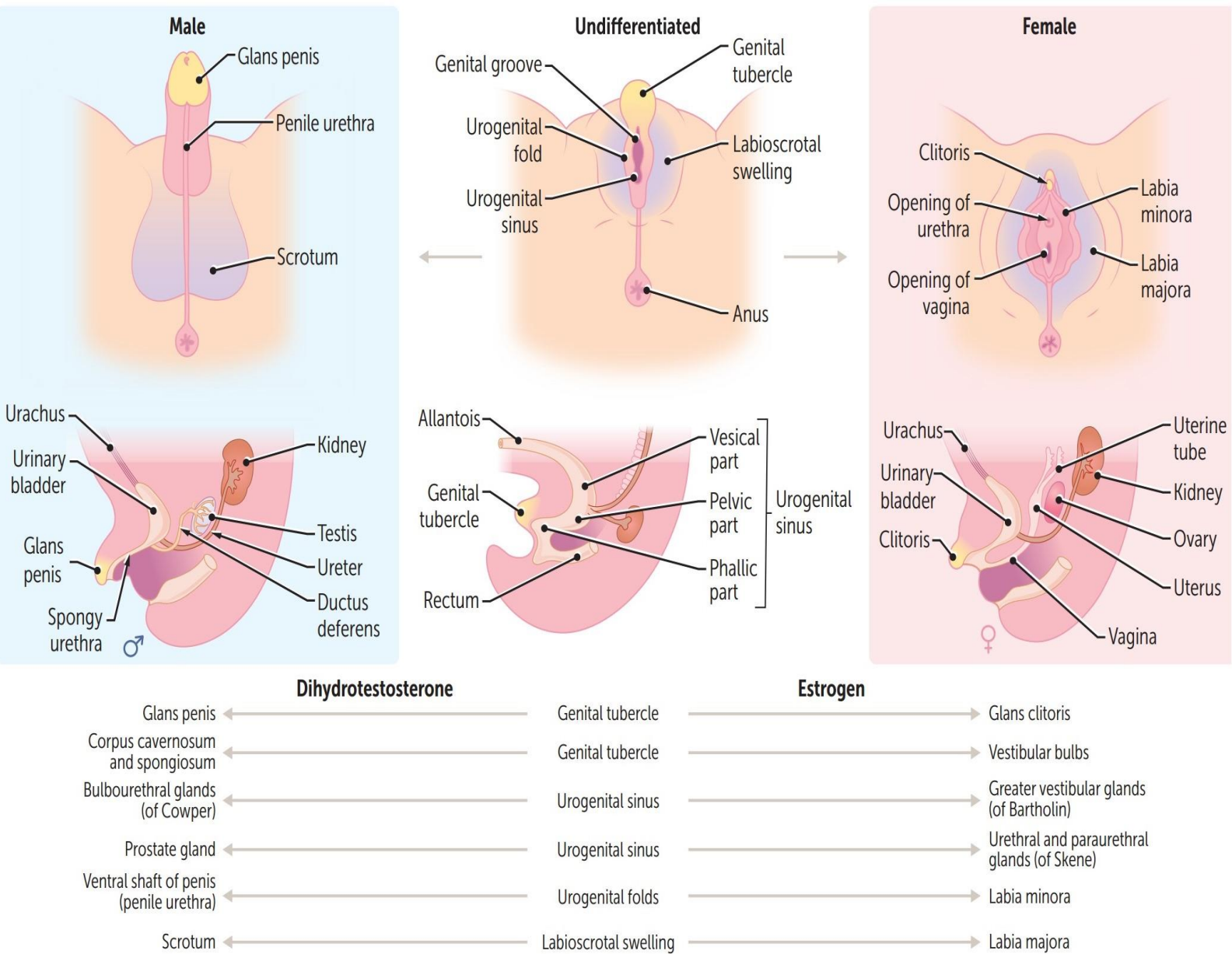
- The primitive gonads develop from the genital ridges and can differentiate into either male testes or female ovaries.
- The presence of a Y chromosome induces the development of male gonads.
- The SRY gene on the Y chromosome codes for the testes-determining factor (TDF), which is responsible for gonadal differentiation into testes.
- The absence of a Y chromosome causes the default female pattern of gonadal development (Mesonephric duct degenerates and paramesonephric duct develops).

**2. Ductal stage:**

- The testes contain Sertoli cells and Leydig cells.
- The Sertoli cells produce mullerian-inhibiting factor (MIF) that prevents development of female internal genitalia and the Leydig cells secrete testosterone necessary for the development of male internal genitalia.
- Leydig cells secrete testosterone which stimulates the mesonephric (Wolffian) ducts to develop into male internal genitalia (prostate from urogenital sinus).
- Seminal vesicles, Epididymis, Ejaculatory duct, Ductus deferens (SEED).
- Without Sertoli cells or MIF, the mullerian (paramesonephric) ducts give rise to the uterine tubes, uterus, cervix, and upper 1/3 vagina (lower portion from urogenital sinus) under the influence of maternal estrogen and the mesonephric ducts regress.

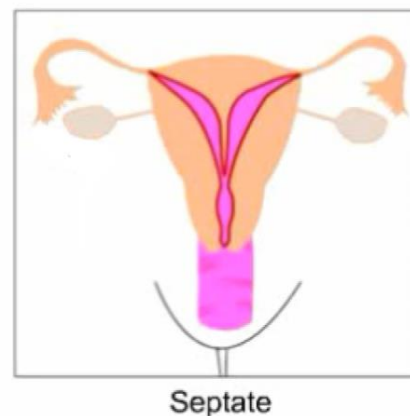
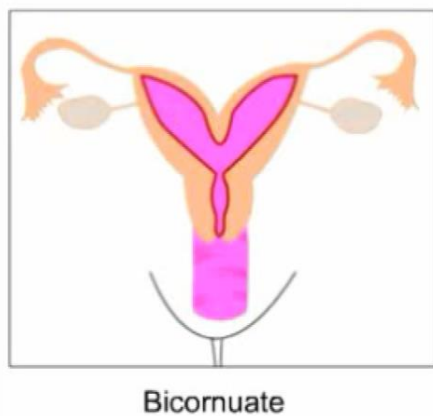
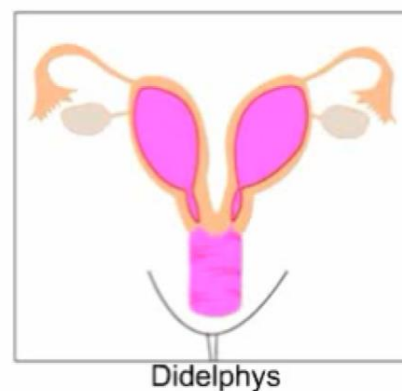
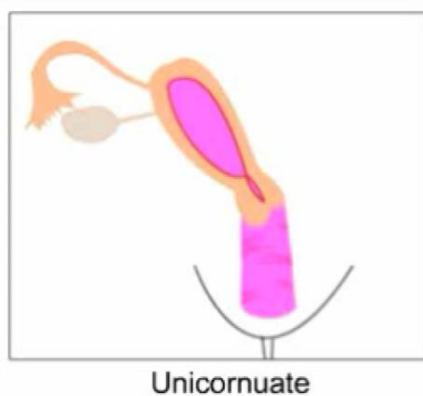
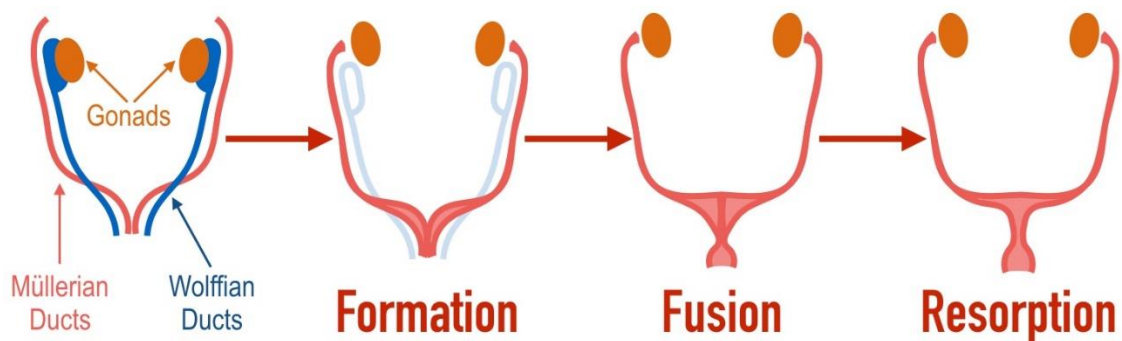
**3. Genital stage:**

- Testosterone is converted into dihydrotestosterone (DHT), which induces development of male-type external genitalia.
- The genital tubercle gives rise to glans penis in males and the glans clitoris in females.
- In the male, the urethral folds fuse to form the ventral aspect of the penis and the penile raphe, which serve as the anterior wall of the urethra.
- In the female, the urethral (urogenital) folds do not fuse and ultimately form the labia minora.
- The genital swellings (labioscrotal swelling) become the scrotum in males and the labia majora in females.
- The urogenital sinus gives rise to the bladder, urethra, prostate, and bulbourethral glands in males. In females, it develops into the bladder, urethra, lower vagina and Bartholin glands.



### Uterine (Müllerian duct) anomalies

- Uterine anomalies are found in **3% of fertile women** with normal reproductive outcomes. Uterine anomalies may result from 3 mechanisms:
  - Stage 1:** failure of one or both of the 2 Müllerian ducts to form.
  - Stage 2:** failure of the 2 ducts to fuse completely.
  - Stage 3:** failure of the 2 fused Müllerian ducts to dissolve the septum that results from fusion.





A. **Failure to Form:**1. Mullerian aplasia/agenesis:

- Also called Mayer-Rokitansky Küster-Hauser syndrome.
- Patients with Mullerian agenesis have primary amenorrhea due to an absent uterus, cervix, and upper 1/3 of the vagina.
- May present as 1° amenorrhea (due to a lack of uterine development) in females with fully developed 2° sexual characteristics (functional ovaries).

2. Unicornuate uterus:

- When one of the Mullerian ducts fails to form, a single-horn (banana-shaped) uterus develops from the healthy Mullerian duct.

B. **Failure to Fuse:**1. Didelphys uterus:

- A double uterus results from the complete failure of the 2 Mullerian ducts to fuse together. So each duct develops into a separate uterus, each of which is narrower than a normal uterus and has only a single horn.
- These 2 uteri may each have a cervix, or they may share a cervix. In 67% of cases, a didelphys uterus is associated with 2 vaginas separated by a thin wall.
- Preterm delivery is common if pregnancy occurs in these patients.

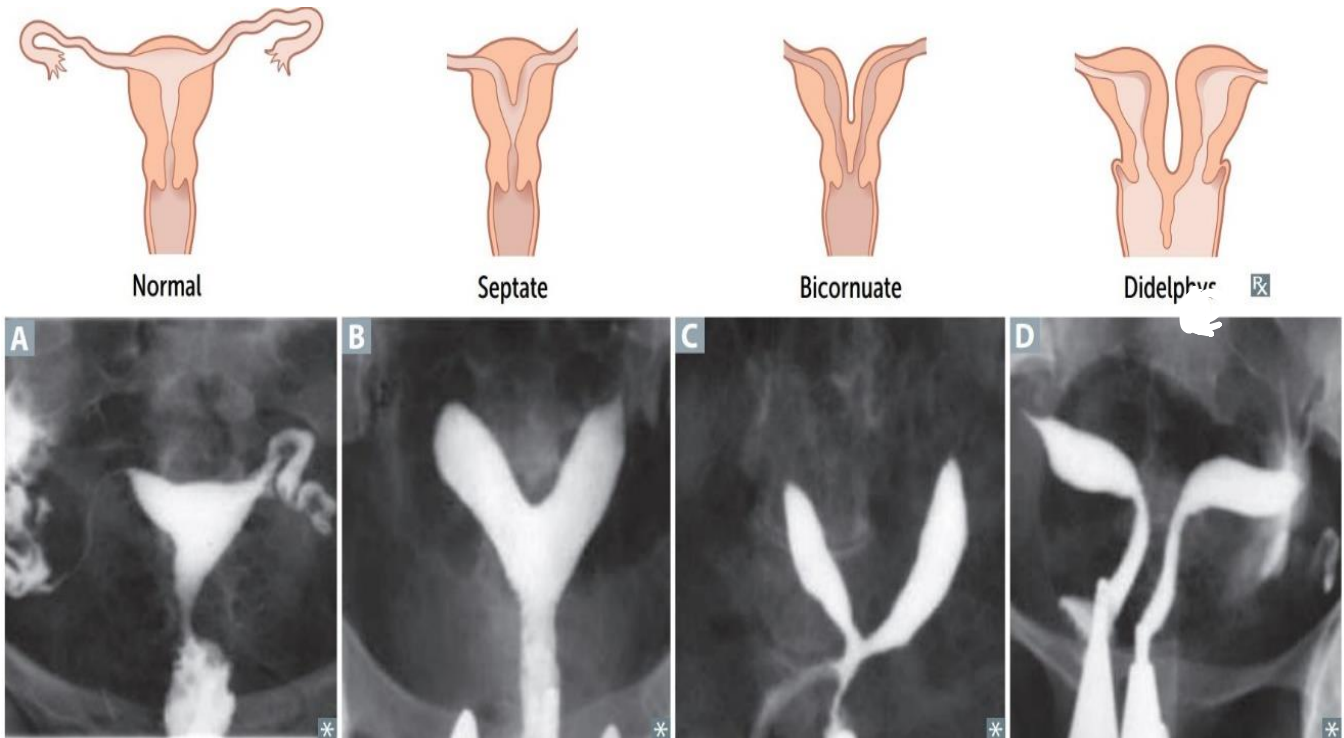
2. Bicornuate uterus:

- It results from a failure of fusion between the mullerian ducts at the top (incomplete fusion).
- Thus, there is a single uterine cavity at the bottom with a single cervix, but it branches into two distinct horns at the top.
- Preterm delivery and malpresentation are common with pregnancy.

C. **Failure to Dissolve Septum (Septate uterus):**

- The two Mullerian ducts fused normally; however, there was a failure in degeneration of the median septum.
- Preterm delivery and malpresentation are common with pregnancy.
- ↓fertility. Treat with septoplasty.

- Hystrogram is a radiographic study that involves introducing radioopaque material into the uterus via the cervical os and subsequently X-raying the pelvic region.

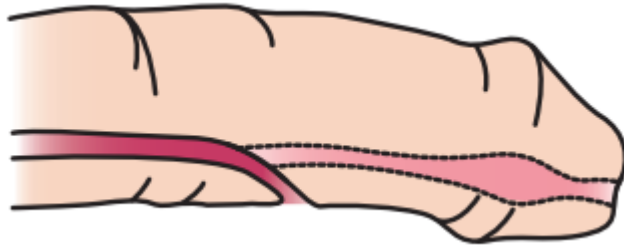


### Congenital penile abnormalities

#### Hypospadias

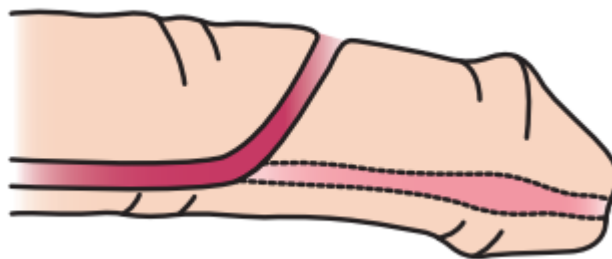
- Abnormal opening of penile urethra on ventral surface of penis **due to failure of urethral folds to fuse**.
- In the female, the urethral (urogenital) folds do not fuse and ultimately form the labia minora.
- In the male, the urethral folds fuse to form the ventral aspect of the penis and the penile raphe, which serve as the anterior wall of the urethra.
- **In males, incomplete fusion of the urethral (urogenital) folds results in an abnormal opening of the urethra proximal to the glans penis along the ventral shaft of the penis.**
- Depending on the degree of nonunion, the urethral opening can be anywhere from the perineum to just proximal to the glans penis.
- **Hypospadias is more common than epispadias.**
- **Associated with inguinal hernia and cryptorchidism.**

- Hypospadias can generally be repaired surgically to allow normal urination and sexual activity.
- Hypo is below.



### Epispadias

- Abnormal opening of penile urethra on dorsal surface of penis due to faulty positioning of genital tubercle.
- Exstrophy of the bladder is associated with Epispadias.
- When you have Epispadias, you hit your Eye when you pee.



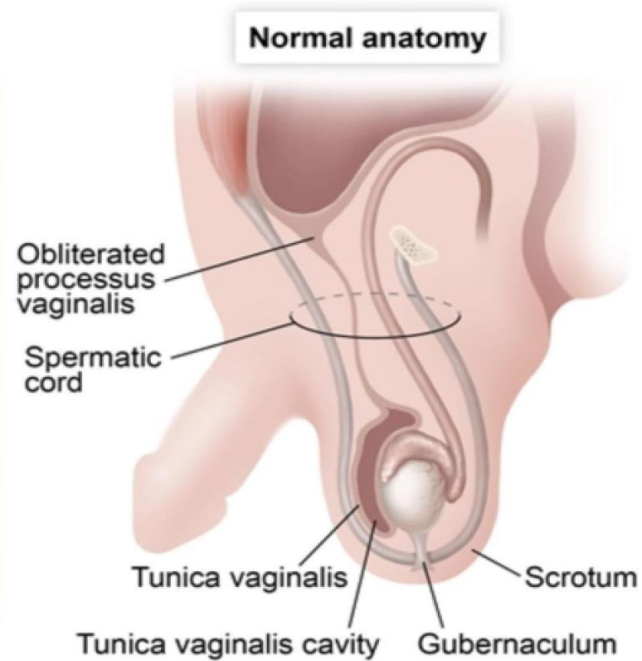
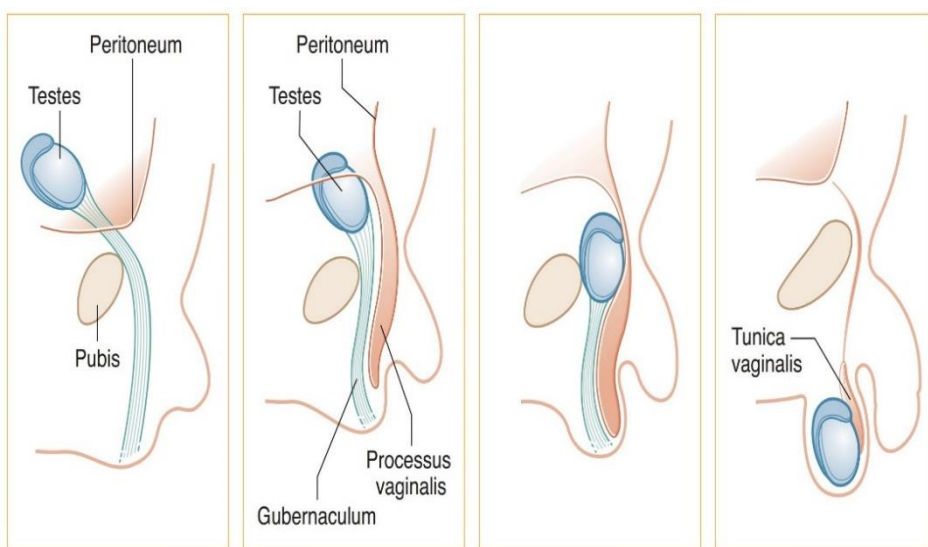
### Descent of testes and ovaries

#### Gubernaculum (band of fibrous tissue)

- As the scrotum and labia majora form in males and females, respectively, the gubernaculum aids in the descent of the gonads (both testes and ovaries).
- The testes descend to a greater degree than the ovaries and ultimately pass through the inguinal canal.
- The gubernaculum is present only during the development of the urinary and reproductive organs, being replaced by distinct vestiges in males and females:
  - Male remnants: Anchors testes within scrotum.
  - Female remnants: Ovarian ligament + round ligament of uterus.

**Processus vaginalis (evagination of peritoneum)**

- **In males:**
  - It precedes the testis in their descent down within the gubernaculum, and closes (Forms tunica vaginalis).
  - Persistent patent processus vaginalis → hydrocele.
- **Female remnants:** Obliterated.



## Twinning

### A. Dizygotic twins:

- Dizygotic twins are most common. Identifiable risk factors include race, geography, family history, or ovulation induction.
- Dizygotic twins result from fertilization of 2 oocytes by 2 different sperm (the sex of the twins may differ) and always have 2 amnions and 2 chorions (dichorionic/diamniotic), but the chorions and placentas may be fused depending on the proximity of the implantation sites.

### B. Monozygotic twins:

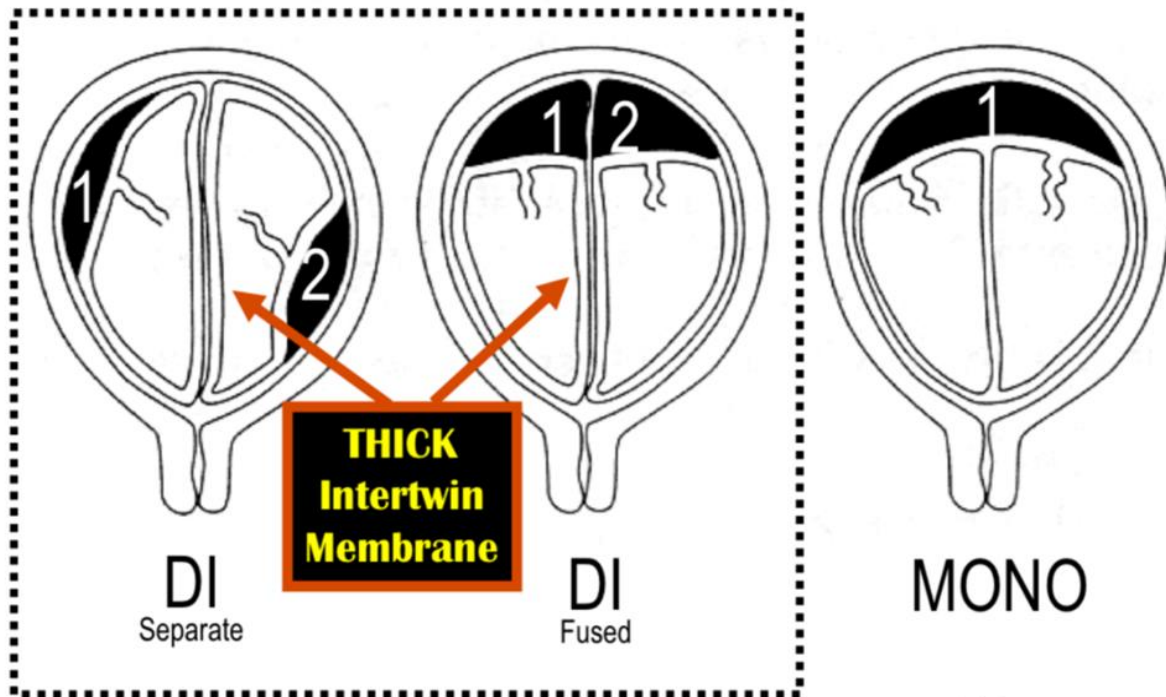
- In contrast, monozygotic twins arise from the fertilization of a single oocyte. They are of the same sex, are genetically identical, and are similar in appearance.
- Monozygotic twinning may occur at different stages of embryogenesis, which affects the organization of the fetal membranes: dichorionic/diamniotic (days 0-4), monochorionic diamniotic (days 4-8), monochorionic monoamniotic (days 8-12), and monochorionic monoamniotic conjoined twins (> 13 days).
- Rarely, early separation (days 0-4) can result in monozygotic twins with 2 amnions, 2 chorions, and 2 placentas that may or may not be fused. In this situation, if the sexes are the same, it may be difficult to distinguish whether the twins are monozygotic or dizygotic until other characteristics develop (or if blood groups are discordant).
- It typically occurs during the end of the first week (days 4-8), giving rise to 2 embryos, each with its own amniotic sac. These develop within 1 chorion and share a common placenta, a monochorionic-diamniotic twin placenta.
- Late division (8-12 days) of monozygotic twins results in 1 amniotic sac and 1 chorionic sac. A monochorionic monoamniotic pregnancy is associated with a high fetal fatality rate, due primarily to the increased risk of umbilical cord entanglement.
- Division occurring after 13 days can result in monoamniotic monochorionic conjoined twins.
- The timing of cleavage determines chorionicity (number of chorions) and amnionicity (number of amnions) (SCAB):
  - Cleavage 0-4 days: Separate chorion and amnion.
  - Cleavage 4-8 days: shared Chorion.
  - Cleavage 8-12 days: shared Amnion.
  - Cleavage 13+ days: shared Body (conjoined).



Note # of layers  
in the septum

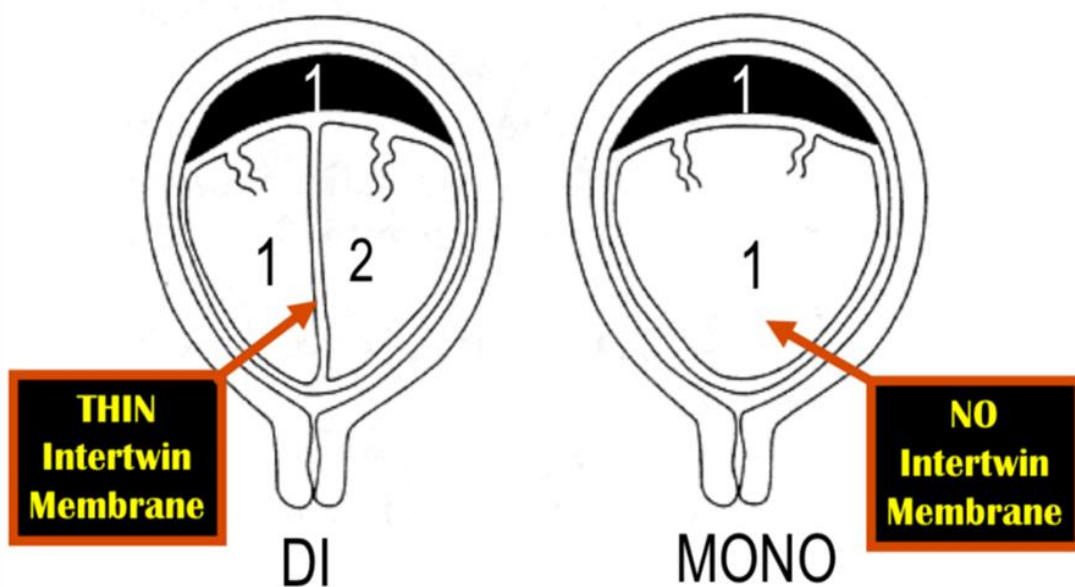
## CHORIONICITY

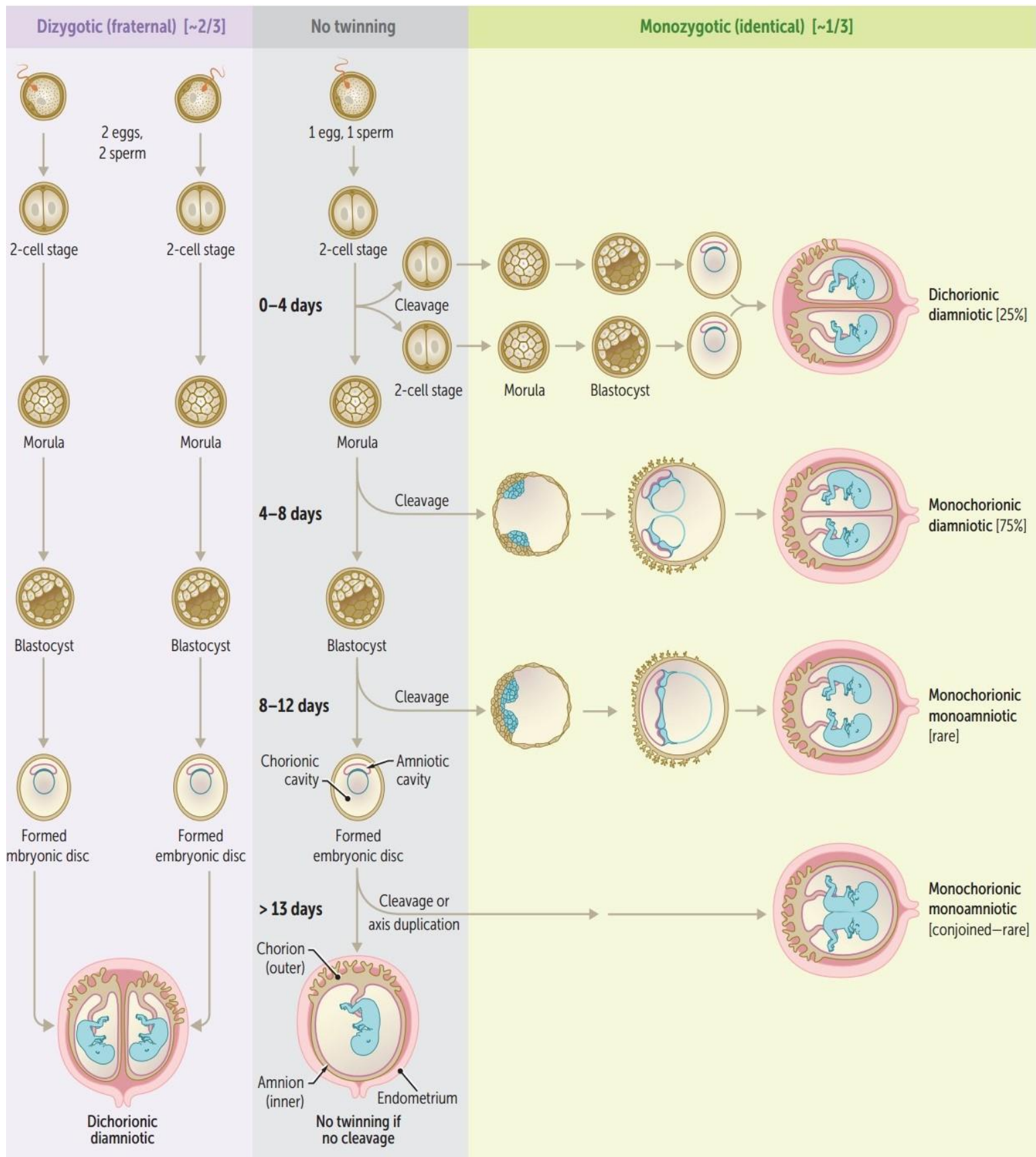
How many placentas?



## AMNIONICITY

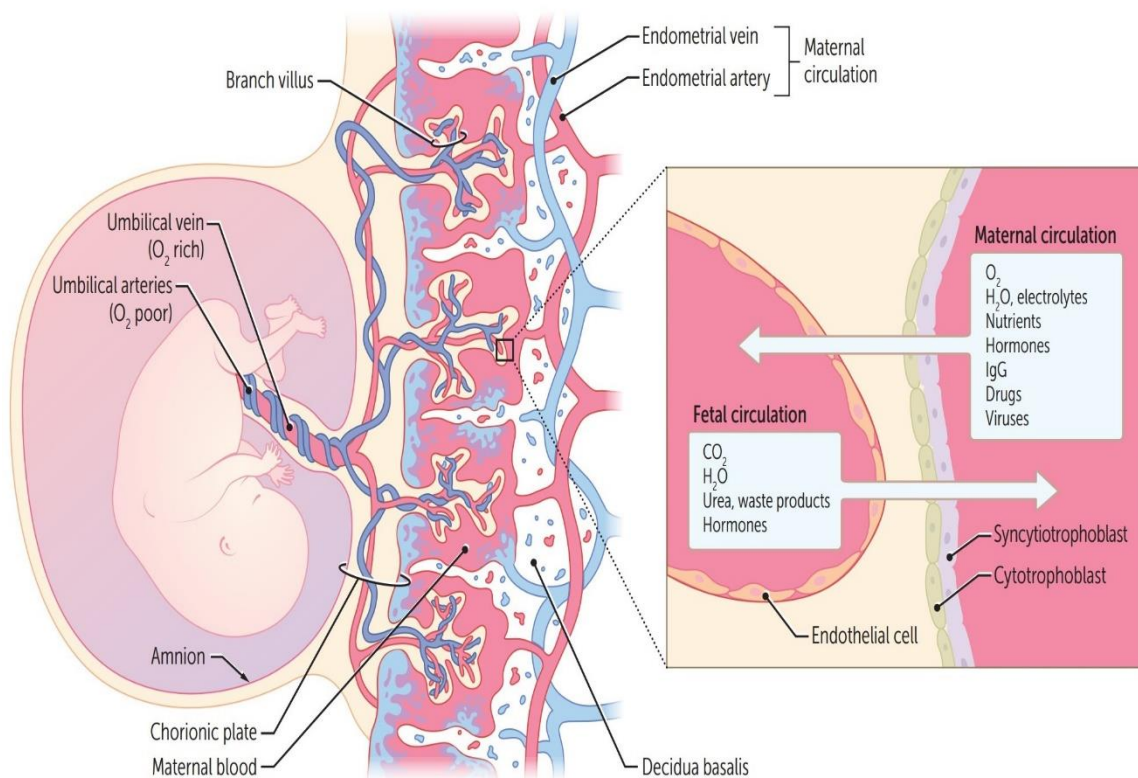
How many sacs?





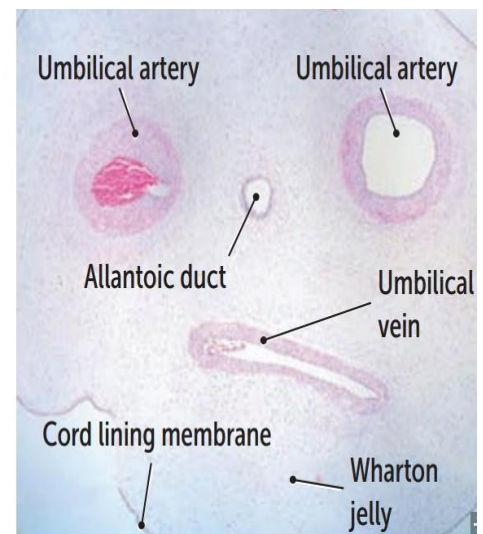
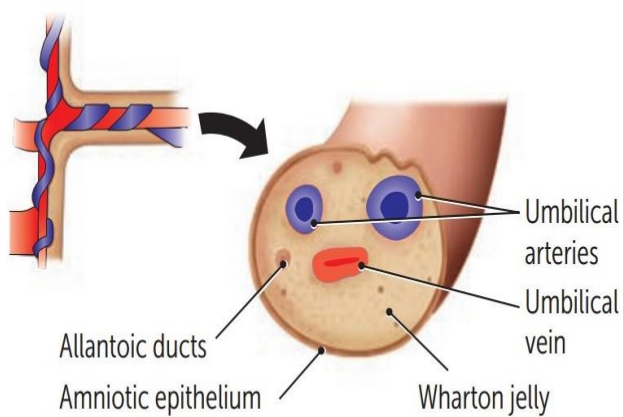
## Placenta

- Placenta is the primary site of nutrient and gas exchange between mother and fetus.
- **Fetal component:**
  1. **Cytotrophoblast:**
    - Inner layer of chorionic villi.
    - Cytotrophoblast makes Cells.
  2. **Syncytiotrophoblast:**
    - Outer layer of chorionic villi; synthesizes and secretes hormones.
    - It secretes hCG (structurally similar to LH; stimulates corpus luteum to secrete progesterone during first trimester).
    - Syncytiotrophoblast synthesizes hormones.
- **Maternal component:**
  - **Decidua basalis:**
    - Derived from endometrium.
    - Maternal blood in lacunae.



### Umbilical cord

- **Two** Umbilical arteries return deoxygenated blood from fetal internal iliac arteries to placenta.
- **One** Umbilical vein supplies oxygenated blood from placenta to fetus; drains into IVC via liver or via ductus venosus.
- Single umbilical artery (2-vessel cord) is associated with congenital and chromosomal anomalies.



## **CHAPTER 2**

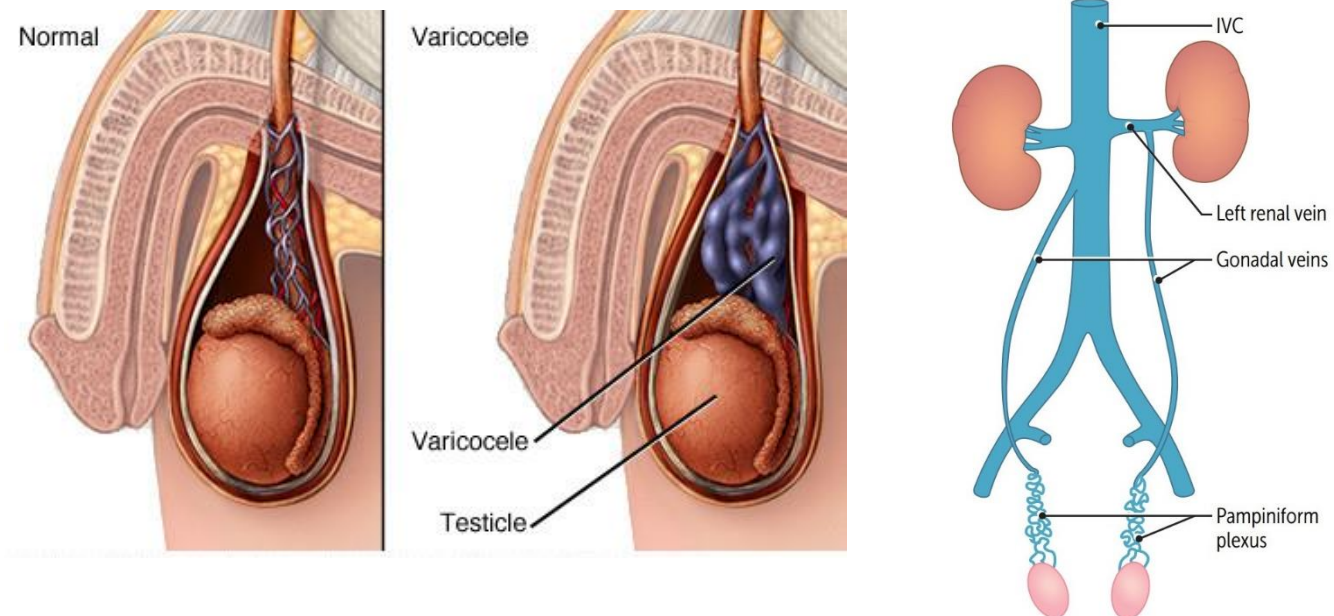
# **Anatomy**



## Gonadal drainage

### A. Venous drainage:

- Left ovary/testis → left gonadal vein → left renal vein → IVC.
- Right ovary/testis → right gonadal vein → IVC.
- “Left gonadal vein takes the Longest way”.
- Because the left spermatic vein enters the left renal vein at a 90° angle, flow is less laminar on left than on right → left venous pressure > right venous pressure → varicocele more common on the left.



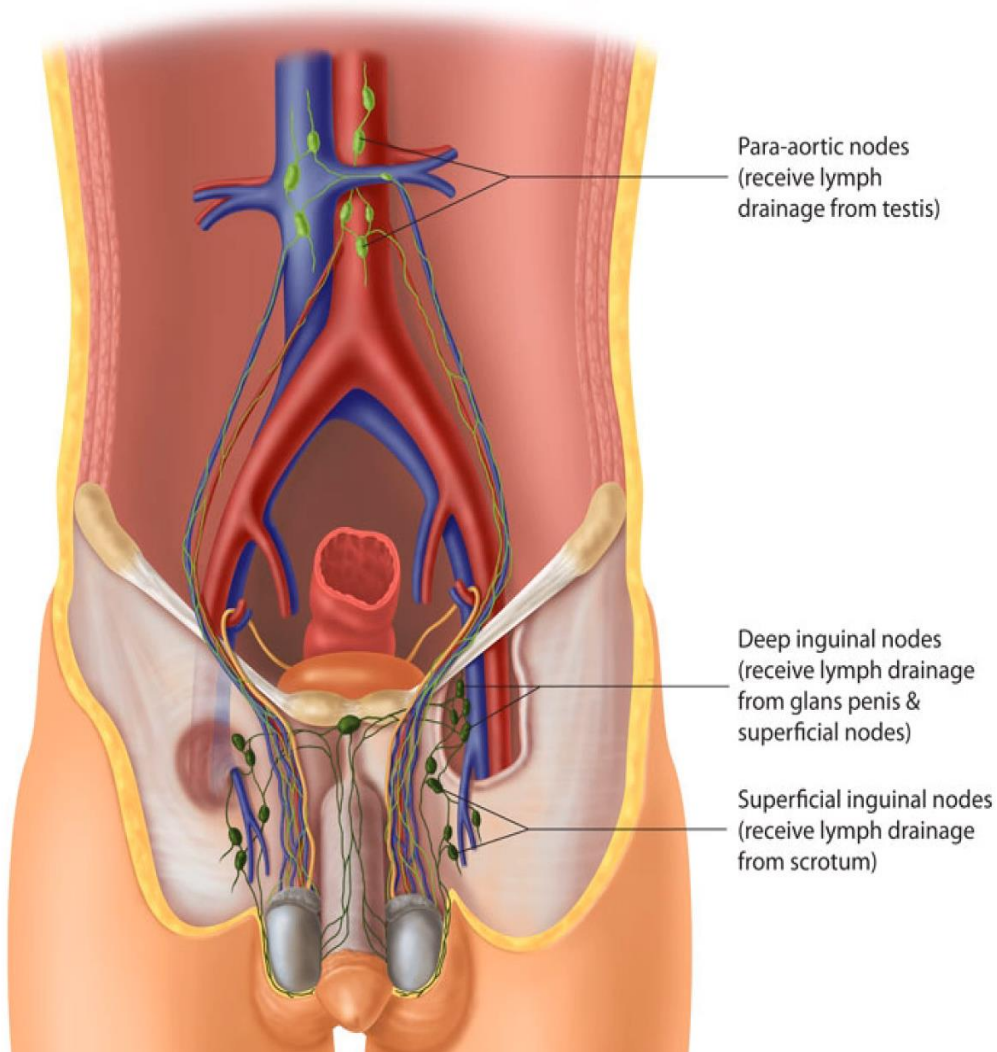
### B. Lymphatic drainage:

- Ovaries/testes → para-aortic lymph nodes.
- Body of uterus/cervix/superior bladder → external iliac nodes.
- Prostate/cervix/corpus cavernosum/proximal vagina → internal iliac nodes.
- Distal vagina/vulva/scrotum/distal anus → superficial inguinal nodes.
- Due to its intra-abdominal origin, lymphatic drainage of the testis is to the para-aortic lymph nodes, contrast, lymph drainage from the scrotum goes into the superficial inguinal lymph nodes.
- Glans penis → deep inguinal nodes.

## ❖ N.B:

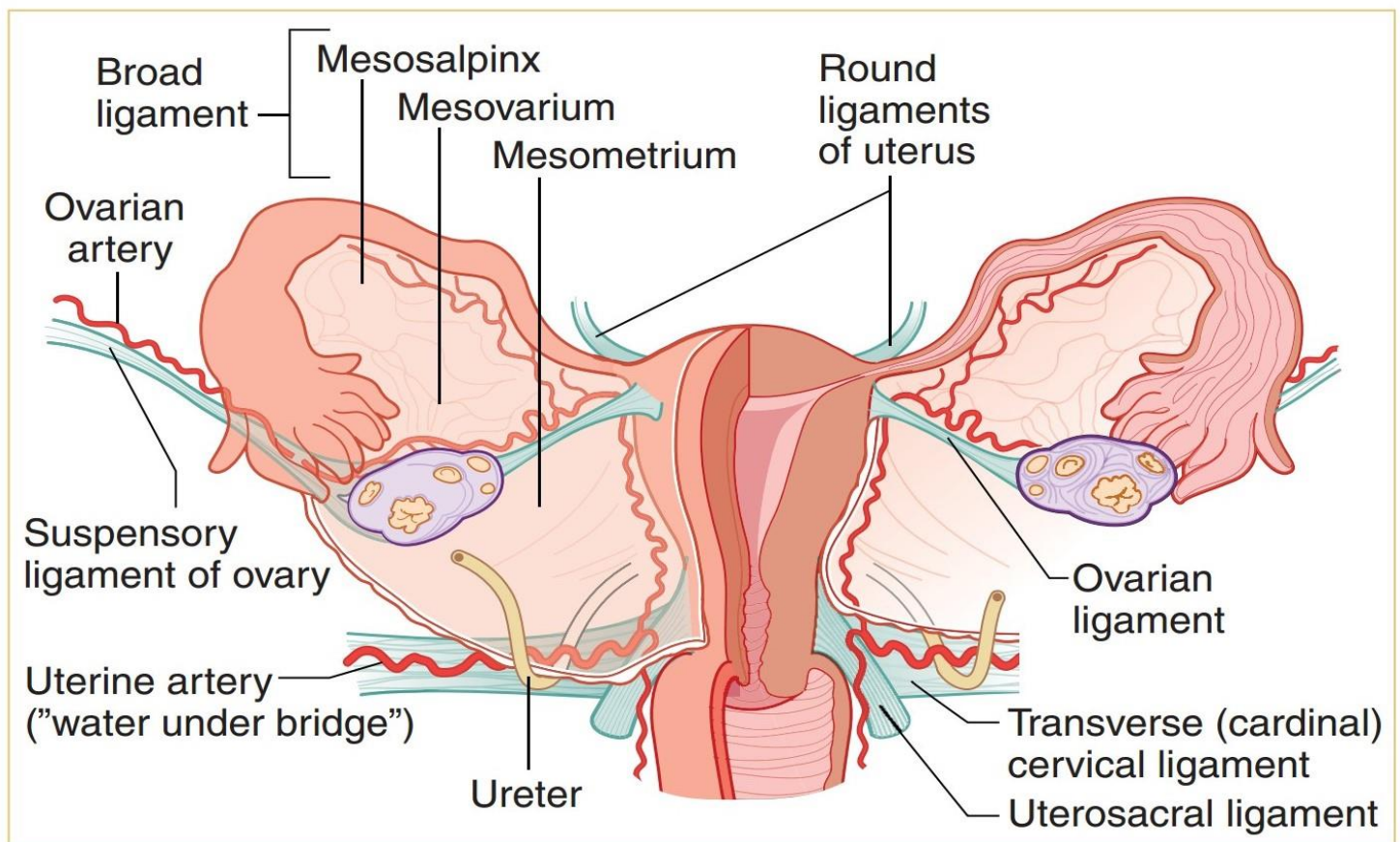
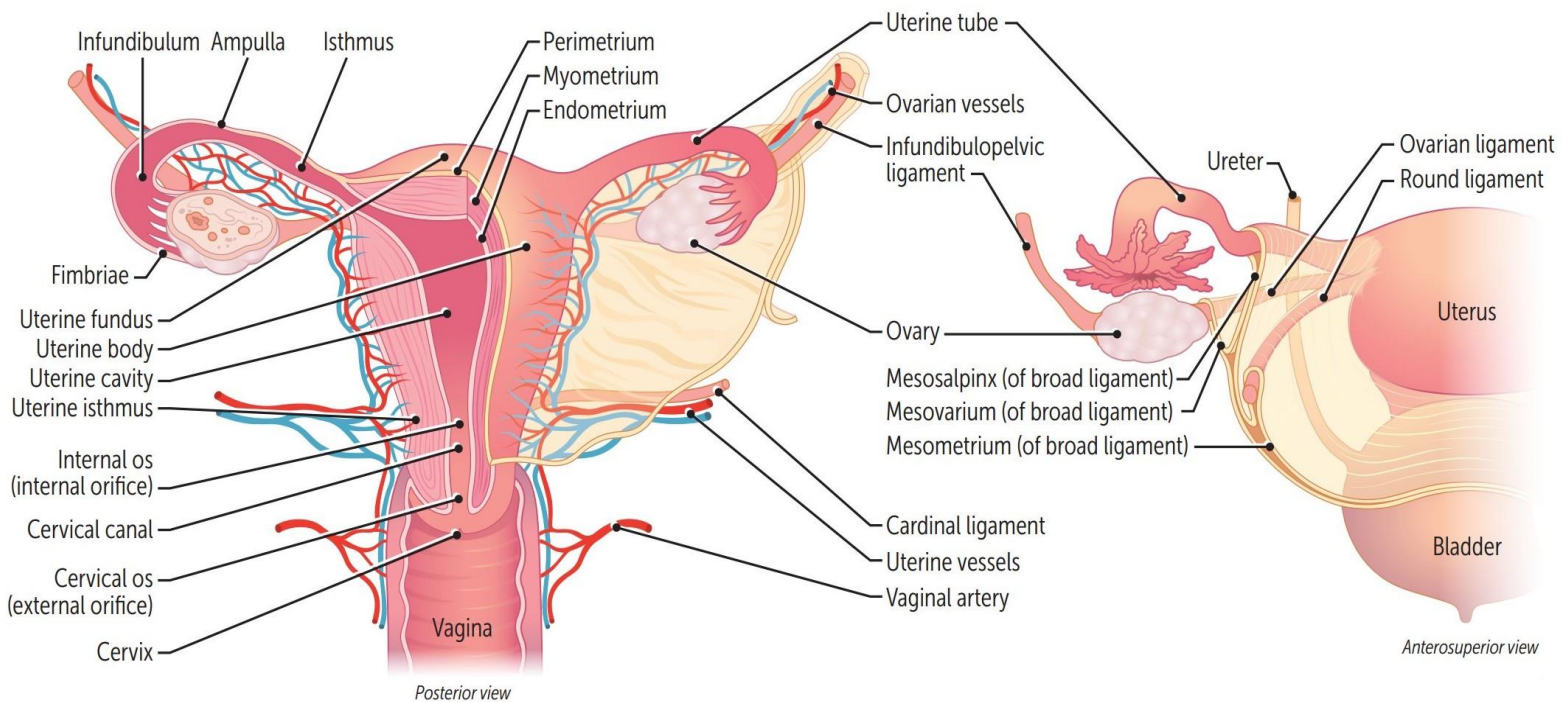
- Lymphatic drainage of the scrotum occurs via the **superficial inguinal lymph nodes**.
- These lymph nodes **drain nearly all cutaneous lymph from the umbilicus to the feet, including the external genitalia and anus (up to the dentate line)**.
- The exceptions are the **testis, glans penis, and the cutaneous portion of the posterior calf**.
- Lymph from the testes drains directly into the para-aortic (retroperitoneal) lymph nodes.
- During fetal development, the testes originate within the retroperitoneum and establish their arterial supply from the abdominal aorta. The testes subsequently descend through the inguinal canals into the scrotum, taking with them their arterial, venous, and lymphatic supplies. Thus, lymph from the testes drains through lymph channels directly back to the para-aortic (retroperitoneal) lymph nodes.
- Lymph from **the glans penis and the cutaneous portion of the posterior calf** drains into the **deep inguinal lymph nodes**.
- The superficial inguinal lymph nodes also drain into the deep inguinal lymph nodes.

Lymph vessels & nodes of male genitalia





## Female reproductive anatomy



- Female reproductive system is held in place by several peritoneal ligaments, of which the following are the most important:
  1. **Broad ligament:**
    - Fold of peritoneum that comprises the **mesosalpinx** (a subdivision of broad ligament that suspends **Fallopian tubes**), **mesometrium** (a subdivision of broad ligament that suspends **uterus**), and **mesovarium** (a subdivision of broad ligament that suspends **ovaries**).
    - Connects: Uterus, fallopian tubes, and ovaries to pelvic side wall.
    - Structures contained: Ovaries, fallopian tubes, round ligaments of uterus.
  2. **Ovarian ligament:**
    - Connects: Medial pole of ovary to lateral uterus.
    - Derivative of gubernaculum.
  3. **Infundibulopelvic ligament (suspensory ligament of the ovary):**
    - Connects: Ovaries to lateral pelvic wall.
    - Structures contained:
      - The nerves, arteries, veins, and lymphatics supplying the ovary are all delivered by the **suspensory ligament of the ovary**.
      - The ovarian blood supply is provided by the ovarian arteries, which arise from the abdominal aorta bilaterally.
      - **Ligate vessels during oophorectomy to avoid bleeding.**
      - **Ureter courses retroperitoneally, close to gonadal vessels → at risk of injury during ligation of ovarian vessels.**
      - **Rotation of the ovary around the IP ligament results in ovarian torsion.**
  4. **Round ligament of the uterus:**
    - Connects: Uterine fundus to labia majora.
    - It contains the artery of Sampson which rarely is a source of a major bleeding.
    - Derivative of gubernaculum.

5. **Cardinal ligament:**

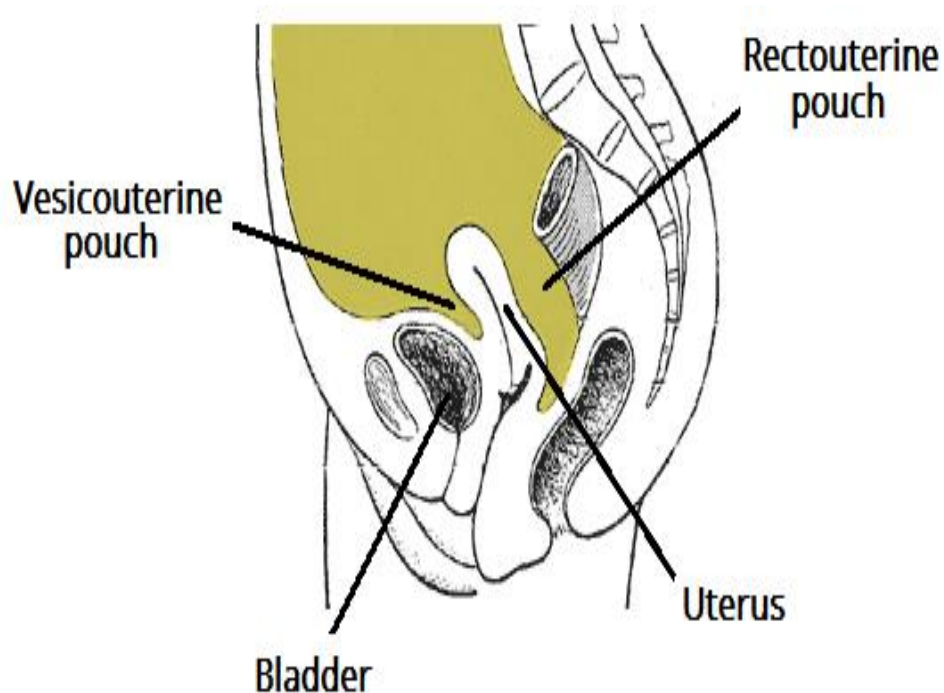
- Also known as transverse cervical ligaments.
- Connects: Cervix to side wall of pelvis.
- Structures contained: Uterine vessels.
- Ureter at risk of injury during ligation of uterine vessels in hysterectomy.

**Pouches of pelvis**

A. **Vesicouterine pouch:** a peritoneal sac between bladder and uterus.

B. **Rectouterine pouch (of Douglas):**

- A peritoneal sac between uterus and rectum.
- Lies behind posterior fornix of vagina.
- Lowest portion of peritoneal cavity.
- As it is the furthest point of the abdominopelvic cavity in women, it is a site where infection and fluids typically collect.
- Culdocentesis is aspiration of fluid from rectouterine pouch by a needle puncture of posterior fornix of vagina.



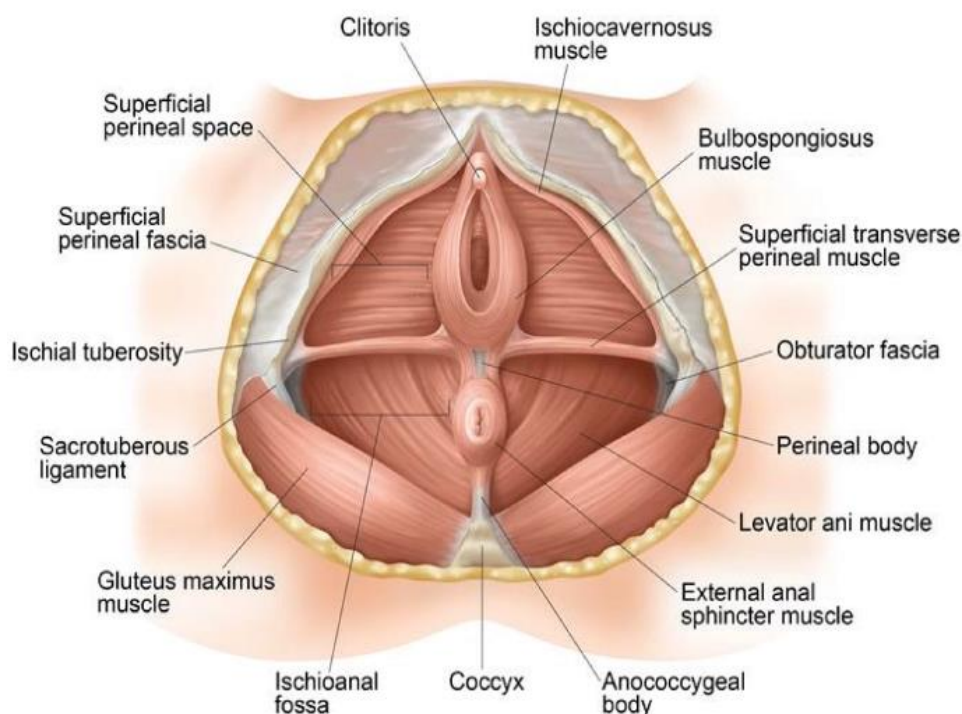
## Female reproductive epithelial histology

Tissue	Histology
Vulva	Stratified squamous epithelium
Vagina	Stratified squamous epithelium, nonkeratinized
Ectocervix	Stratified squamous epithelium, nonkeratinized
Transformation zone	Squamocolumnar junction ( <b>most common area for cervical cancer</b> )
Endocervix	Simple columnar epithelium
Uterus	Simple columnar epithelium with long tubular glands in proliferative phase; coiled glands in secretory phase
Fallopian tube	Simple columnar epithelium, ciliated
Ovary, outer surface	Simple cuboidal epithelium ( <b>germinal epithelium covering surface of ovary</b> )

## ❖ N.B:

- The perineal body is **essential to the integrity of the pelvic floor**.
  - This tendinous center point of the perineum separates the urogenital and anal triangles.
  - Episiotomies are used to enlarge the vaginal outlet to **facilitate delivery and reduce the risk of severe perineal laceration**.
  - A midline episiotomy is a vertical incision from the posterior vaginal opening to the perineal body**. It transects the vaginal lining and the submucosal tissue but not the external anal sphincter or the rectal mucosa.

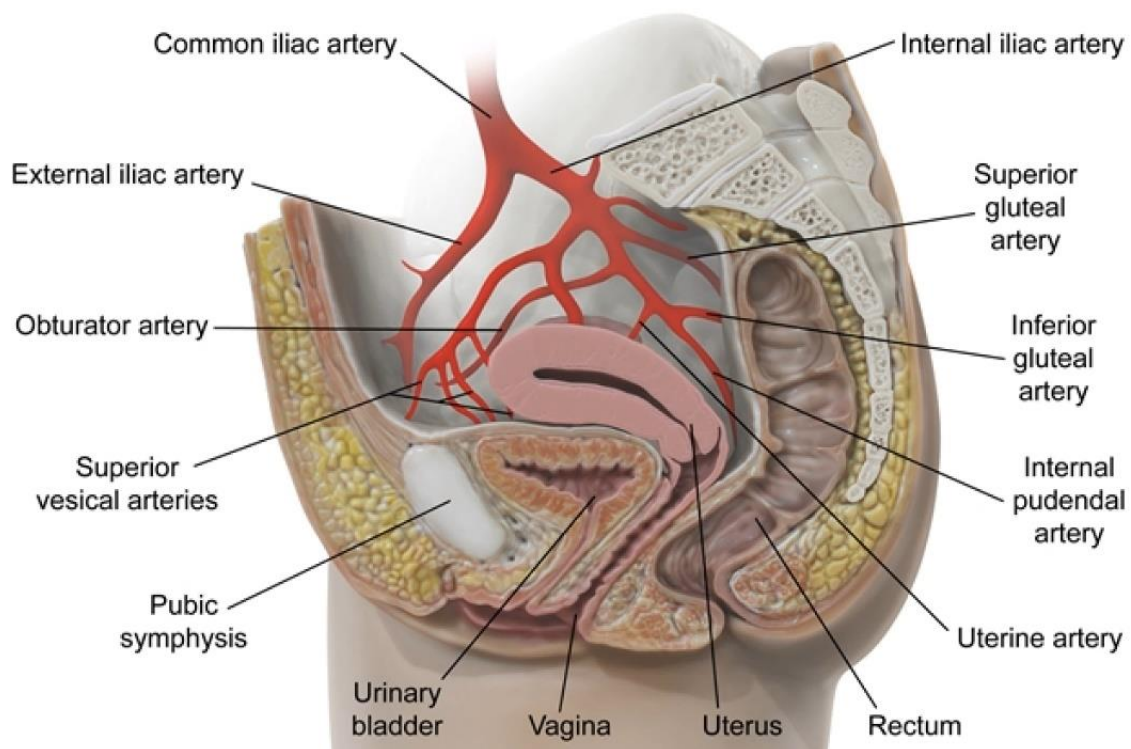
## Pelvic floor muscles





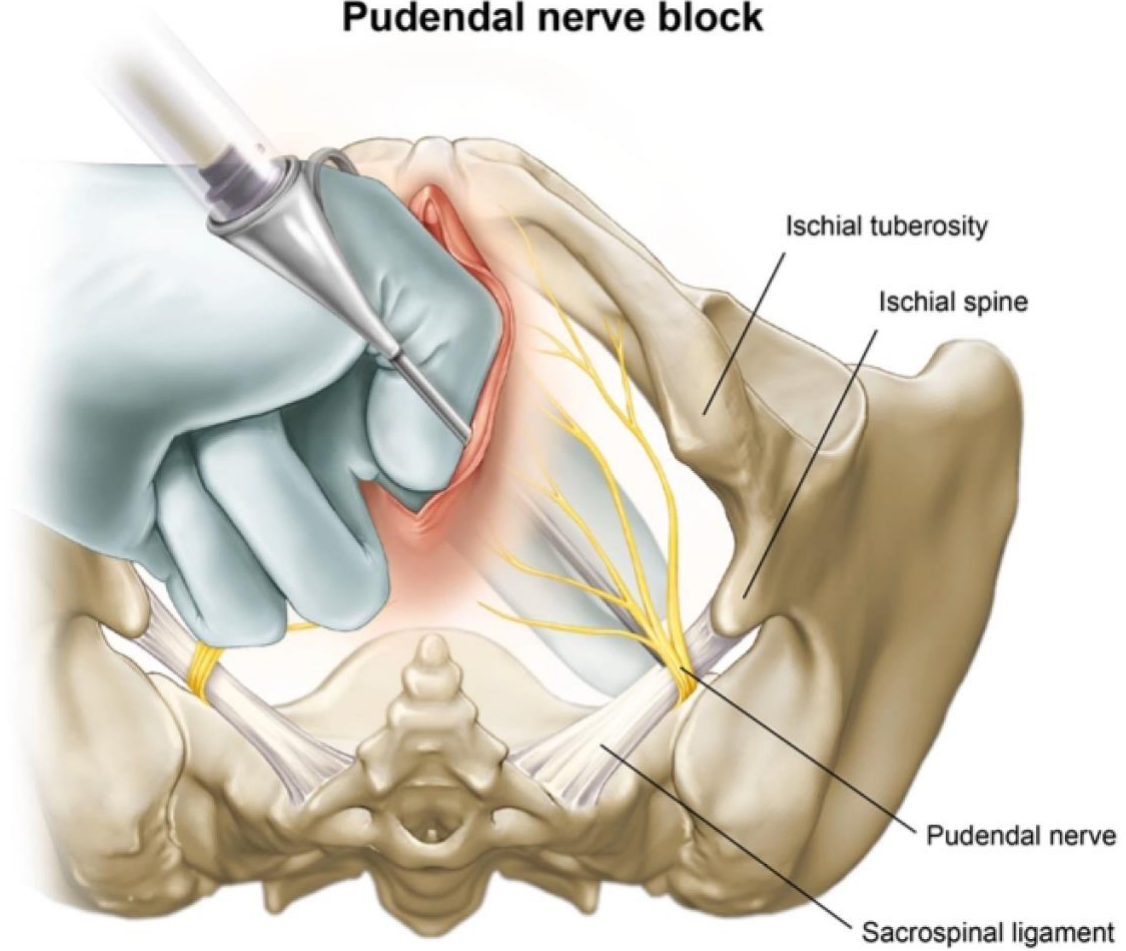
2. Postpartum hemorrhage is an **obstetrical emergency** and a leading cause of maternal mortality.
  - Postpartum hemorrhage is frequently caused by **failure of the uterus to contract and compress the placental site blood vessels**.
  - Risk factors include prolonged labor and twin gestation. These conditions lead to **uterine atony (loss of uterine tone)**, characterized by a boggy uterus that cannot contract effectively after placental delivery.
  - Surgery is indicated when medical management (**uterine massage, uterotonic medications**) of postpartum hemorrhage fails to control bleeding.
  - The pelvic organs are mainly supplied by **the internal iliac arteries** (also known as the hypogastric arteries).
  - The uterine arteries, the major blood supply to the uterus, are branches of the internal iliac arteries. **Bilateral ligation (suturing) of the internal iliac arteries should stop uterine blood flow and hemorrhage, thereby preventing the need for hysterectomy.** The uterus has collateral blood flow from the ovarian arteries, which is sufficient to maintain uterine function after internal iliac ligation.

### Branches of the internal iliac artery in the female

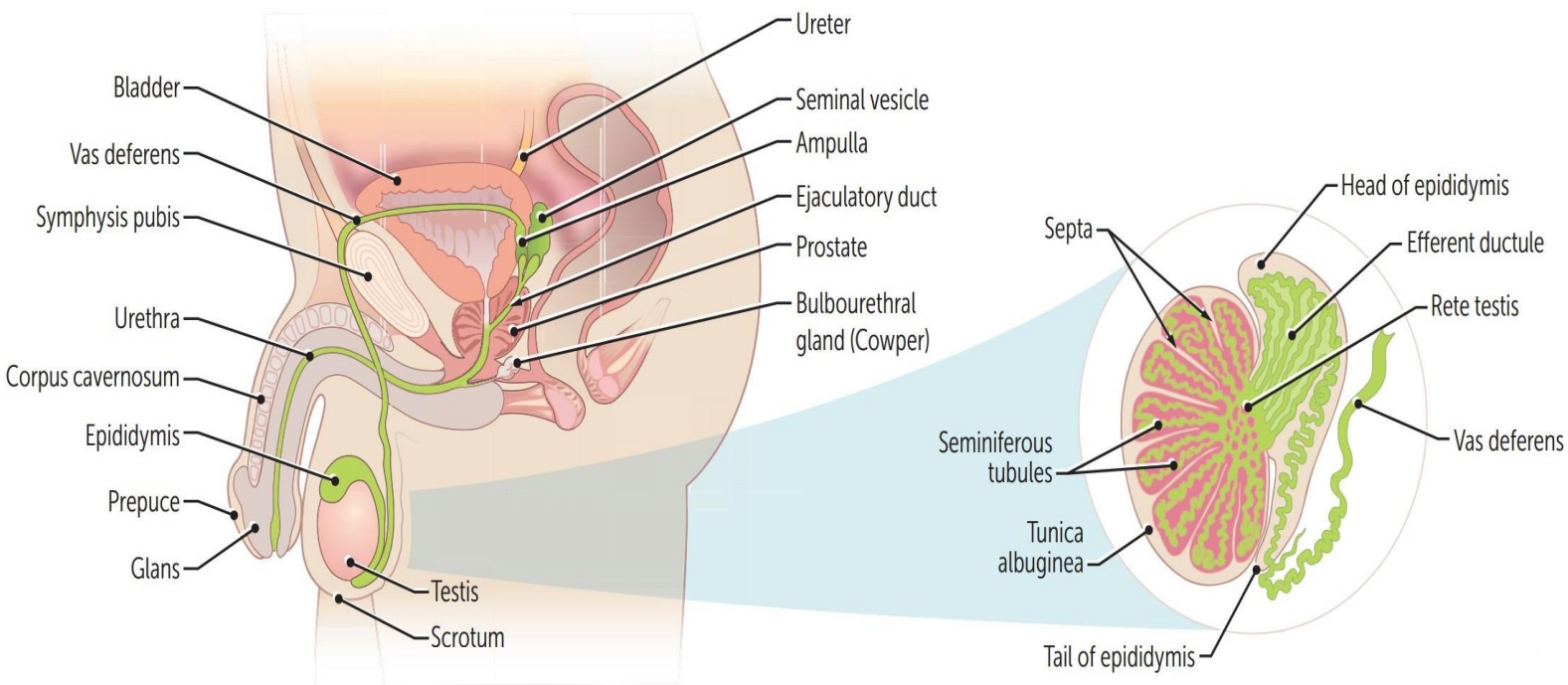


3. A pudendal nerve block is one method of **providing anesthesia during childbirth**.
  - **The pudendal nerve is derived from the S2 - S4 nerve roots and provides sensory innervation to the perineum and genitals (of both sexes) as well as motor innervation to the sphincter urethrae (external urethral sphincter) and the external anal sphincter.**
  - When administering a pudendal nerve block, the physician generally palpates intravaginally for the **ischial spines** and attempts to administer the anesthetic agent in that location.

## Pudendal nerve block



## Male reproductive anatomy

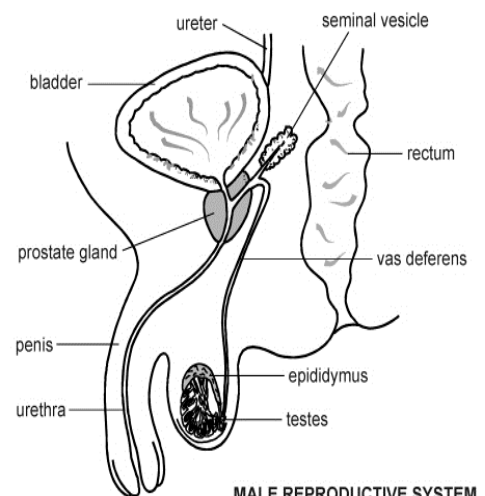


### ▪ Pathway of sperm during ejaculation (SEVEN UP):

- **S**eminiferous tubules.
- **E**pididymis.
- **V**as deferens.
- **E**jaculatory ducts.
- **(Nothing)**.
- **U**rethra.
- **P**enis.

### Retrograde ejaculation

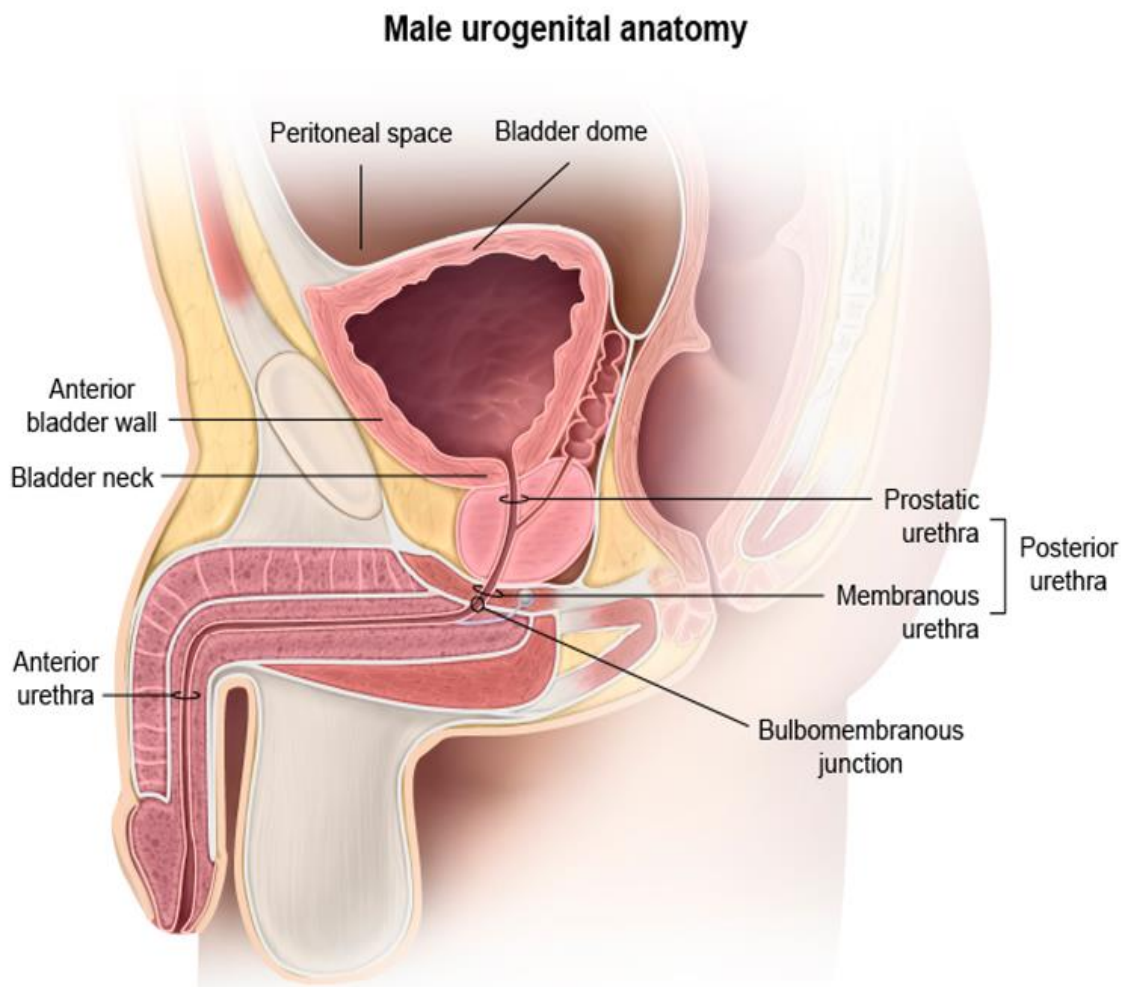
- The urethral sphincters are used to **control the exit of urine and semen through the urethra**.
- In males and females, both internal and external urethral sphincters function to inhibit the release of urine.
- **In males, the internal sphincter muscle of urethra functions to prevent reflux of seminal fluids into the male bladder during ejaculation.**
- Normally, the sphincter of the bladder contracts before ejaculation **forcing the semen to exit via the urethra, the path of least resistance**.
- **When the bladder sphincter does not function properly, retrograde ejaculation may occur.**





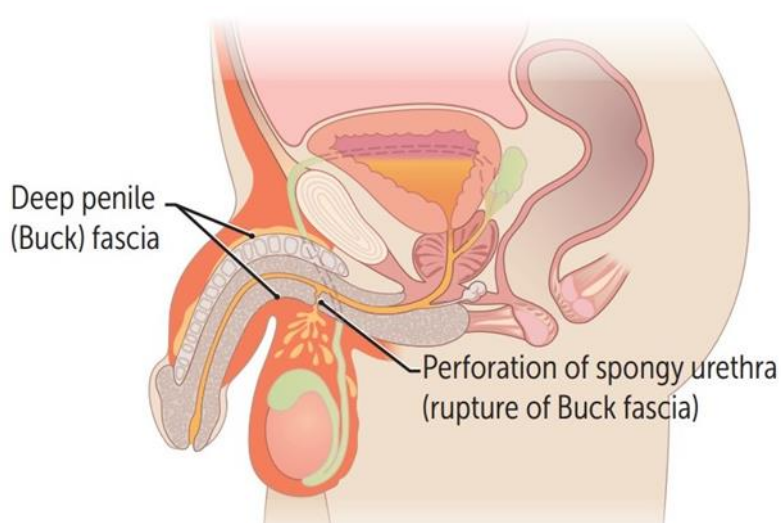
## Urethral injury

- Suspect if blood seen at urethral meatus.
- Urethral injuries **most commonly occur in men** because of their **longer** urethral length and are divided into anterior and posterior urethral injuries.
- The posterior urethra is located above the bulb of the penis, and the anterior urethra lies within the bulb and the remainder of the corpus spongiosum.
- The posterior urethra is further divided into the **prostatic and membranous segments**; the anterior urethra is divided into **bulbous and penile segments**.
- **If urethral injury is suspected, placement of a Foley catheter is contraindicated and should not be attempted as it can worsen the injury; a retrograde urethrogram should be performed first to assess urethral integrity.**

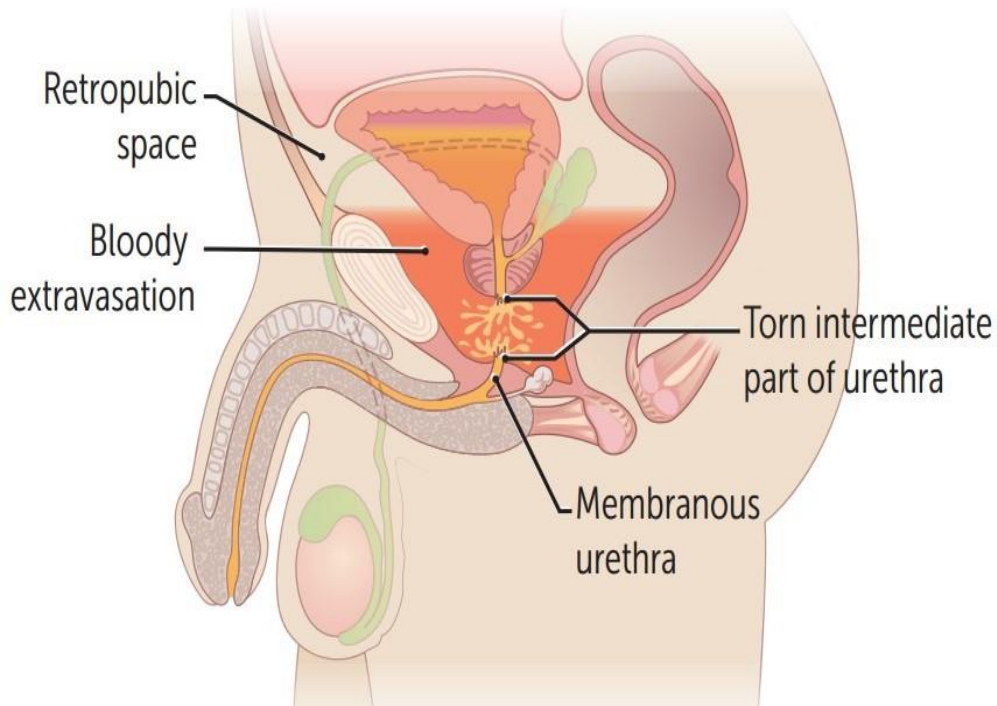


A. **Anterior urethral injury:**

- Part of urethra: Bulbar (spongy) urethra.
- Mechanism of injury: **Perineal straddle injury.**
- Location of urine leak/blood accumulation:
  - o Blood accumulates in scrotum.
  - o If Buck fascia is torn, urine escapes into perineal space.
- Presentation: Blood at urethral meatus and scrotal hematoma.

B. **Posterior urethral injury:**

- Part of urethra:
  - o Membranous urethra.
  - o In contrast to the prostatic and bulbous segments, **the membranous segment is relatively unsupported by the adjacent tissues and is the weakest point of the posterior urethra.**
- Mechanism of injury: **Pelvic fracture.**
- Location of urine leak/blood accumulation: Urine leaks into **retropubic space.**
- Presentation:
  - o **Inability to void** with a full bladder sensation, a **high-riding boggy prostate** (caused by hematoma formation below the gland), and **blood at the urethral meatus** are suggestive of urethral injury, particularly in the presence of a pelvic fracture.



### Penis Anatomy

- The penis is made of several parts:

A. Glans (head) of the penis.

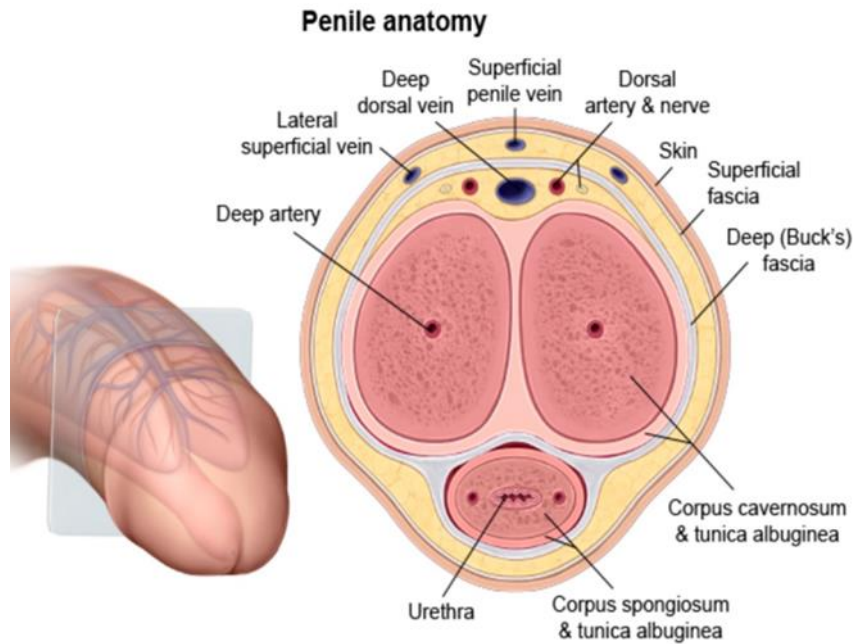
B. Corpus cavernosum:

- Two columns of tissue running along the sides of the penis.
- Blood fills this tissue to cause an erection.

C. Corpus spongiosum:

- A column of sponge-like tissue running along the front of the penis and ending at the glans penis.
- The urethra runs through the corpus spongiosum, conducting urine out of the body.

- An erection results from changes in blood flow in the penis. When a man becomes sexually aroused, nerves cause penis blood vessels to expand → **More blood flows in and less flows out of the penis, hardening the tissue in the corpus cavernosum.**



### Autonomic innervation of the male sexual response

#### A. **Erection:**

- **P**arasympathetic nervous system (pelvic splanchnic nerves, S2-S4).
- NO  $\rightarrow$   $\uparrow$  cGMP  $\rightarrow$  smooth muscle relaxation  $\rightarrow$  vasodilation  $\rightarrow$  proerectile.
- Norepinephrine  $\rightarrow$   $\uparrow$  [Ca]  $\rightarrow$  smooth muscle contraction  $\rightarrow$  vasoconstriction  $\rightarrow$  antierectile.

#### ▪ **Emission:**

- Phase when sperm moves from testes up to prostatic urethra.
- **S**ympathetic nervous system (hypogastric nerve, T11-L2).

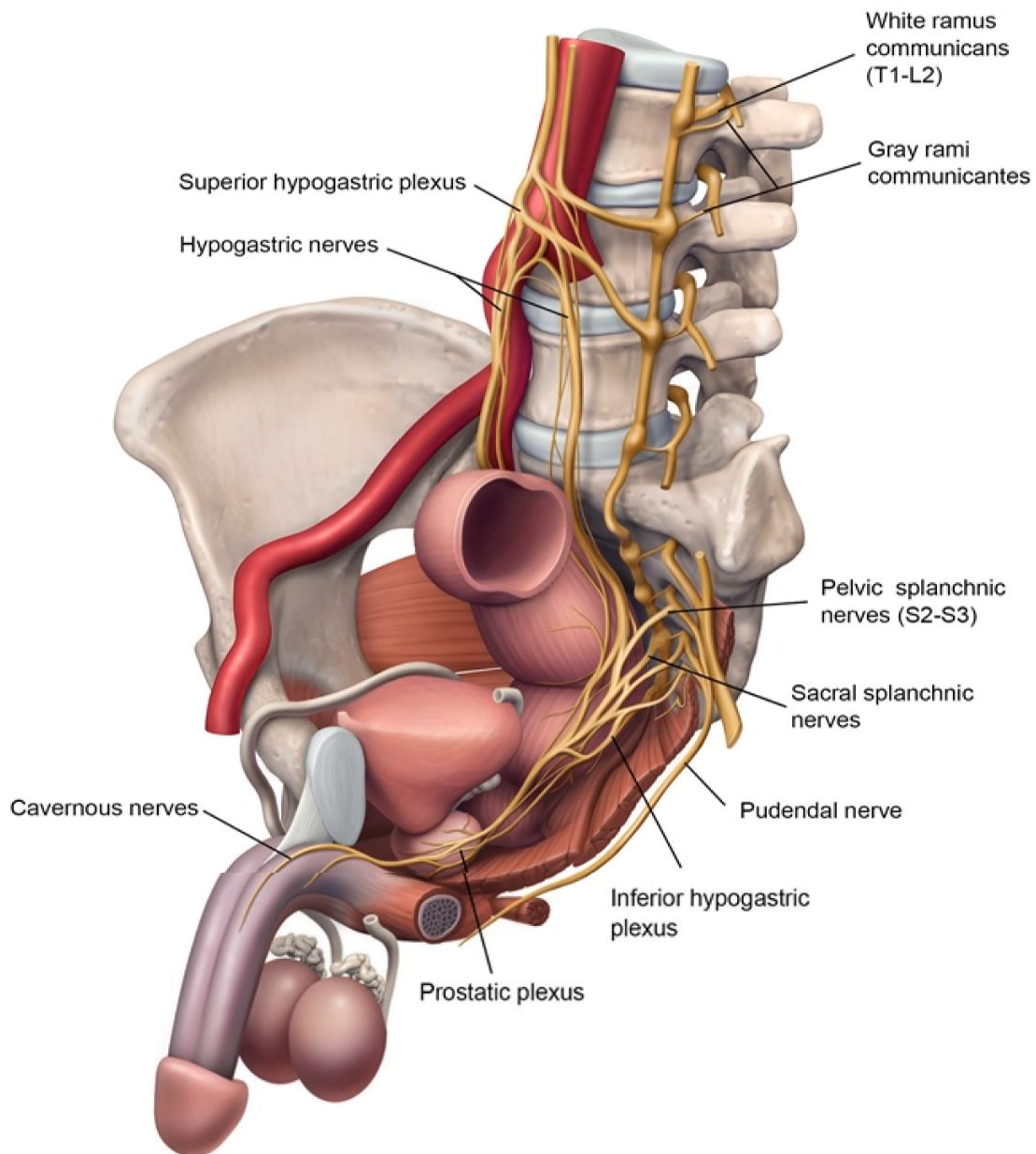
#### ▪ **Ejaculation:**

- Phase when sperm moves from prostatic urethra to the outside.
- Visceral and **S**omatic nerves (pudendal nerve).
- **P**oint, **S**queeze, and **S**hoot.
- S2, 3, 4 keep the penis off the **f**loor.
- PDE-5 inhibitors (sildenafil)  $\rightarrow$   $\downarrow$  cGMP breakdown.

## ❖ N.B:

- The lesser and greater cavernous nerves arise from the prostatic plexus and pass beneath the pubic arch to **innervate the corpora cavernosa of the penis and urethra**.
- The cavernous nerves **carry post-ganglionic parasympathetic fibers that facilitate penile erection**.
- The prostatic plexus lies within the fascia of the prostate and originates from the inferior hypogastric plexus (which itself is a continuation of the hypogastric nerve with additional input from the pelvic and sacral splanchnic nerves).
- **Prostatectomy or injury to the prostatic plexus can cause erectile dysfunction; as a result, surgeons attempt to preserve the integrity of the prostatic fascial shell during surgery.**

### Pelvic autonomic nerves





## **CHAPTER 3**

# **Physiology**



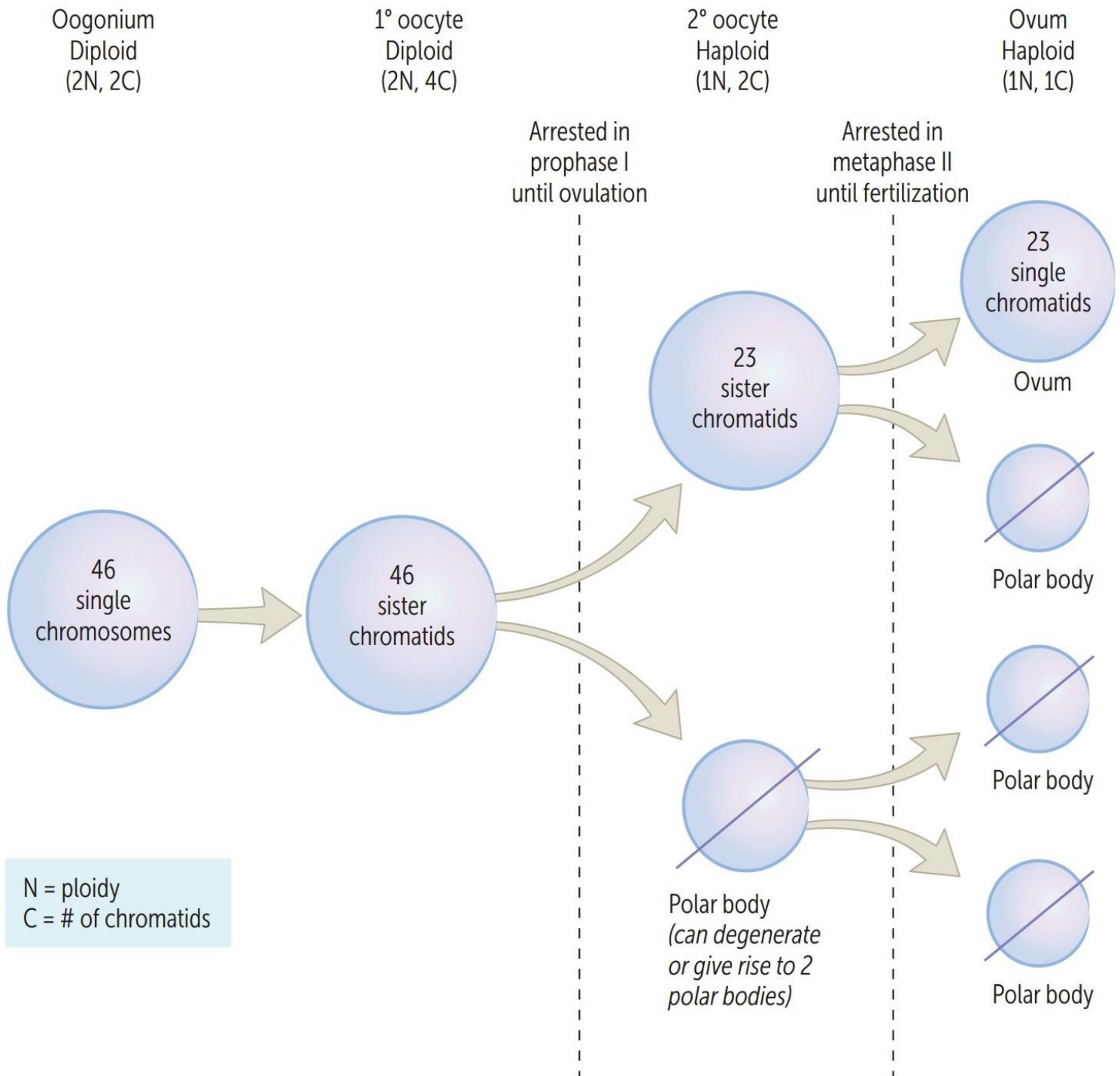
## The Female Reproductive System

### Oogenesis

- Gametogenesis is a specialized process of cell division that produces the male gamete (spermatogenesis) and female gamete (oogenesis).
- Meiosis occurs within the testes and ovary.
- Meiosis consists of 2 cell divisions, meiosis I and meiosis II.
- In the female, gametogenesis begins early in embryonic development (at approximately four weeks gestation) when the primordial germ cells migrate from the yolk sac region to the developing gonadal region.
- The primordial germ cells then differentiate into oogonia, before beginning meiosis I.
- Starting at about eight weeks of gestation, oogonia begin meiosis I where they arrest in prophase of meiosis I and remain there until puberty. They are now referred to as primary oocytes.
- A woman's full complement of oocytes is developed by five months gestational age.
- At puberty, ovulatory cycles begin, and the female becomes capable of reproduction.
- FSH stimulation during the ovarian cycle causes some oocytes to complete meiosis I, forming secondary oocytes and polar bodies.
- The secondary oocyte begins meiosis II (the polar body degenerates), but halts in metaphase of meiosis II.
- Prior to fertilization, secondary oocytes are arrested in metaphase of meiosis II.
- At day 14 of the menstrual cycle, a secondary oocyte is released from the ovarian follicle in response to high estrogen concentrations and a paradoxical LH surge.
- The secondary oocyte remains frozen in metaphase II until fertilization occurs, at which point it divides into a mature oocyte and second polar body.
- If fertilization does not occur within 1 day, the 2° oocyte degenerates.

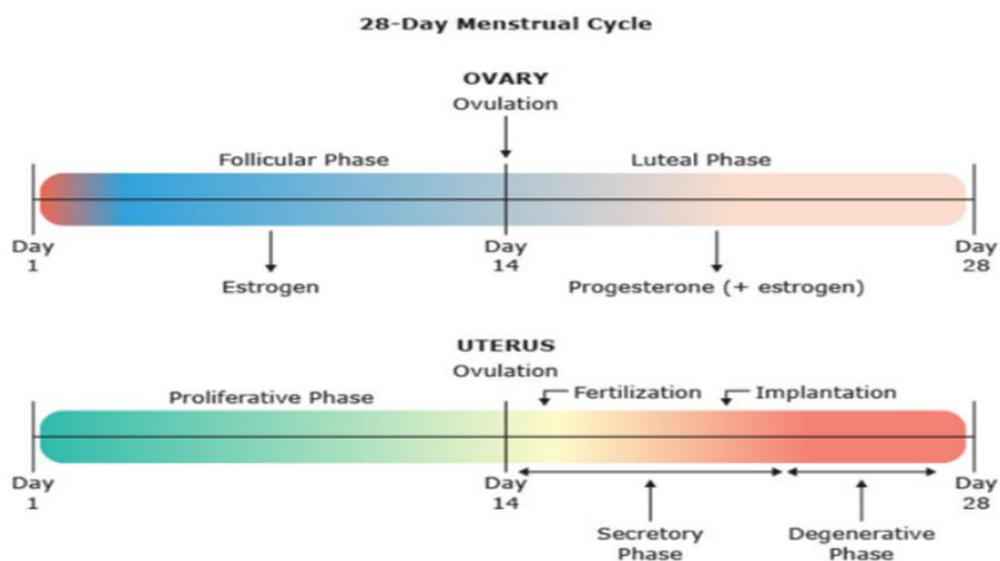
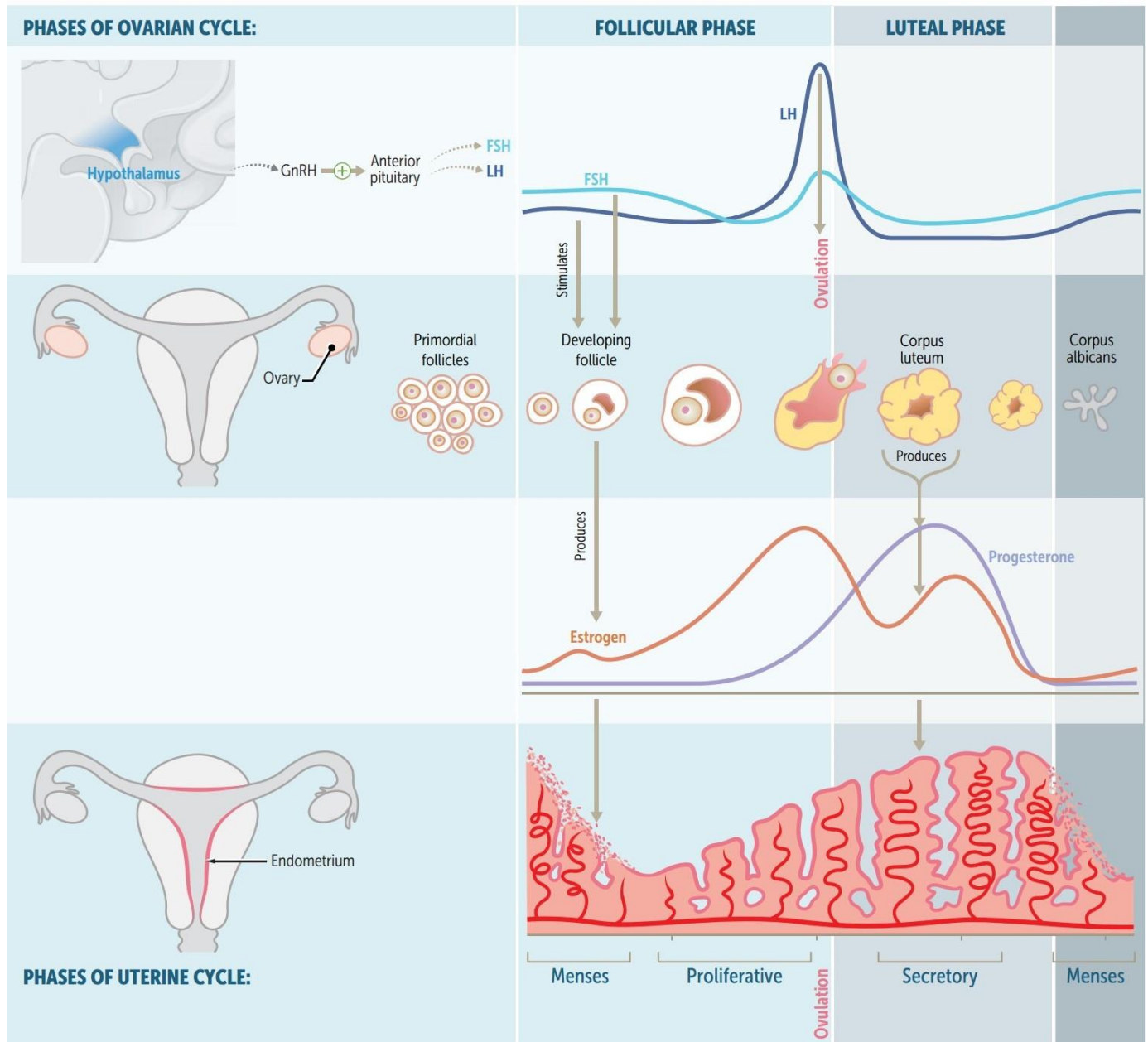
❖ In a nutshell:

- 1° oocytes begin meiosis I during fetal life and complete meiosis I just prior to ovulation.
- Meiosis I is arrested in prOphase I for years until Ovulation (1° oocytes).
- Meiosis II is arrested in metaphase II until fertilization (2° oocytes). "An egg met a sperm."



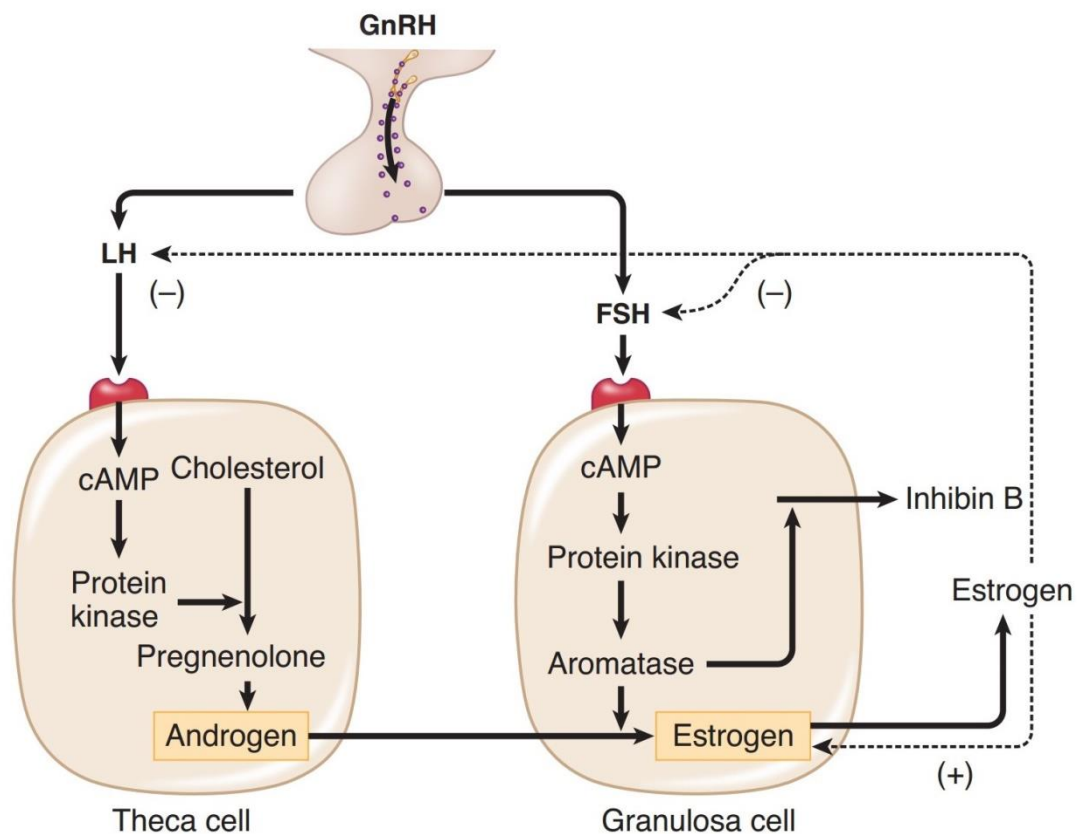
### The menstrual cycle

- The ovarian menstrual cycle is **approximately 28 days**.
  - It consists of **two phases and one event**.
  - Each of the two phases is about **14 days**.
  - Variable lengths in the menstrual cycle are usually **due to variations in the follicular phase**.
  - **Once ovulation occurs, menstruation occurs almost exactly 14 days later**. Ovulation day + 14 days = menstruation.
  - **The length of the menstrual cycle in days minus 14 gives a good estimate of the day of ovulation**.
- A. Follicular Phase (Days 1-14):
- This represents **the growth of the dominant follicle within the ovary**, driven mainly by **FSH**.
  - It is probably the **largest** follicle and the one with **the greatest number of FSH receptors**.
  - The main hormonal secretion is **estrogen** by the **granulosa cells**.
  - One function of the estrogen is to **stimulate the replacement of the cells of the functional layer of the endometrium lost in the last menstruation**.
- B. Ovulation: Preceded by the **LH surge** near the end of the follicular phase, which **induces ovulation on about Day 14**.
- C. Luteal Phase (Days 14-28):
- Formation and functioning of **the corpus luteum**, driven by **LH**.
  - The main function of the corpus luteum is to **secrete progesterone plus some estrogen**. The **estrogen is needed for progesterone to function**.
  - The progesterone secreted in the first week of this phase **creates the thick, secretory endometrium required for implantation**.
  - **Regression of the corpus luteum occurs by day 23 if there is no pregnancy, causing decreased levels of progesterone** → Constriction of the spiral arteries occurs 1 day before menstruation, causing endometrial ischemia and release of **prostaglandins**, followed by leukocyte infiltration. The resulting necrosis leads to **painful cramps and menstruation**.

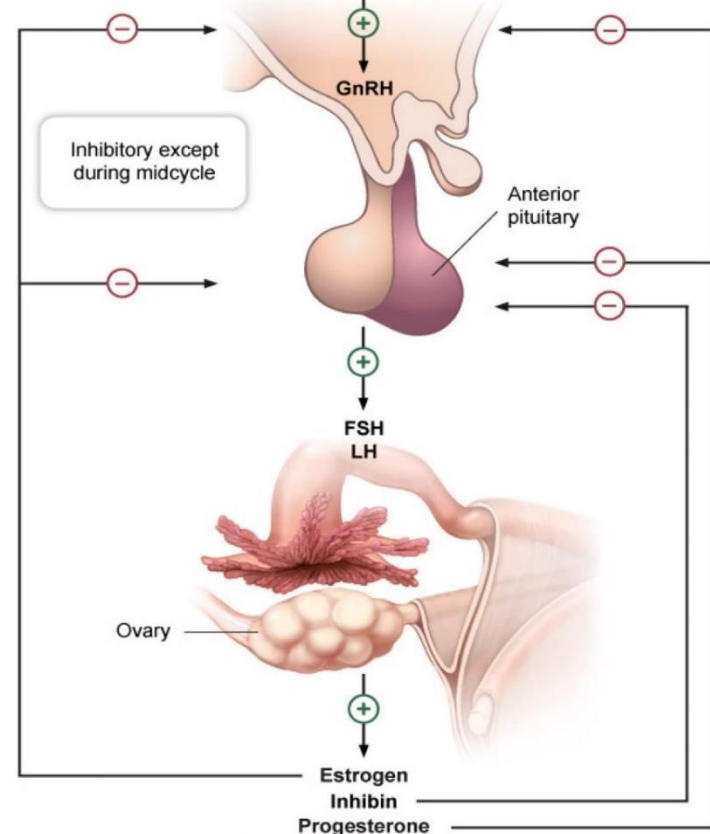
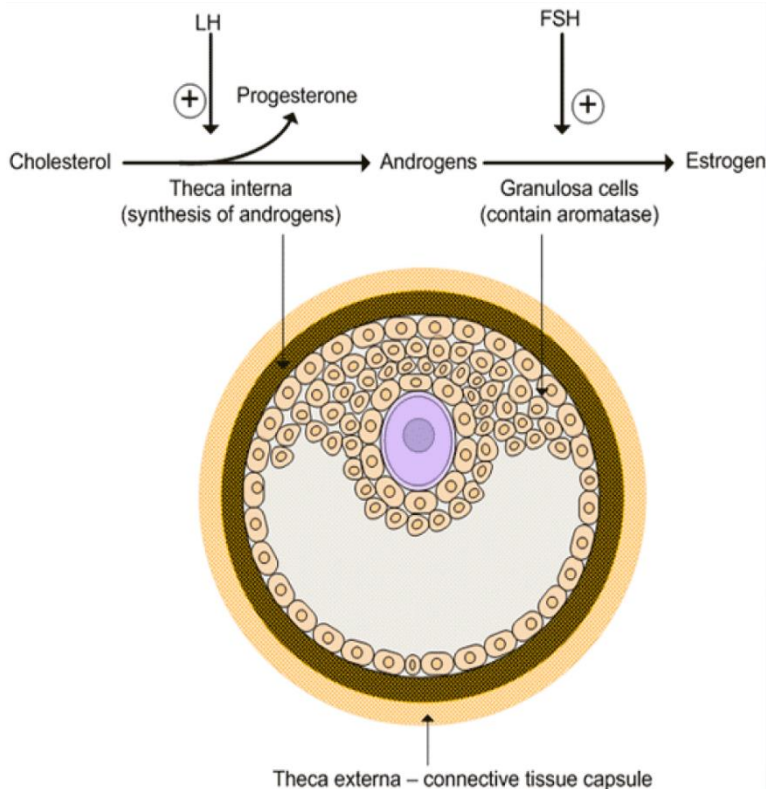


## Follicular phase

- A dominant follicle emerges from the growing pool of follicles in the first week of the follicular phase.
- It is probably **the largest follicle and the one with the greatest number of FSH receptors**.
- The dominant follicle becomes a **steroidogenic gland**.
- Both the thecal and granulosa cells are required and participate in steroid hormone synthesis.



- Theca Cells:
  - They have LH receptors and stimulation by LH; they produce large amounts of androgen.
  - The main androgen synthesized is **androstenedione**, but some testosterone is also synthesized.
  - Some androgen diffuses to the circulation, but **most is transferred to the granulosa cells**.



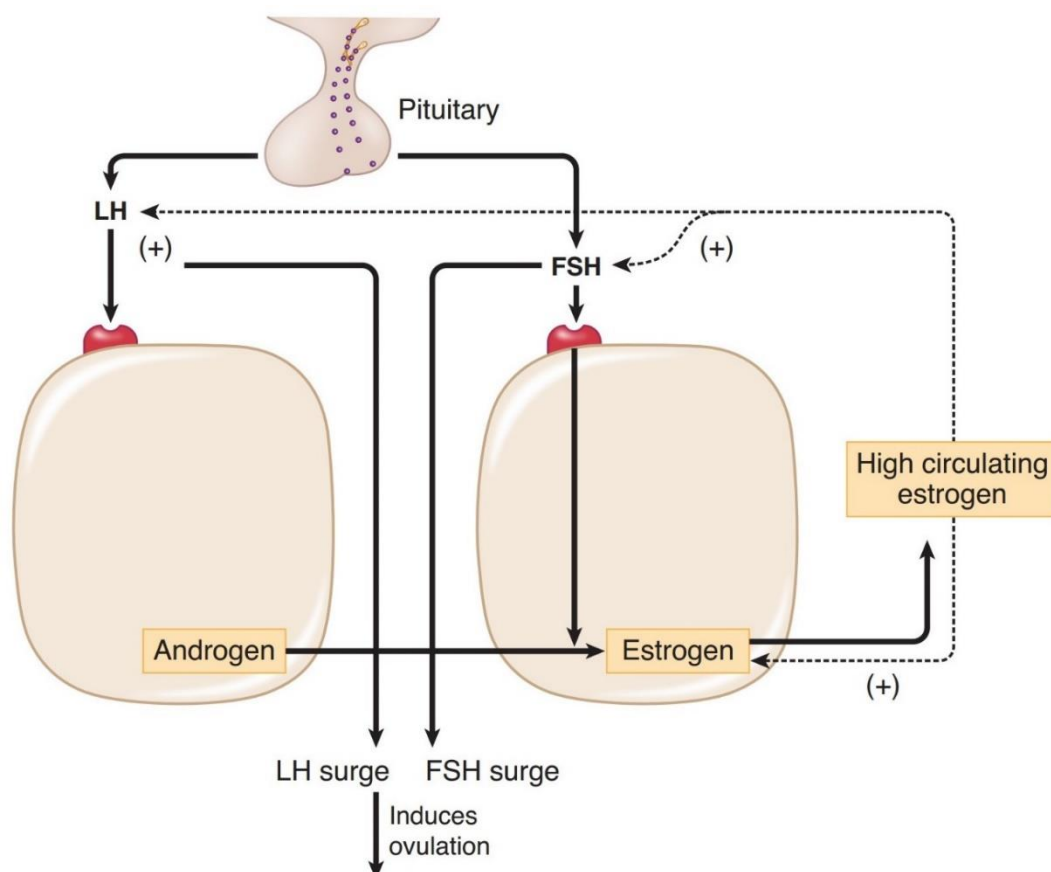
#### Granulosa Cells:

- Mural granulosa cells are very sensitive to FSH.
  - They express aromatase and convert the androgen to estrogen.
  - The rise in estrogen within the follicle further augments FSH activity.
  - In other words, estrogen acting locally enhances its own production.
  - FSH also stimulates the production and secretion of inhibin, Inhibin acting on the pituitary inhibits the secretion of FSH.
  - Circulating estrogen acting on the pituitary and the hypothalamus inhibit the secretion of both LH and FSH.
  - But because of the local effect of estrogen in the ovary, it continues to rise throughout this phase.
  - Estrogen slowly rises at the beginning and then increases more rapidly near the end of the phase.
- #### Estrogen:
- Estrogen has some important peripheral actions during this phase.
  - It induces the replacement of the cells of the functional endometrium lost in the last menstruation.
  - It also causes the cervical mucus to be thin and watery. This facilitates the transport of Sperm.



## Ovulation

- Preovulatory Follicle:
  - The steroidogenic pathways start to change just before ovulation.
  - They begin to move away from producing estrogen and toward a greater production of progesterone.
  - As a result, **plasma progesterone begins to rise just before ovulation.**
  - Progesterone also **increases basal body temperature and it has been used as a marker of ovulation.**
- Ovulation:
  - Estrogen, initially in the follicular phase, creates a negative feedback loop and inhibits the release of LH and FSH.
  - However, with the late dramatic rise in estrogen, it no longer inhibits the release of LH and FSH, it stimulates their release.
  - In other words, a **negative feedback has been converted to a positive feedback.**
  - This results in an **LH and an FSH surge, but it is the LH surge that causes ovulation.** The FSH surge may be involved in recruiting new follicles for the next cycle.

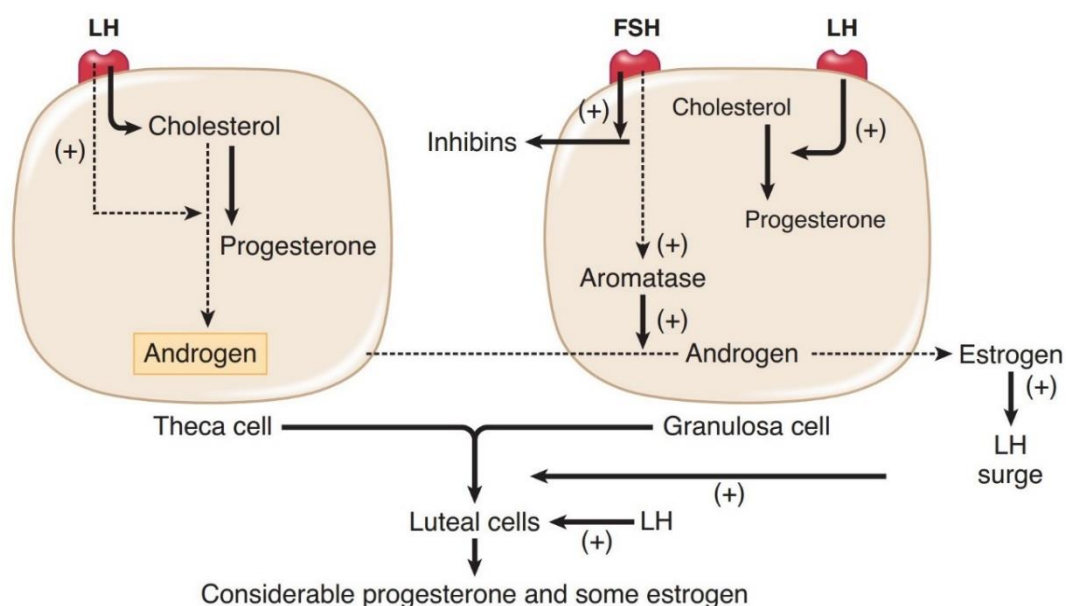




- Estrogen peaks just before the LH surge.
- Ovulation takes place about 36 hours after the LH surge.
- Because LH is a protein hormone, it is filtered by the kidney and appears in the urine.
- The appearance of an increase in urine LH can be used as an indicator of impending ovulation.
- **Mittelschmerz**: transient mid-cycle ovulatory pain ("Middle hurts"); classically associated with peritoneal irritation (follicular swelling/rupture, fallopian tube contraction). **Can mimic appendicitis.**

## Luteal phase

- The corpus luteum is made up of the remaining ovarian follicle after rupture.
- The luteal cells upregulate their LH receptors. This allows the basal secretion of LH to stimulate and maintain the corpus luteum.
- The luteal cells pathways produce considerable progesterone and some estrogen.
- The secreted progesterone inhibits the secretion of LH.
- Progesterone rises and peaks about the midpoint in the luteal phase.
- During the First week of the luteal phase, the progesterone along with estrogen **creates the secretory endometrium**. This **prepares the uterus for implantation**.
- Progesterone also **causes the cervical mucus to become thicker**. This makes it **more difficult for sperm as well as bacteria to penetrate the uterus**.

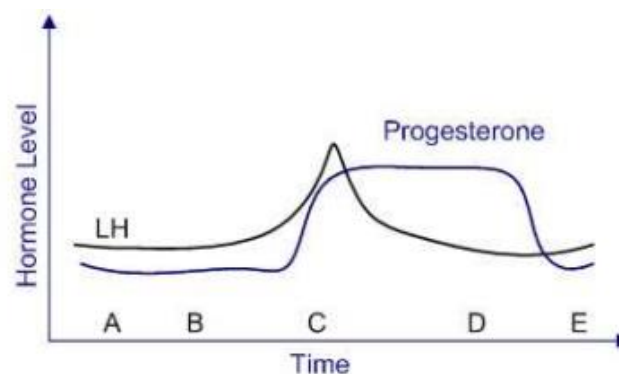


## Menses

- The corpus luteum starts to undergo a programmed cell death (luteolysis) approximately nine days after ovulation.
- The origin of luteolysis is not understood.
- For some reason, the luteal cells **stop responding to LH**.
- **Regression of the corpus luteum occurs by day 23 if there is no pregnancy, causing decreased levels of progesterone** → Constriction of the spiral arteries occurs 1 day before menstruation, causing endometrial ischemia → **endometrial apoptosis**, and release of **prostaglandins**, followed by leukocyte infiltration. The resulting necrosis leads to **painful cramps and menstruation**.

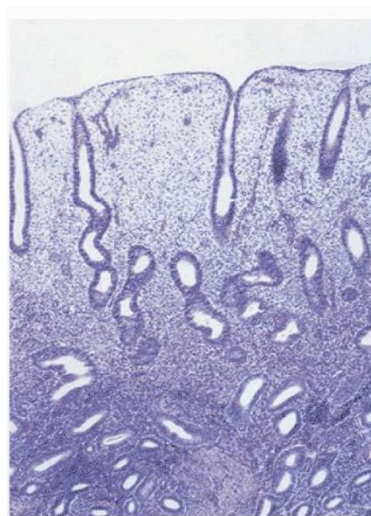
## Uterine changes during menstrual cycle

- The uterine endometrium is a highly specialized mucosa that experiences a multitude of changes during the menstrual cycle in preparation for zygote implantation.
- The upper layer of the endometrium (the stratum functionale) consists of **lamina propria studded with tubular glands, spiral arteries, and dilated capillaries**.
- Histologic examination of these components allows for endometrial dating.

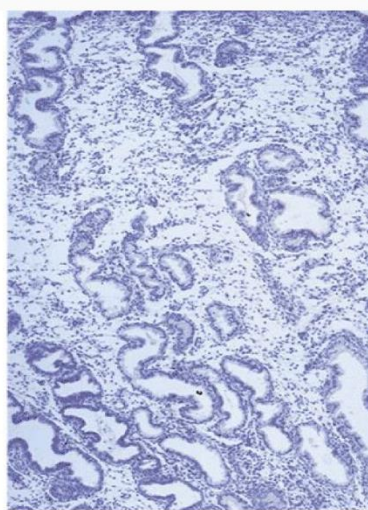


- Points (A and E) in the menstrual cycle:
  - Correspond to the beginning (point E) and end (point A) of menses.
  - An endometrial biopsy from this interval reveals an **eroded, hemorrhagic endometrial surface with disintegrating stroma and glands**.
  - The remaining intact uterine glands may contain blood.
  - Distal segments of the spiral arteries are **necrotic**.

- Point B in the menstrual cycle:
  - Represents the **midpoint of the proliferative phase of the menstrual cycle**.
  - The stratum functionale contains compact, **non-edematous stroma**.
  - The uterine glands have increased in length and girth **but still remain relatively straight**. No secretions are present in the glandular lumens.
  - The endometrium thickens, but the coiled spiral arteries remain limited to the deeper layers.
- Point C in the menstrual cycle:
  - Corresponds to the boundary between the proliferative and secretory phases of the menstrual cycle, which represents ovulation.
  - An endometrial biopsy at this time would show a late proliferative endometrium with coiled glands and occasional cytoplasmic vacuoles in the glandular epithelium.
- Point D in the menstrual cycle:
  - Represents the second half of the menstrual cycle (days 15 through 28), progesterone promotes the development of secretory endometrium.
  - **The secretory phase of the menstrual cycle occurs from day 15 through day 28 of the normal menstrual cycle (between ovulation and the onset of menses).**
  - **Progesterone released by the corpus luteum causes the uterine glands to coil and secrete glycogen-rich mucus.**
  - The endometrial stroma becomes **edematous** and completely traversed by tortuous spiral arteries that extend from the deeper layers to the uterine lumen.



**Mid-proliferative phase endometrium (day 7).**  
The endometrium demonstrates uniform development, with a gland:stroma ratio of less than 1:1. The glands are straight and narrow, and contain small lumens.



**Mid-secretory phase endometrium (day 21).**  
The gland:stroma ratio has increased to approximately 1:1 because the amplified stromal volume is associated with marked stromal edema. The glands are dilated and coiled, and contain wide lumens.

### Monitoring the Menstrual Cycle

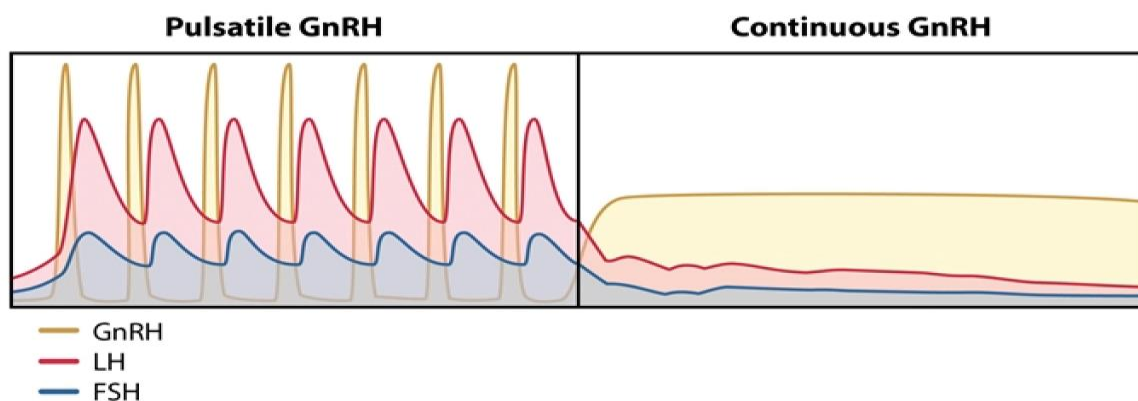
- As mentioned previously, **an increase in urine LH is an indication of the approaching ovulation.**
- Estrogen and progesterone are lipid-soluble hormones and, as such, limited amounts appear in the urine.
- However, during their metabolism (in liver) they are conjugated with a glucuronide or sulfate group and become water soluble.
- These water-soluble metabolites can be followed in the urine:
  - Low progesterone metabolites and low but **slowly** rising estrogen metabolites represent the **early follicular phase**.
  - Low progesterone metabolites but **rapidly** rising estrogen metabolites represent **the latter follicular phase just before ovulation**.
  - **Elevated and rising progesterone metabolites** are indicative of the **first week of the luteal phase before implantation** (this could also be pregnancy).
  - **Elevated but declining progesterone** metabolites indicate the **last week of the luteal phase**.
- Definitions:
  - **Dysmenorrhea:** **Pain** with menses; often associated with endometriosis.
  - **Oligomenorrhea:** > 35-day cycle.
  - **Polymenorrhea:** < 21-day cycle.
  - **Metrorrhagia:** uterine bleeding at **irregular** intervals, particularly between the expected menstrual periods.
  - **Menorrhagia:** **Heavy** menstrual bleeding; > 80 mL blood loss or > 7 days of menses.
  - **Menometrorrhagia:** **Heavy, irregular** menstruation.

## Estrogen

- There are three naturel estrogens:
  - 17 $\beta$ -estradiol: This is **the most potent estrogen** and the main estrogen secreted by the **ovary**.
  - Estrone: It is formed in the ovary and some is released during the menstrual cycle, but it also is formed in **peripheral tissues** from androgens. **It is the main circulating estrogen following menopause (1/10 the potency of estradiol)**.
  - Estriol: This is the main estrogen secreted by the **placenta** during pregnancy from circulating adrenal androgens. It is the least potent of the estrogens (1/100 the potency of estradiol).
  - Ovary (17 $\beta$ -estradiol), placenta (estriol), adipose tissue (estrone via aromatization).
  - Potency: estradiol > estrone > estriol.
- Function:
  - Development of genitalia and breast, female fat distribution.
  - Growth of follicle, endometrial proliferation,  **$\uparrow$  myometrial excitability**.
  - Stimulation of prolactin secretion.
  - $\uparrow$  transport proteins;  $\uparrow$  HDL;  $\downarrow$  LDL.
  - **Estrogens increase the circulating steroid-binding globulins, elevating the bound steroid hormone in the circulation.**
- In Pregnancy:
  - 50-fold  $\uparrow$  in estradiol and estrone.
  - 1000-fold  $\uparrow$  in estriol (indicator of fetal wellbeing).
  - Estrogen receptors expressed in cytoplasm; translocate to nucleus when bound by estrogen (steroid receptors).

## Progesterone

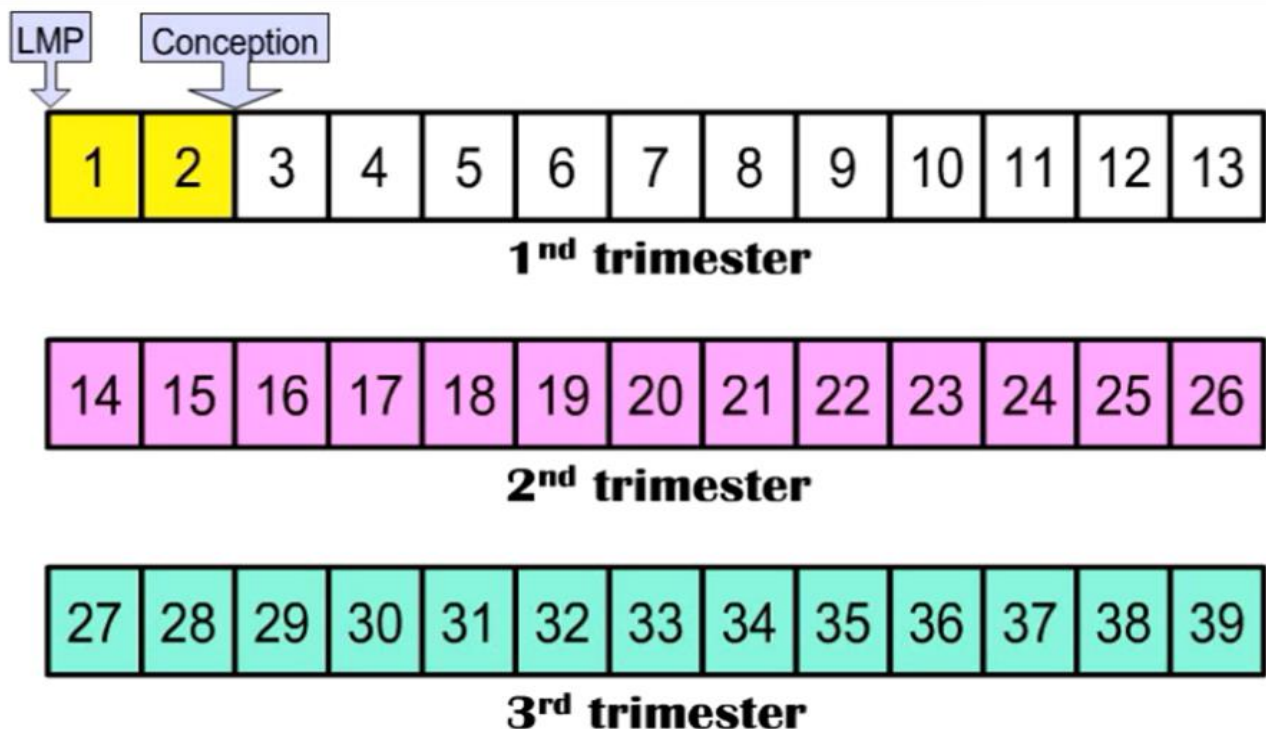
- **Source:** Corpus luteum, placenta, adrenal cortex, testes.
- **Function:**
  - A. **During luteal phase, prepares uterus for implantation of fertilized egg:**
    - Stimulation of endometrial glandular secretions and spiral artery development.
    - Production of thick cervical mucus, which inhibits sperm entry into uterus.
    - Prevents endometrial hyperplasia.
    - ↑ body temperature.
    - ↓ estrogen receptor expression.
    - Inhibition of gonadotropins (LH, FSH).
  - B. **During pregnancy:**
    - Maintenance of pregnancy (Progesterone is **pro-gestation**).
    - ↓ myometrial excitability.
    - Uterine smooth muscle relaxation (preventing contractions).
    - Although prolactin secretion increases as pregnancy progresses, **high progesterone levels inhibit lactation through negative feedback on prolactin in the anterior pituitary.**
- Fall in progesterone after delivery disinhibits prolactin → lactation.
- **Endometrial cells undergo apoptosis upon withdrawal of endocrine stimulation by progesterone.**
- ❖ N.B:
  - Gonadotropin-releasing hormone (GnRH) is a polypeptide that is normally released from the anterior hypothalamus in a **pulsatile manner**. GnRH is carried to the anterior pituitary via the portal circulation, where it stimulates FSH and LH production. **Pulsatile stimulation of pituitary gonadotrophin cells by GnRH leads to upregulation of GnRH receptors and enhanced FSH and LH secretion.**
  - Nonpulsatile (**constant**) infusion of GnRH, or a long-acting analog, **suppresses FSH and LH release and subsequently suppresses gonadal function.**





## Pregnancy

- Fertilization takes place **within one day after ovulation**, most commonly occurs in upper end of fallopian tube (the ampulla).
- The embryo begins development as it is transported to the uterus, and by implantation it has reached the blastocyst stage (about five days after fertilization).
- At the time of **implantation**, the uterus is at its full thickness for the menstrual cycle and progesterone is high (**mid-luteal phase**).
- **A high level of progesterone is absolutely required to maintain pregnancy.**
- Following implantation, the outer trophoblasts of the embryo differentiate, and the outer-most layer becomes the **syncytiotrophoblasts** that have a major endocrine function.
- Weeks of gestational age are, by convention, calculated from the first day of the last menstrual period.
- Biological pregnancy begins two weeks later with fertilization. Thus, fetal age is always two weeks less than gestational age.
- So, in a nutshell:
  - Gestational age: calculated **from the first day of last menstrual period.**
  - Embryonic age: calculated **from date of conception (gestational age minus 2 weeks).**



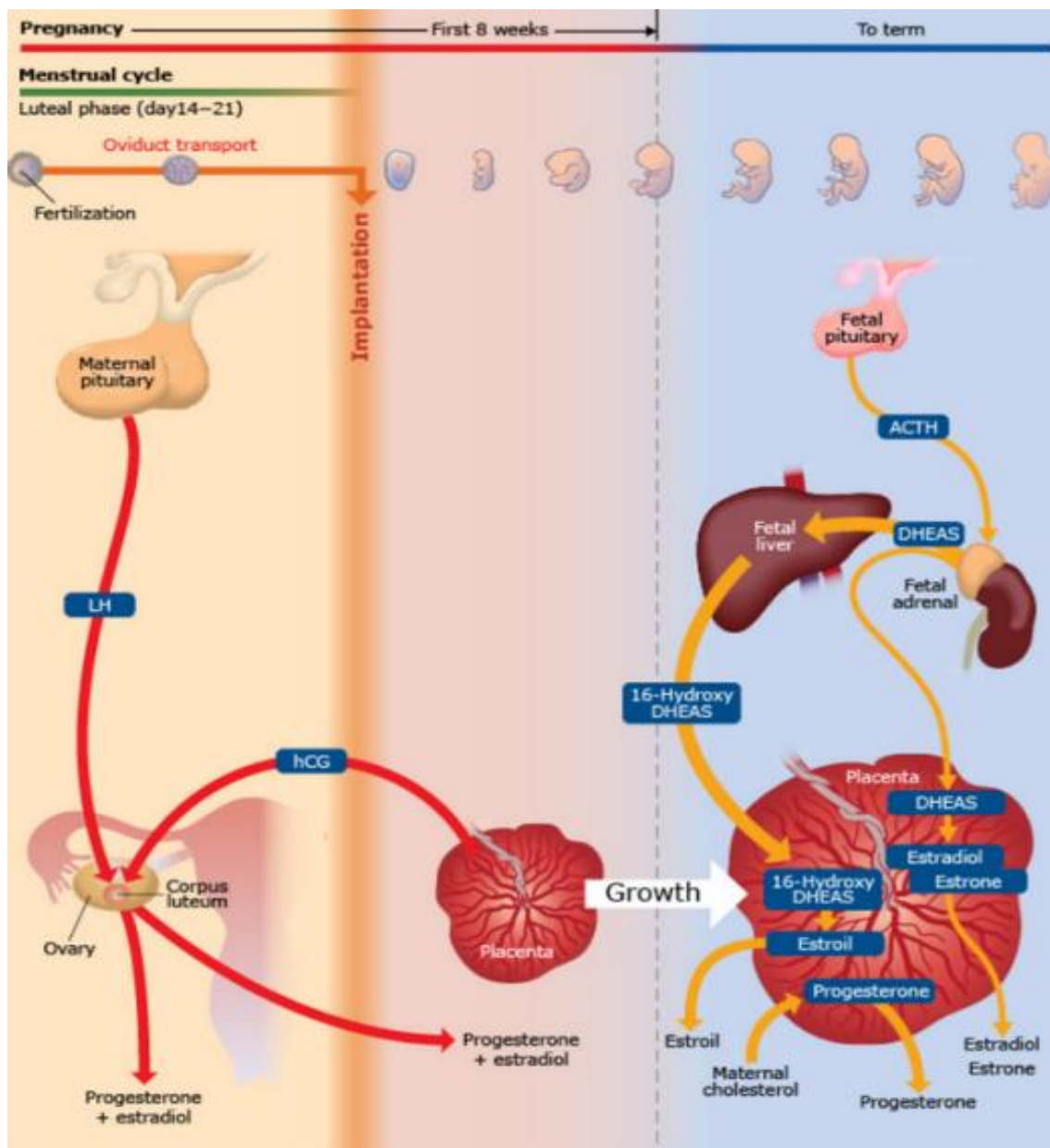
### A. Early Pregnancy (First Two Months)

- Week 1 of the luteal phase prepares the uterus for implantation.
- Pituitary LH → luteal cells → mainly progesterone and some estrogen (**estradiol**).
- At implantation, **the luteal cells are losing sensitivity to LH**.
- Almost immediately, **the syncytiotrophoblasts begin synthesizing and secreting into the maternal circulation human chorionic gonadotropin (hCG)**.
- hCG is almost identical to LH. It has **the same  $\alpha$ -subunit and an almost identical  $\beta$ -subunit, and it will stimulate LH receptors**.
- The important point is that the luteal cells program changes that lead to luteolysis, including an initial loss of sensitivity to LH, **but the receptors maintain a sensitivity to hCG**.
- The hCG rescues the corpus- luteum, it prevents luteolysis and maintains the progesterone and estrogen secretion in early pregnancy.
- **hCG is absolutely required to maintain the first eight weeks of pregnancy. Removal of the ovary containing the corpus luteum in the first seven to eight weeks of pregnancy aborts the developing fetus.**
- hCG concentration **peaks in the first three months of pregnancy, but a reduced secretion continues through the remainder of pregnancy**.

### B. Late Pregnancy: Third Month to Term

- **hGC cannot maintain pregnancy into the second trimester.**
- **The placenta takes over the production of progesterone and estrogen.**
- Progesterone production:
  - Progesterone production is **independent of fetal tissues**. Maternal cholesterol is the substrate and it is converted to progesterone with no feedback control.
  - Maternal progesterone **rises continuously throughout the remainder of pregnancy**.
  - Because fetal tissues are not involved in the synthesis of progesterone, **this cannot be used as an index of fetal health**.

- Estrogen production:
  - They are similar to granulosa cells in that the precursors are **androgens**.
  - The androgen synthesizing cells reside in the inner region of the **fetal adrenal cortex**.
  - The major end-product is DHEA-sulfate, and its production is **dependent on fetal ACTH**.
  - The placenta secretes CRH (corticotropin-releasing hormone) into the fetal circulation, which drives ACTH secretion.
  - When delivered to the placenta, it is converted to **estriol**.
  - Because estrogen synthesis is dependent on fetal tissues, **it can be used as an index of fetal health and placental**.



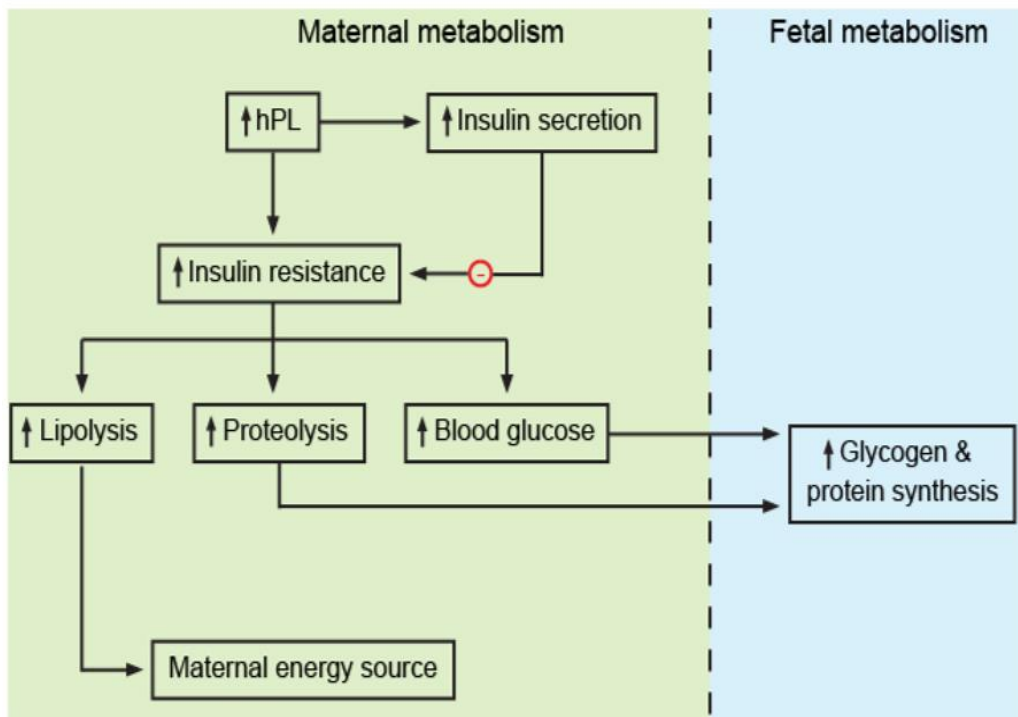
### hCG (Human chorionic gonadotropin)

- Source: Syncytiotrophoblast of placenta.
- Function:
  - Maintains corpus luteum (and thus progesterone) for first 8-10 weeks of pregnancy by acting like LH (otherwise no luteal cell stimulation → abortion).
  - Has identical  $\alpha$  subunit as LH, FSH, TSH (states of  $\uparrow$  hCG can cause hyperthyroidism).
  - $\beta$  subunit is unique (pregnancy tests detect  $\beta$  subunit).
  - hCG is  $\uparrow$  in multiple gestations, hydatidiform moles, choriocarcinomas, and Down syndrome.
  - hCG is  $\downarrow$  in ectopic/failing pregnancy, Edward syndrome, and Patau syndrome.

### hPL (Human Placental Lactogen)

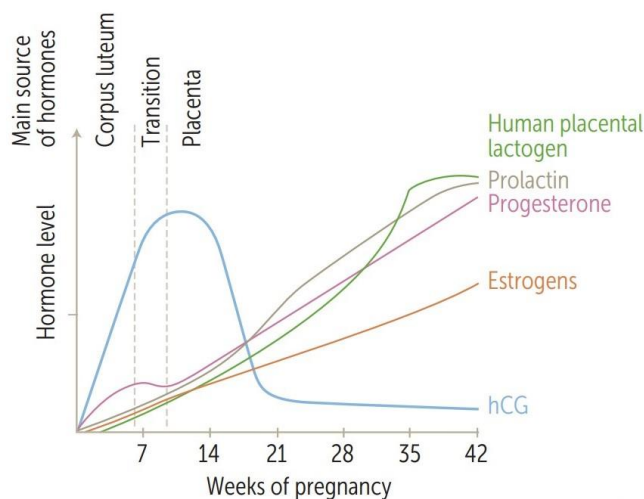
- Also called Human Chorionic Somatomammotropin.
- Produced by the syncytiotrophoblasts.
- The quantity of hormone secreted is directly related to the size of the placenta. Thus, the plasma levels rise throughout pregnancy.
- Pregnancy is associated with profound alterations in maternal metabolism. Carbohydrate metabolism is shunted toward supplying glucose and amino acids to the fetus, while excess free fatty acids, ketones, and glycerol provide energy to the mother. This is accomplished primarily through placental hormones, particularly human placental lactogen.
- It increases maternal insulin resistance, which decreases maternal glucose utilization and increases blood glucose levels, thus allowing glucose to be shunted toward the fetus.
- In response to hypoglycemia, hPL levels rise in an attempt to maintain an adequate fetal glucose supply.
- Maternal lipolysis and proteolysis are also increased by hPL, with the resulting free fatty acids and ketones providing energy to the mother, thus freeing relatively more glucose for fetal use.
- Gestational diabetes mellitus results when a woman's pancreatic function is not sufficient to overcome this pregnancy-related increase in insulin resistance. If the diabetes resolves upon delivery, it is referred to as gestational diabetes.

## Metabolic effects of human placental lactogen



## Hormonal changes during pregnancy

- There is a **progressive rise in progesterone and estradiol during pregnancy**. Estradiol and estrone show similar increases but at lower concentrations.
- Prolactin **rises parallel to estrogen**.
- hCG **peaks in the first trimester** but continues to be secreted throughout pregnancy.
- hPL **begins to rise in early pregnancy but the greatest plasma levels are in the latter part of pregnancy**.
- Pituitary gonadotropins are **suppressed** during pregnancy.



### Physiologic Adaptations to Pregnancy







- **↑ cardiac output** (↑ preload, ↓ afterload, ↑ HR → ↑ placental and uterus perfusion).
- **BP ↓** in first 24 weeks with gradual return to normal due to ↓ peripheral vascular resistance because of **progesterone mediated smooth muscle relaxation**.
- **Anemia** (↑ plasma volume by **50%**, RBC mass only ↑ by **30%** → ↓ viscosity).
- **Hypercoagulability** (to ↓ blood loss at delivery) due to ↑ clotting factors and venous stasis secondary to uterine pressure on great veins of lower extremity.
- Hyperventilation (eliminate fetal CO<sub>2</sub>) because **progesterone directly stimulates central respiratory center**.
- ↑ Progesterone leads to ↓ bladder tone (smooth muscles relaxation) → urinary stasis **predisposes to UTI/pyelonephritis**.
- GFR is elevated and renal threshold decreases:
  - **Renal plasma flow, GFR, and creatinine clearance all increase** (secondary to a 50% increase in plasma volume).
  - Increase in GFR → INCREASE in the filtered load of glucose → when the blood glucose level exceeds certain threshold, the proximal tubule becomes overwhelmed and begins to excrete glucose in the urine.
- ↑ Thyroid binding globulin (TBG):
  - Due to ↑ estrogen.
  - Leading to ↑ total T<sub>3</sub> and T<sub>4</sub>.
  - Free T<sub>3</sub> and T<sub>4</sub> remain the same (pregnant women are euthyroid).
  - **Levothyroxine requirements increase during pregnancy**. Patients with hypothyroidism should increase their levothyroxine dose at the time pregnancy is detected, with subsequent dose adjustments based on TSH and total T<sub>4</sub>.

### Apgar score

- Assessment of newborn vital signs following labor via a 10-point scale evaluated at 1 minute and 5 minutes.
- **Apgar** score is based on **A**ppearance, **P**ulse, **G**rimace, **A**ctivity, and **R**espiration.
- Apgar scores < 7 require further evaluation.



- If Apgar score remains low at later time points, there is ↑ risk the child will develop long-term neurologic damage.

	Score 2	Score 1	Score 0
<b>A</b> pppearance	 Pink	 Extremities blue	 Pale or blue
<b>P</b> ulse	≥ 100 bpm	< 100 bpm	No pulse
<b>G</b> rimace	Cries and pulls away	Grimaces or weak cry	No response to stimulation
<b>A</b> ctivity	 Active movement	 Arms, legs flexed	 No movement
<b>R</b> espiration	Strong cry	Slow, irregular	No breathing

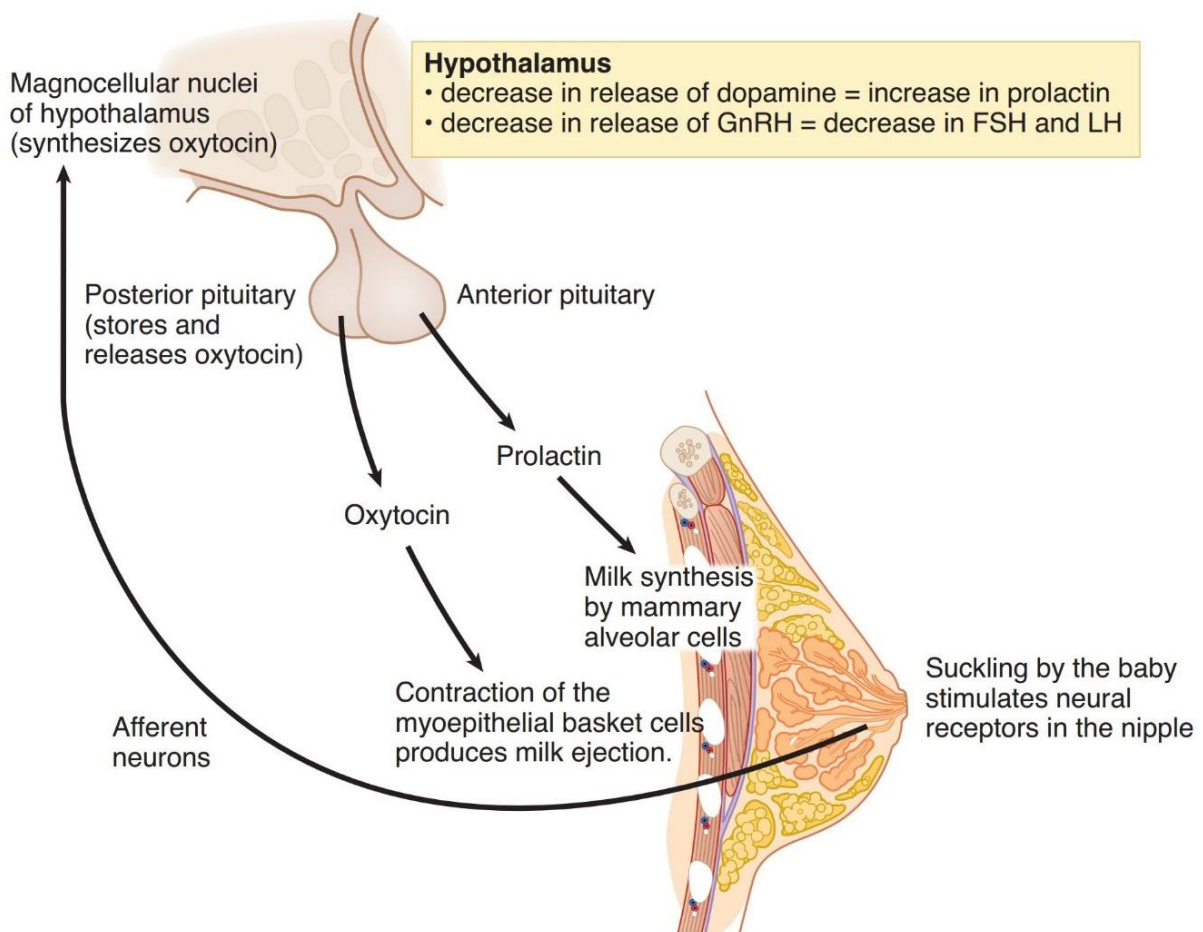
### Low birth weight

- Defined as < 2500 g.
- Caused by prematurity or intrauterine growth restriction (IUGR).
- Associated with ↑ risk of sudden infant death syndrome (SIDS) and with ↑ overall mortality.

### Lactation

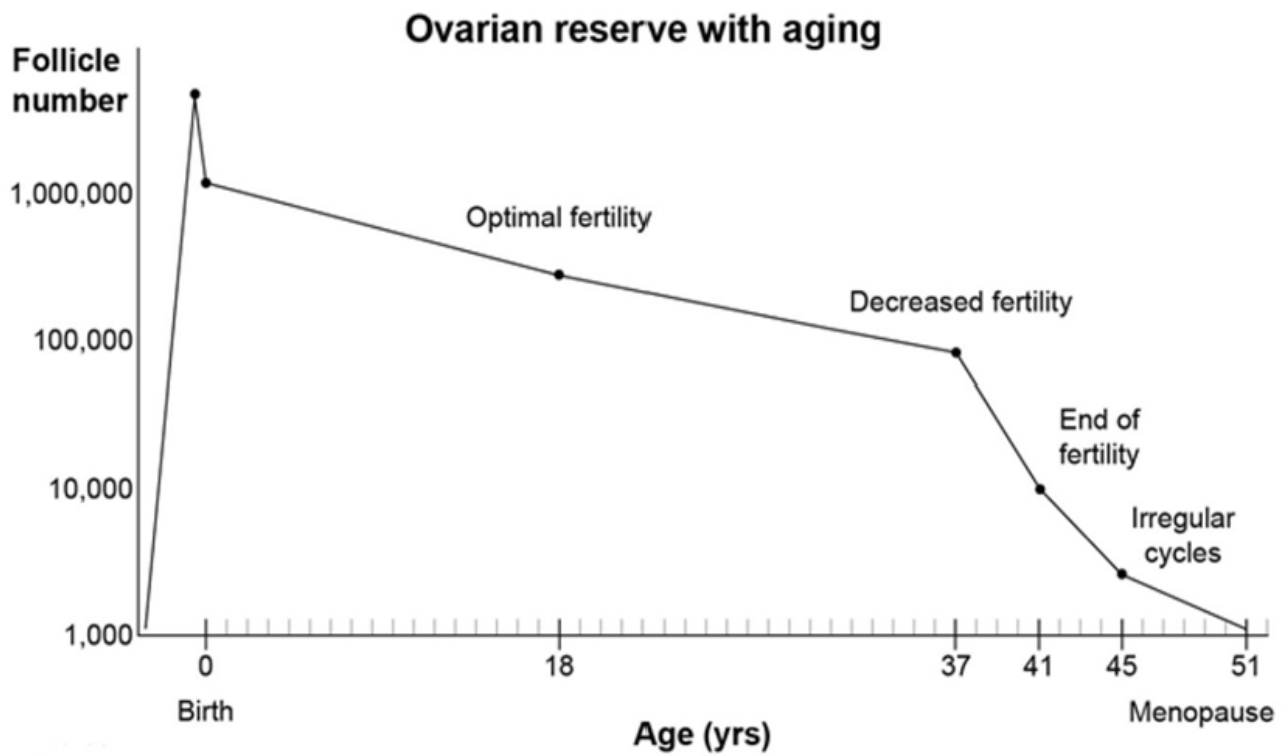
- After parturition and delivery of placenta, rapid ↓ in progesterone disinhibits prolactin → initiation of lactation.
- Tactile or mechanoreceptors in the nipple region increase afferent activity to the hypothalamus.

- The afferent activity has three main effects:
  - The release of oxytocin from the posterior pituitary causes contraction of the myoepithelia cells surrounding the mammary alveoli, producing milk ejection.
  - Decreases the release of dopamine, which maintains prolactin secretion and milk synthesis.
  - Decreases the release of GnRH, causing in some cases a functional amenorrhea, which has been termed **nature's contraceptive**. Prolactin itself will decrease the release of GnRH.
- **Prolactin:** induces and maintains lactation and ↓ reproductive function.
- **Oxytocin:** assists in milk letdown; also promotes uterine contractions.
- Breast milk is the ideal nutrition for infants < 6 months old. Contains maternal immunoglobulins (conferring passive immunity; mostly IgA), macrophages, lymphocytes. Breast milk reduces infant infections and is associated with ↓ risk for child to develop asthma, allergies, diabetes mellitus, and obesity.
- Guidelines recommend exclusively breastfed infants get vitamin D and possibly iron supplementation.
- Breastfeeding ↓ maternal risk of breast and ovarian cancer and facilitates mother-child bonding.



## Menopause

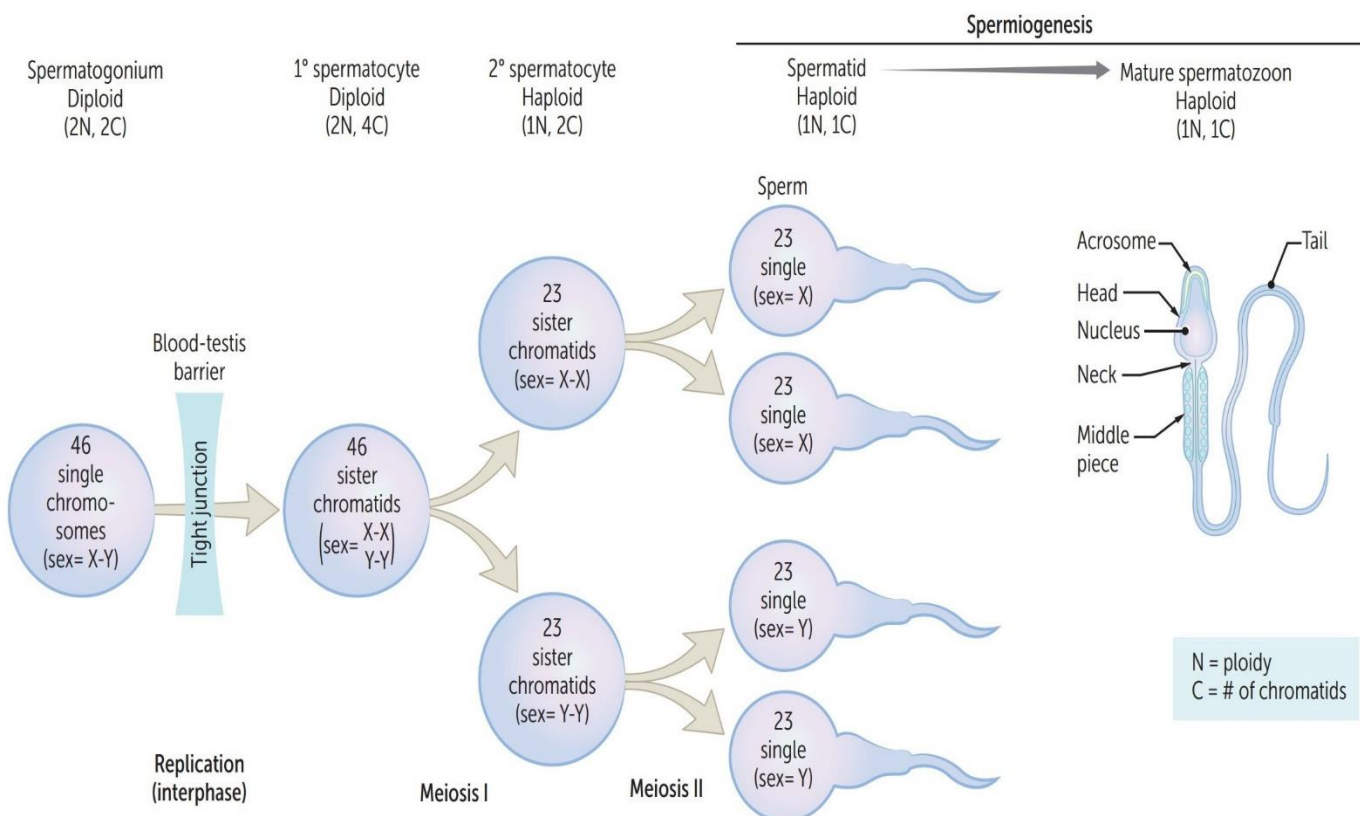
- Menopause is a retrospective diagnosis and is defined as **12 months of amenorrhea**.
- Progressive loss of ovarian follicle units (atresia) throughout reproductive life causes a decrease in ovarian production of estrogen and reduces negative feedback to anterior pituitary, **leading to an increase in FSH and LH levels**.
- **↑↑ FSH is specific for menopause (loss of negative feedback on FSH due to ↓ estrogen)**.
- Hormonal changes: ↓ estrogen, **↑↑ FSH**, ↑ LH (no surge), ↑ GnRH.
- ↓ estrogen production due to age-linked decline in number of ovarian follicles.
- Average age at onset is **51 years** (earlier in smokers).
- Usually preceded by 4–5 years of abnormal menstrual cycles (**anovulatory cycles**).
- Source of estrogen (**estrone**) after menopause becomes peripheral conversion of androgens, ↑ androgens → hirsutism (total testosterone remains unchanged while estrogen decreases markedly creating a state of relative androgen excess).
- Symptoms are caused by **loss of ovarian source of estrogen**:
  - Hirsutism (male-pattern hair growth in women) via ↑ androgens.
  - Hot flashes (feeling of intense heat with sweating and rapid heartbeat, often accompanied by visible reddening of the face due to **vascular instability**).
  - Atrophy of vagina (thinning of vaginal epithelium).
  - ↓ vaginal secretions.
  - Osteoporosis.
  - Coronary artery disease.
  - Causes **HAVOCS**: **H**ot flashes, **A**троphy of the Vagina, **O**steoporosis, **C**oronary artery disease, **S**leep disturbances.
- **Menopause before age 40 suggests 1° ovarian insufficiency (premature ovarian failure)**. Causes of premature ovarian failure include **chemotherapy**, radiation, and autoimmune ovarian failure.



## The Male Reproductive System

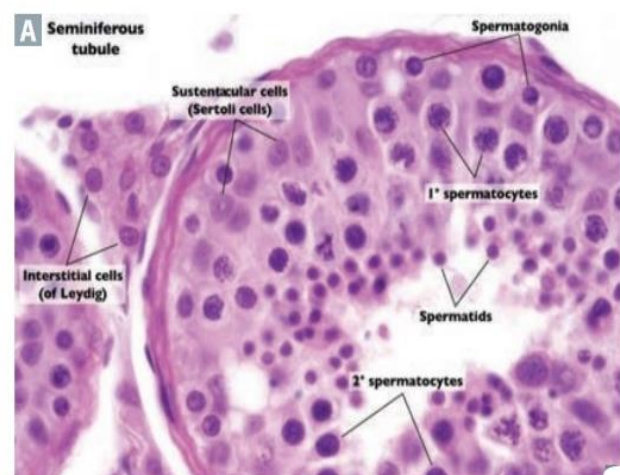
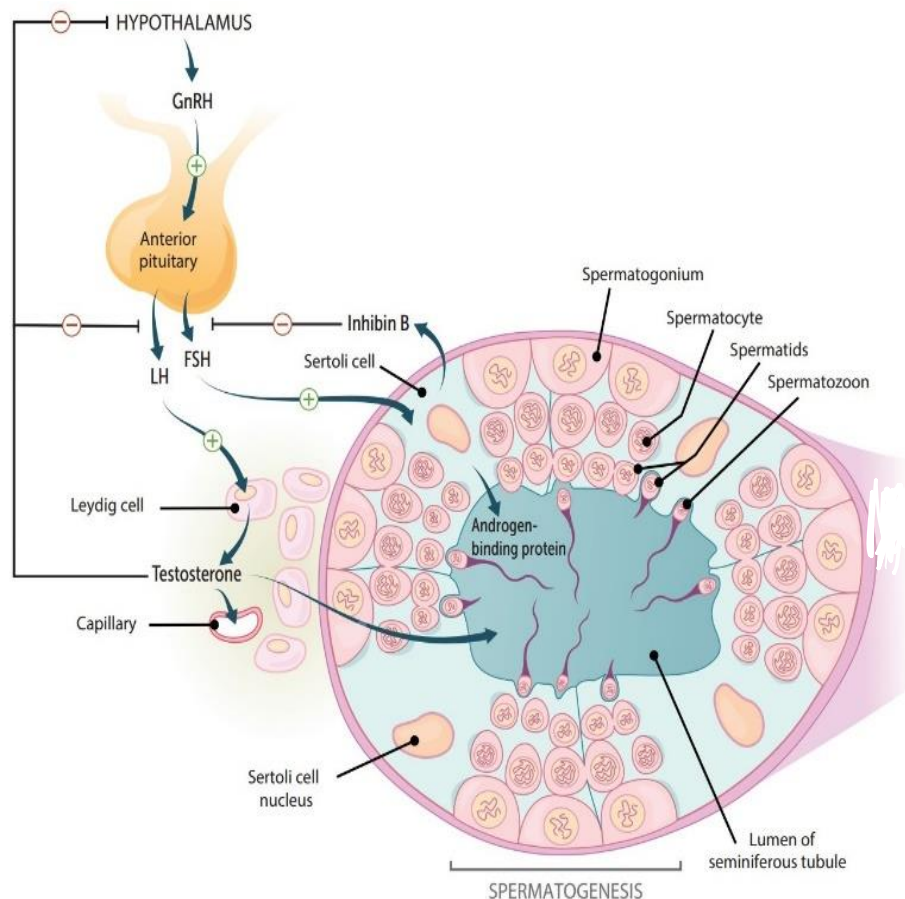
### Spermatogenesis

- Primordial germ cells arrive in the indifferent gonad at week 4 and remain dormant until puberty.
- When a boy reaches **puberty**, primordial germ cells differentiate into **spermatogonia**, which **serve as stem cells throughout adult life**.
- Spermatogonia enter meiosis I to form primary spermatocytes.
- Primary spermatocytes form 2 secondary spermatocytes.
- Secondary spermatocytes enter meiosis II to form 2 spermatids.
- Spermatids undergo spermiogenesis (loss of cytoplasmic contents, gain of acrosomal cap), which is a series of morphological changes resulting in the mature spermatozoa.
- "Gonium"** is **going** to be a sperm; **"Zoon"** is **"Zooming"** to egg.
- Tail mobility impaired in **ciliary dyskinesia/Kartagener syndrome** → infertility. Tail mobility normal in cystic fibrosis (in CF, absent vas deferens → infertility).



## Organization of the Testes

- The testes reside in the scrotum outside the abdominal cavity where the temperature is about 2°C lower, **a requirement for normal spermatogenesis**.
- Spermatogenesis takes place within **the epithelial cells (Sertoli cells) lining the seminiferous tubules**.



## Seminiferous tubules

- Spermatogonia (germ cells):**
  - Location:** Line seminiferous tubules.
  - Function:**
    - Maintain germ pool and produce 1° spermatocytes.



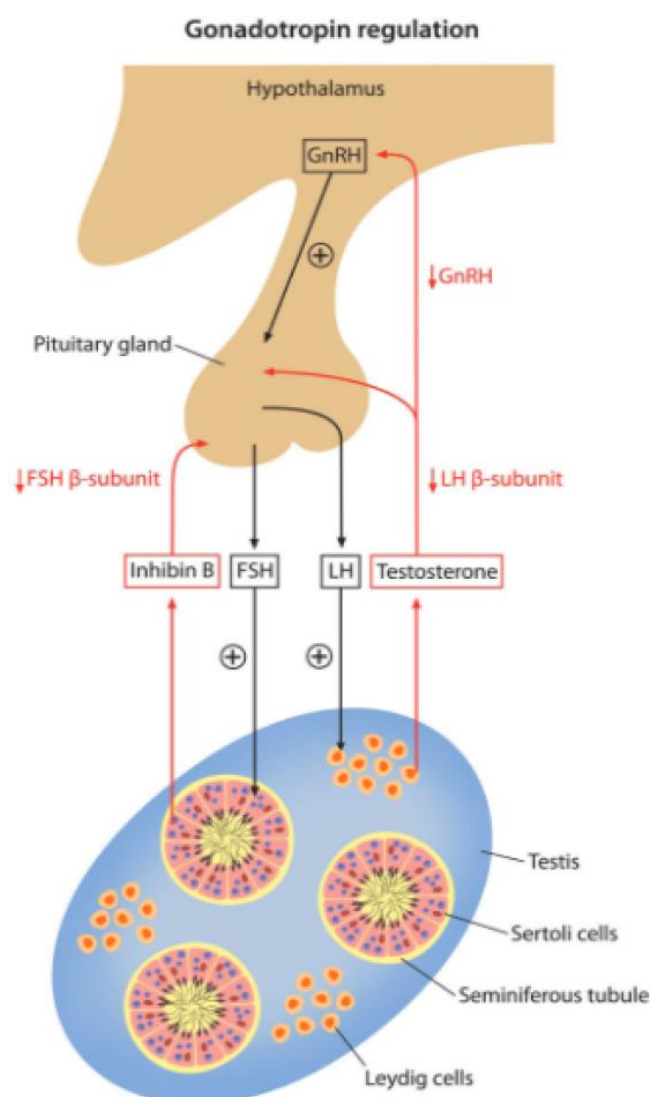
## 2. Sertoli cells (non-germ cells):

- Location: Line seminiferous tubules.
- Function:
  - Homolog of female granulosa cells.
  - Produce MIF (Mullerian inhibiting factor).
  - Sertoli cells possess FSH receptors and FSH stimulates Sertoli function.
  - Convert testosterone and androstenedione to estrogens via aromatase.
  - Secrete androgen-binding protein → maintain local levels of testosterone.
  - Regulate spermatogenesis.
  - They are the nurse cells for the developing sperm. Support and nourish developing spermatozoa.
  - Tight junctions between adjacent Sertoli cells form blood-testis barrier → isolate gametes from autoimmune attack.
  - FSH stimulates the release of inhibin B from the Sertoli cells. Testosterone and inhibin B induce negative feedback on LH and FSH production, respectively.
  - Temperature sensitive: ↓ sperm production and ↓ inhibin B with ↑ temperature. ↑ temperature seen in varicocele, cryptorchidism.
  - Sertoli cells are inside Seminiferous tubules, Support Sperm Synthesis, and inhibit FSH.

## 3. Leydig cells (endocrine cells):

- Location: Interstitium.
- Function:
  - Homolog of female theca interna cells.
  - LH receptors are located on the Leydig cell's outer membrane.
  - Secrete testosterone in the presence of LH.
  - Anterior pituitary LH promotes Leydig cell growth and proliferation as well as stimulating the pathway from cholesterol to testosterone. A small amount of testosterone is converted into dihydrotestosterone (DHT).

- Significant amounts of the testosterone diffuse into the Sertoli cells. Much of it becomes concentrated in the seminiferous tubules bound to an androgen-binding protein secreted by the Sertoli cells. This high concentration of testosterone is required for normal spermatogenesis.
  - Testosterone production unaffected by temperature.
- ❖ N.B:
- Inhibin B is produced by the Sertoli cells and is the physiological inhibitor of FSH secretion.
  - LH concentration is controlled primarily by testosterone feedback.
  - Impaired Sertoli cell function would lead to decreased production of inhibin, increased FSH levels, and impaired fertility.



## Androgens

### ▪ Source:

- Dihydrotestosterone and testosterone (testis), Androstenedione (Adrenal).
- Potency: DHT > testosterone > androstenedione.
- Testosterone is converted to DHT by 5 $\alpha$ -reductase, which is inhibited by finasteride.
- Testosterone and DHT bind to the same androgen receptor, but DHT does so with a much higher affinity. DHT is therefore the more active form of the hormone.

### ▪ Function:

#### A. Testosterone:

- Differentiation of male internal genitalia except prostate: Seminal vesicles, Epididymis, Ejaculatory duct, Ductus deferens (SEED).
- Growth spurt: penis, seminal vesicles, sperm, muscle, RBCs.
- Closing of epiphyseal plates (via estrogen converted from testosterone). Sex steroids initially increase linear growth, but they also encourage closure of epiphyseal growth plates. Once the growth plates have closed, linear growth is irreversibly stopped.
- Deepening of voice, Libido.

#### B. DHT:

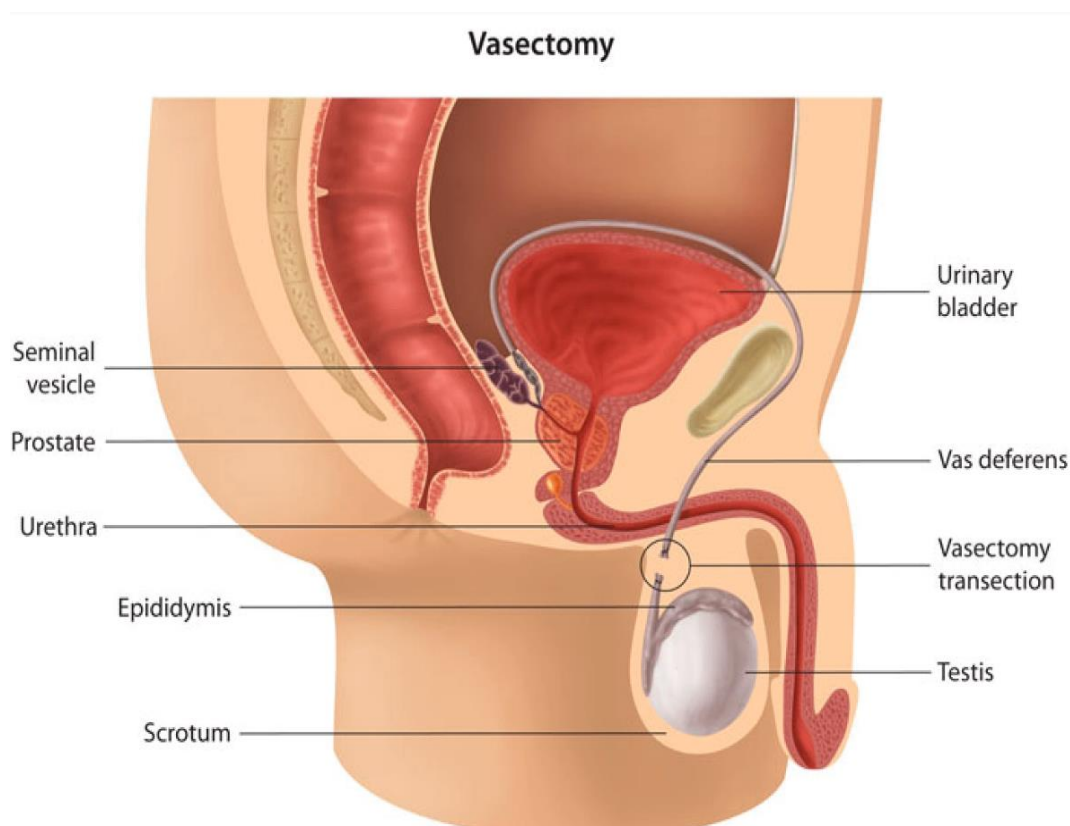
- Early: differentiation of penis, scrotum, prostate.
- Late: prostate growth, balding, sebaceous gland activity.

### ▪ Androgenic steroid abuse:

- Abuse of anabolic steroids → ↑ fat-free mass, muscle strength, and performance.
- Suspect in men who present with changes in behavior (aggression), acne, gynecomastia, ↑ Hb and Hct, small testes (exogenous testosterone → hypothalamic pituitary-gonadal axis inhibition → ↓ intratesticular testosterone → ↓ testicular size, ↓ sperm count, azoospermia).
- Women may present with virilization (hirsutism, acne, breast atrophy, male pattern baldness).

## ❖ N.B:

- Vasectomy is a surgical procedure for male sterilization and/or permanent contraception.
- Vasectomy involves **transection of the vas deferens**.
- **However, the procedure blocks only the vas deferens at the point where it is sealed and has no effect on sperm proximal to the ligation.**
- **Viable sperms remain in the portion of the vas deferens proximal to the ligation**
- Sexual intercourse can typically be resumed within a week following the procedure, yet **pregnancy is still possible as viable sperm may be present in the ejaculate.**
- **In fact, 20% of patients still have viable sperm after 3 months and at least 20 ejaculations.**
- Therefore, another method of birth control must be used after the vasectomy until a sperm sample confirms azoospermia.



## Tanner stages of sexual development

- Tanner stage is **assigned independently to genitalia, pubic hair, and breast** (a person can have Tanner stage 2 genitalia, Tanner stage 3 pubic hair).
- Earliest detectable secondary sexual characteristic is breast bud development in girls, testicular enlargement in boys.

♂					
♀					
<div> <div> <h3>Stage I</h3> <p>No sexual hair ♂ ♀ Flat-appearing chest with raised nipple ♀</p> <p>Pre-pubertal</p> </div> <div> <h3>Stage II</h3> <p>Pubic hair appears ♂ ♀ (pubarche) Testicular enlargement ♂ Breast bud forms (thelarche), mound forms ♀</p> <p>~ 8–11.5 years</p> </div> <div> <h3>Stage III</h3> <p>Coarsening of pubic hair ♂ ♀ Penis size/length ↑ ♂ Breast enlarges ♀</p> <p>~ 11.5–13 years</p> </div> <div> <h3>Stage IV</h3> <p>Coarse hair across pubis, sparing thigh ♂ ♀ Penis width/glans ↑ ♂ Breast enlarges, raised areola, mound on mound ♀</p> <p>~ 13–15 years</p> </div> <div> <h3>Stage V</h3> <p>Coarse hair across pubis and medial thigh ♂ ♀ Penis and testis enlarge to adult size ♂ Adult breast contour, areola flattens ♀</p> <p>Usually &gt; 15 years</p> </div> </div>					

### Precocious puberty

- Appearance of 2° sexual characteristics (adrenarche, thelarche, menarche) **before age 8 years in girls and 9 years in boys**.
- ↑ sex hormone exposure or production → ↑ linear growth, somatic and skeletal maturation (premature closure of epiphyseal plates → short stature).
- Types include:
  - A. **Central precocious puberty (GnRH secretion):**
    - Idiopathic (**most common**; early activation of hypothalamic-pituitary gonadal axis).
    - CNS tumors.
  - B. **Peripheral precocious puberty (GnRH-independent; ↑ sex hormone production or exposure to exogenous sex steroids):**
    - Congenital adrenal hyperplasia.
    - Estrogen-secreting ovarian tumor (granulosa cell tumor).
    - Leydig cell tumor.
    - McCune-Albright syndrome (autonomous stimulation of aromatase enzyme production of estrogen by the ovaries).



## **CHAPTER 4**

# **Pathology**

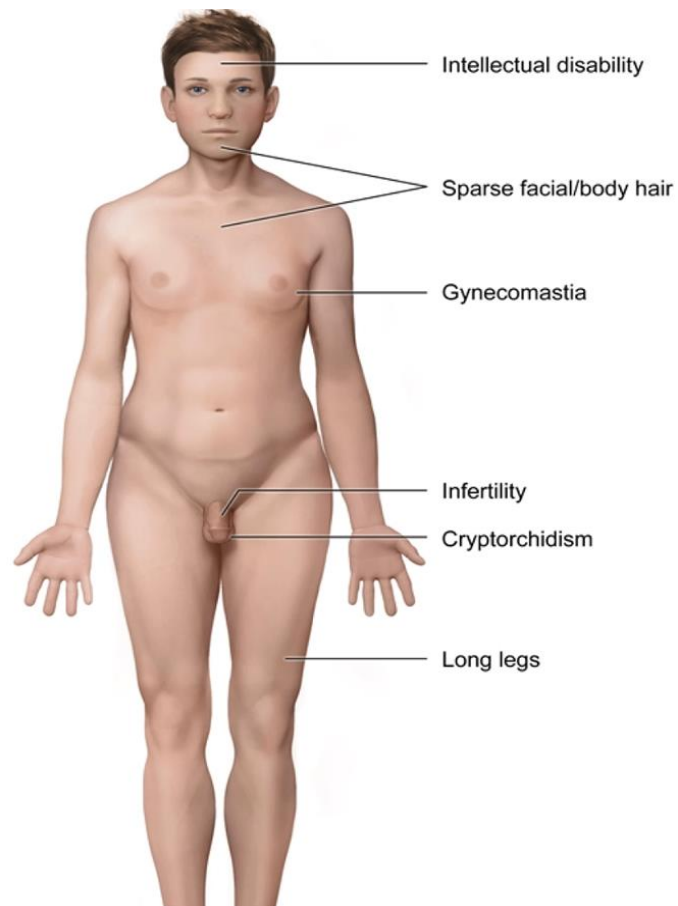
## Sex chromosome disorders

## Klinefelter syndrome [male] (47, XXY)

- The **47 XXY karyotype** is diagnostic of Klinefelter syndrome.
- The extra sex chromosome is acquired due to "**meiotic nondisjunction**" during gametogenesis.
- Presence of inactivated X chromosome (Barr body).
- Neonates are phenotypically normal. **Signs do not become evident until puberty.**
- The major features of this disorder are described below:
  1. **Klinefelter syndrome causes primary testicular failure due to:**
    - **Hyalinization and fibrosis of the seminiferous tubules** causing the testes to be **small and firm**.
    - Dysgenesis of seminiferous tubules → ↓ inhibin B → **↑ FSH**.
    - Abnormal Leydig cell function → ↓ testosterone → **↑ LH**.
    - **↑ estrogen due to increased aromatase activity (↑ testosterone to estradiol conversion).**
    - These abnormalities result in **oligo/azoospermia, infertility**, and **absence of secondary sex characteristics**.
    - Common cause of hypogonadism seen in infertility work-up.
  2. **Testosterone deficiency also leads to the characteristic eunuchoid body habitus:**
    - **Facial and body hair is absent and muscle mass is decreased.**
    - Patients have **tall stature** and **gynecomastia**.
    - The **short-stature homeobox gene (SHOX)**, also known as short-stature-homeobox-containing gene, is a gene located on both the X and Y chromosomes, which is associated with short stature in humans if mutated or present in only one copy (haploinsufficiency).
    - **Turner syndrome**, where there is loss of genetic material from the X chromosome, typically by loss of one entire X chromosome → **short stature**.
    - Gene dosage effects of **extra copies of SHOX** may be a cause of the **tall stature** seen in XYY, Klinefelter XXY and similar syndromes.

## 3. Cognitive symptoms:

- Mild mental retardation is seen in some patients, though the majority have normal intelligence.

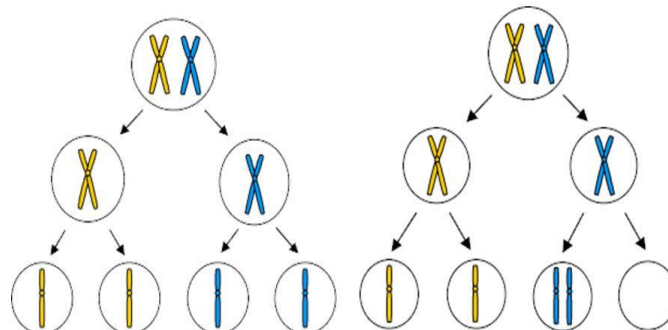


## Nondisjunction

- The failure of homologous chromosomes to separate properly during meiosis.

What should happen

Nondisjunction



### Turner syndrome [female] (45, XO)

- The classic variant of **complete monosomy (45, XO)** occurs in about **50-60%** of Turner syndrome patients due to **meiotic nondisjunction** (more frequent in **sperms**), with another **30%** demonstrating **mosaicism**.
- In the mosaic population, one genetic line contains cells with a normal number of chromosomes (46, XX), while the other genetic line contains cells that are monosomy (45, XO). **Both lines originate from a single zygote**.
- **Most fetuses possessing the 45, XO karyotype abort spontaneously**, with studies suggesting that 15% of all spontaneous abortions are due to Turner syndrome.
- Clinical manifestations of Turner syndrome include the abnormalities listed below:
  1. **Phenotypic abnormalities:**
    - **Short stature** (associated with **SHOX** gene, preventable with growth hormone therapy), webbed neck, low posterior hair line, **shield chest (broad chest with widely spaced nipples)**, shortened 4th metacarpals.
    - **Short stature is the most common clinical finding in patients with Turner syndrome.**
  2. **Urogenital abnormalities:**
    - The ovaries become infiltrated with fibrous tissue (**streak ovaries**) → decreased estrogen and increased gonadotropins (loss of negative feedback), **Primary amenorrhea**, absent secondary sex characteristics, minimal or no thelarche (breast development), **horseshoe kidney** (fusion of kidneys at the midline).
    - ↓ estrogen leads to ↑ LH, FSH.
    - **Most common cause of 1° amenorrhea**. Menopause before menarche.
    - Pregnancy is possible in some cases (IVF, exogenous estradiol-17β and progesterone).
    - Because ovaries normally produce estrogen, **patients with TS are estrogen deficient**. Estrogen normally serves to inhibit osteoclast-mediated bone resorption, leading to increased bone mineral density.
    - **The lack of estrogen in patients with TS therefore leads to increased bone resorption, which causes decreased bone mineral density and increased risk of osteoporosis. Estrogen replacement therapy is therefore given to girls with TS to promote normal sexual maturation and reduce the risk of osteoporosis.**

### 3. Cardiac abnormalities:

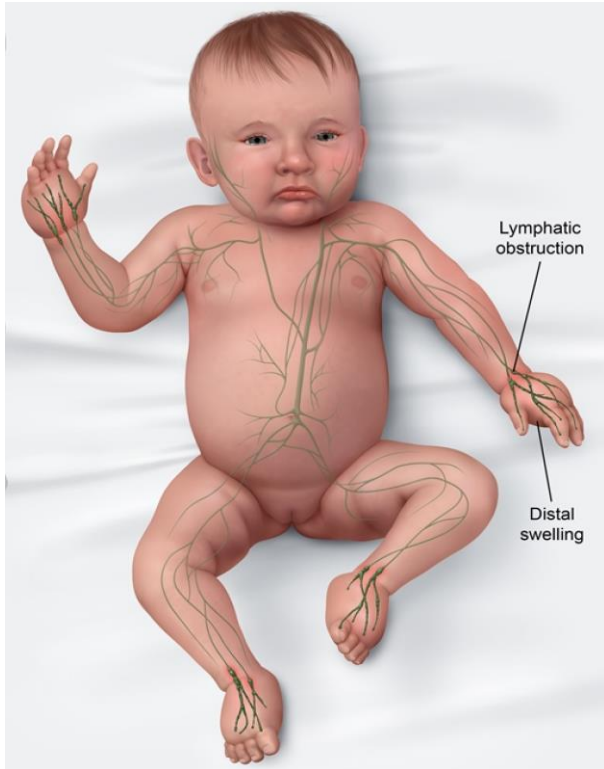
- Coarctation of the aorta (3%-10%), bicuspid aortic valve 20%-30%).
- Patients with TS should undergo echocardiography to evaluate for bicuspid aortic valve, coarctation of the aorta, and aortic root dilation.

### 4. Lymphatic abnormalities:

- The edema is likely due to congenital lymphedema from abnormal development of the lymphatic network.
- The dysfunctional lymphatic system causes accumulation of protein-rich interstitial fluid in the hands, feet (Edema of extremities in neonates), and neck (webbed neck).
- Severe obstruction of lymphatic vessels can result in cystic hygroma of the neck and fetal hydrops.
- Lymphedema is generally nonpitting as opposed to the pitting edema seen with liver failure, congestive heart failure, or nephrotic syndrome.

### ❖ What is Barr bodies?

- Barr body is an inactivated X chromosome seen as a small, perinuclear, dark-staining dot in somatic cells with two or more X chromosomes.
- The number of Barr bodies is one less than the number of X chromosomes in an individual.
- One Barr body means the individual has two X chromosomes, two Barr bodies means the individual has three X chromosomes, etc.
- Normal males never express these "Barr bodies."
- So, in a nutshell:
  - Normal female: one Barr body.
  - Normal male: no Barr body.
  - Turner's (45X0): no Barr body.
  - Klinefelter (47XXY): one Barr body.



## Turner syndrome

Narrow, high-arched palate

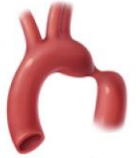Low hairline

Webbed neck

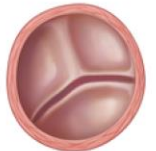Broad chest with widely spaced nipples

Cubitus valgus

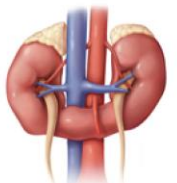Short stature



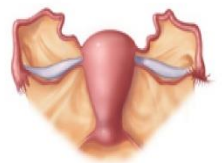
Coarctation of aorta



Bicuspid aortic valve

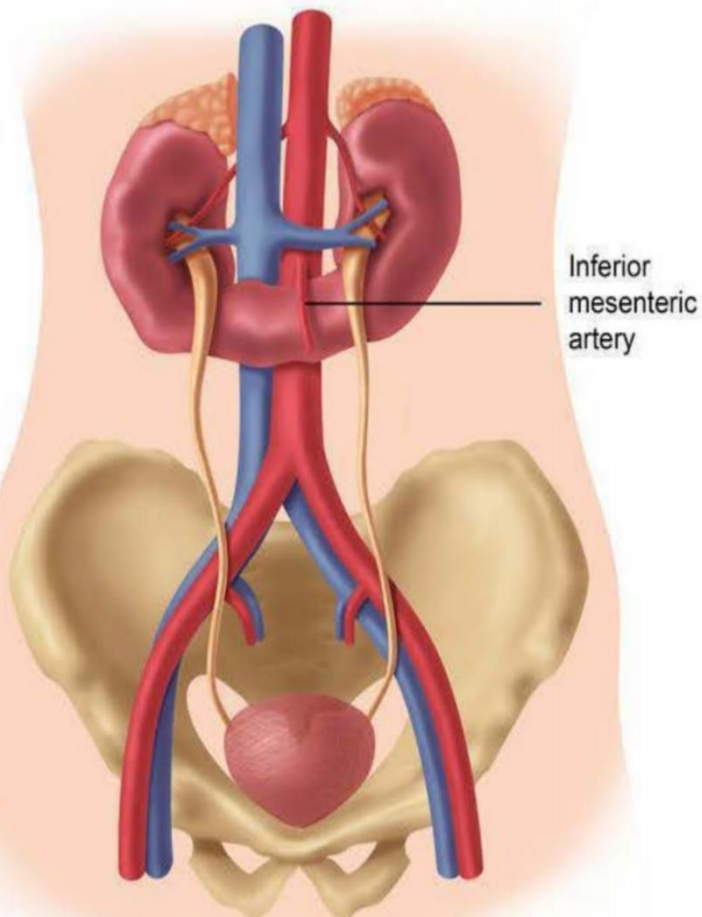


Horseshoe kidney

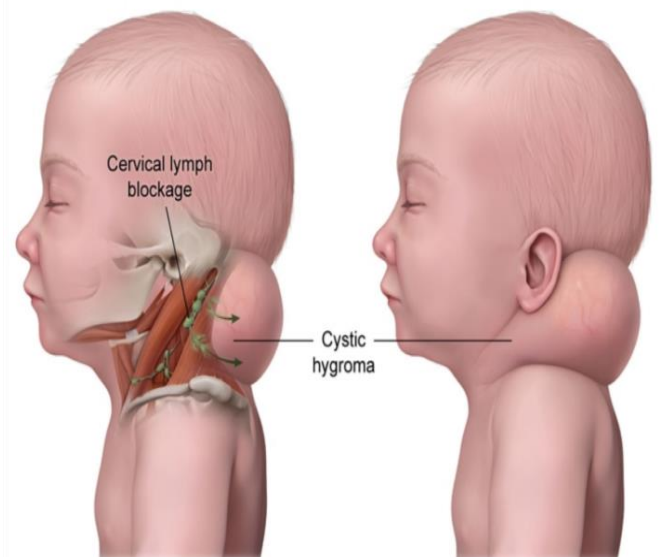


Streak ovaries, amenorrhea &amp; infertility

## Horseshoe Kidney



## Cystic hygroma





### Double Y males (XYY)

- **Phenotypically normal** (usually undiagnosed), **very tall**.
- **Normal fertility**.
- May be associated with severe acne, learning disability, autism spectrum disorders.

### Ovotesticular disorder of sex development

- **Previously called true hermaphroditism**.
- Both ovarian and testicular tissue present (ovotestis); ambiguous genitalia.
- 46, XX > 46, XY.

### Other disorders of sex development

- **Disagreement (mismatch) between the phenotypic sex** (external genitalia, influenced by hormonal levels) **and the gonadal sex** (testes vs ovaries, corresponds with Y chromosome).
- Includes the terms pseudohermaphrodite, hermaphrodite, and intersex.

#### A. 46,XX DSD:

- **Ovaries present**, but external genitalia are virilized or ambiguous.
- **Due to excessive and inappropriate exposure to androgenic steroids during early gestation** (congenital adrenal hyperplasia or exogenous administration of androgens during pregnancy).

#### B. 46,XY DSD:

- **Testes present**, but external genitalia are female or ambiguous.
- **Most common form is androgen insensitivity syndrome (testicular feminization)**.

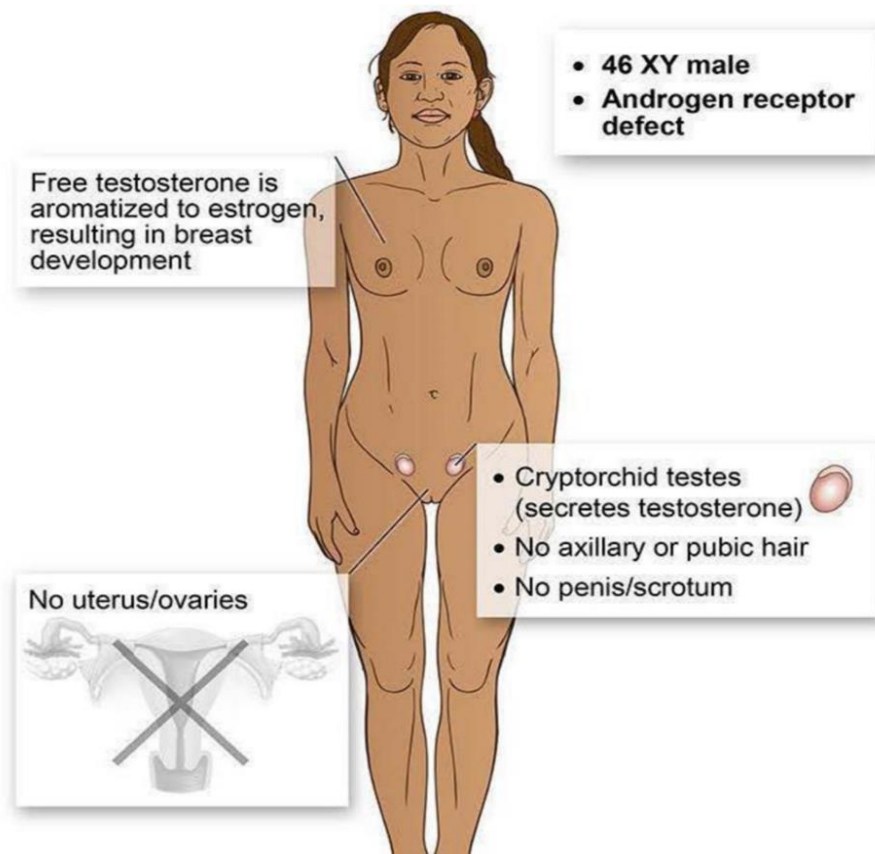
### Disorders by physical characteristics

UTERUS	BREASTS	DISORDERS
⊕	⊖	Hypergonadotropic hypogonadism (eg, Turner syndrome, genetic mosaicism, pure gonadal dysgenesis) Hypogonadotropic hypogonadism (eg, CNS lesions, Kallmann syndrome)
⊖	⊕	Uterovaginal agenesis in genotypic female or androgen insensitivity in genotypic male
⊖	⊖	Male genotype with insufficient production of testosterone

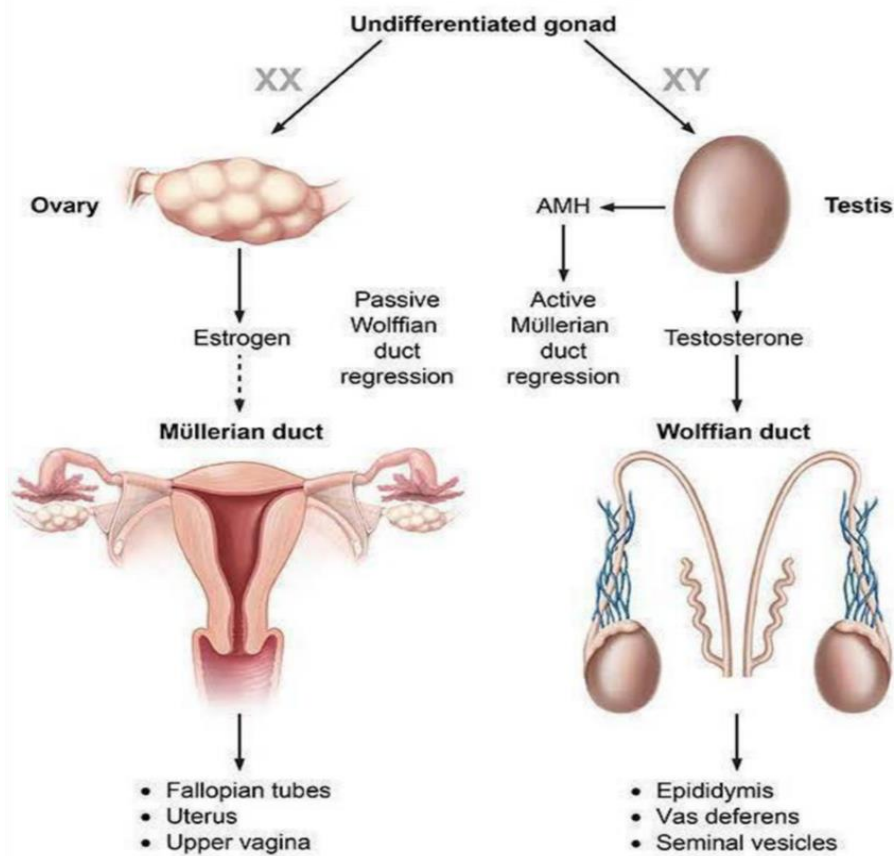
### Androgen insensitivity syndrome (46, XY)

- In these genetically **male (46, XY)** individuals with **complete lack of androgen receptor function**, their bodies do not respond to the high levels of androgens present.
- **Without androgen stimulation, internal Wolffian duct structures atrophy.** With testicular Mullerian inhibitory factor present, **the Mullerian duct derivatives involute.**
- Without body recognition of dihydrotestosterone, external genitalia differentiate in a female direction. **Patients function psychologically and physically as females and are brought up as girls.**
- **At puberty**, when primary amenorrhea is noted, **the diagnosis is made.**
- **Female secondary sexual characteristics are present** because the testes do secrete estrogens without competition from androgens.
- **Testosterone levels are normal male.** However, the functionally normal gonads are **cryptorchid as testicular descent is an androgen-dependent process.** The testes may be found in the abdomen, inguinal canal, or labia majora.
- ↑ testosterone, estrogen (due to conversion of excess testosterone via aromatase), LH (Loss of negative feedback).
- Management: **testes removal at age 20 because the higher temperatures associated with the intraabdominal position of the testes may lead to testicular cancer.** Estrogen replacement is then needed.
- Why 20? - In general, **the benefits from undergoing gonad-stimulated puberty (attainment of adult height) outweigh the low risk of malignancy.** Therefore, a gonadectomy can be deferred until completion of puberty.

### Androgen insensitivity syndrome



### Genital development

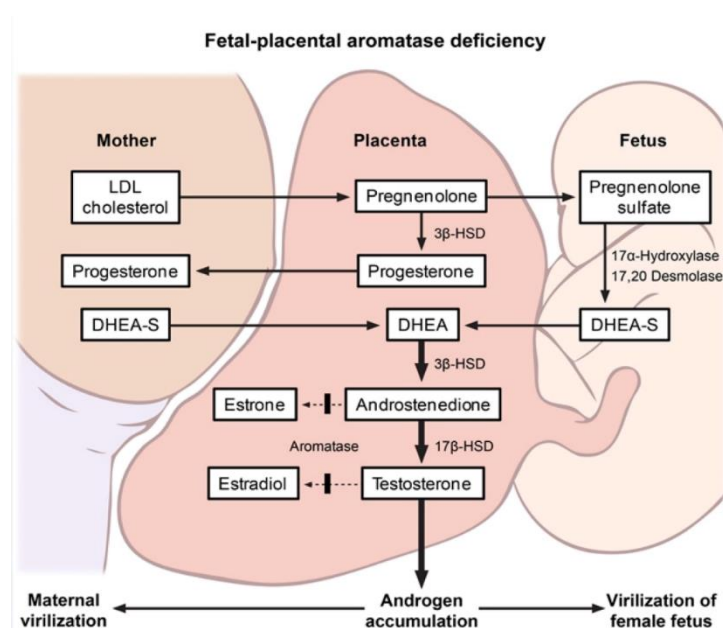


### 5 $\alpha$ -reductase deficiency

- 5 $\alpha$ -reductase converts testosterone into dihydrotestosterone (DHT).
- Deficiency of 5 $\alpha$ -reductase results in diminished conversion of testosterone to DHT in the tissues.
- In the male fetus with this genetic defect, the internal genitalia develop normally under the influence of testosterone, but the external genitalia do not develop properly due to the lack of DHT resulting in male pseudohermaphroditism.
- The genitalia at birth can range from a small phallus with hypospadias to ambiguous or female-type at birth.
- Until they reach puberty when high levels of testosterone results in masculinization evidenced by male-pattern muscle mass, voice deepening, penile and scrotal growth, and testicular descent.
- Testosterone/estrogen levels are normal; LH is normal or  $\uparrow$ .

### Placental aromatase deficiency

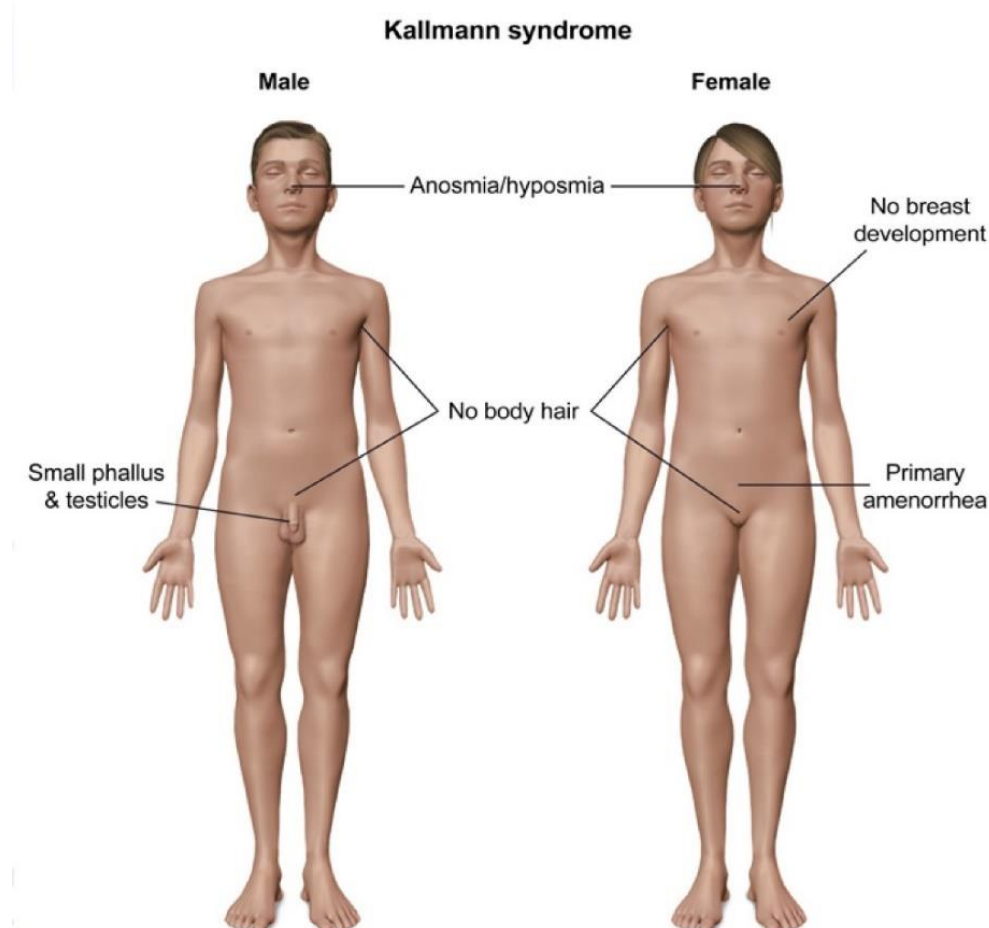
- Inability to synthesize estrogens from androgens.
- Aromatase is an enzyme that converts androstenedione to estrone and testosterone to estradiol.
- Aromatase deficiency manifests early in embryonal life with high androgen levels and low estrogen levels in the female fetus.
- Masculinization of female (46, XX) infants (ambiguous genitalia).



- This hormonal imbalance can affect the mother causing virilization during pregnancy due to the transfer of excess androgens into the maternal circulation via the placenta.
- At birth, affected female infants have ambiguous or male-type external genitalia (female pseudohermaphrodisim).

### Kallmann syndrome

- Kallmann syndrome is a disorder of migration of fetal gonadotropin-releasing hormone (GnRH) and olfactory neurons, resulting in hypogonadotropic hypogonadism and rhinencephalon hypoplasia.
- Patients with Kallmann syndrome present with delayed/absent puberty and anosmia. The karyotype will be consistent with their male or female phenotype.
- Affected boys and girls have normal genotype and internal reproductive organs. However, the congenital absence of GnRH secretion results in short stature and delayed or absent puberty.
- Girls may have primary amenorrhea and absent breast development. Adolescent boys have a eunuchoid appearance with small external genitalia and absent secondary sexual characteristics (pubic/axillary hair, voice deepening, libido).
- The most distinguishing clinical feature from other causes of hypogonadism is anosmia/hyposmia (decreased sense of smell).



- Typical laboratory findings include low follicle-stimulating hormone and luteinizing hormone levels.
- Infertility (low sperm count in males; amenorrhea in females).
- Early diagnosis is important as hormonal treatment can help facilitate development of secondary sex characteristics, build and maintain bone and muscle mass, and improve fertility.



## Gynecologic tumor epidemiology

- **Incidence (US):**
  - **Endometrial > ovarian > cervical**; cervical cancer is more common worldwide due to lack of screening or HPV vaccination.
- **Prognosis:**
  - **Cervical (best prognosis, diagnosed < 45 years old) > Endometrial (middle-aged, about 55 years old) > Ovarian (worst prognosis, > 65 years).**
- **CEOs** often go from **best** to **worst** as they get **older**.

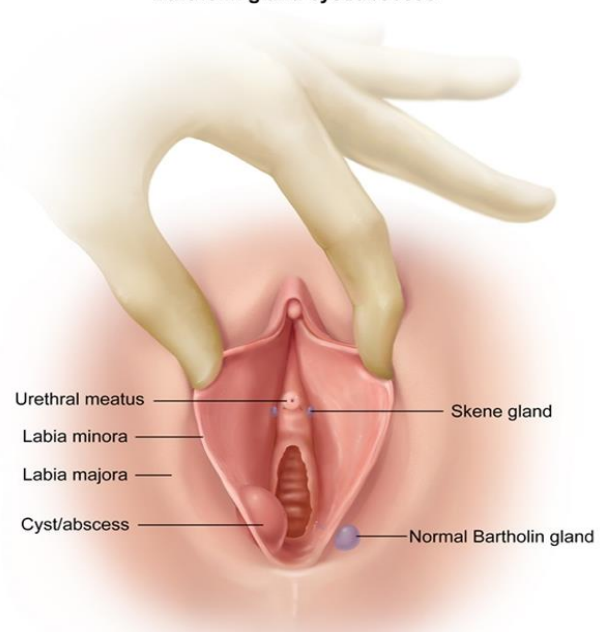
## Vulvar pathology

- Anatomically includes **the skin and mucosa of the female genitalia external to the hymen** (labia majora, labia minora, mons pubis, and vestibule).
- Lined by **squamous epithelium**.

## Non-neoplastic

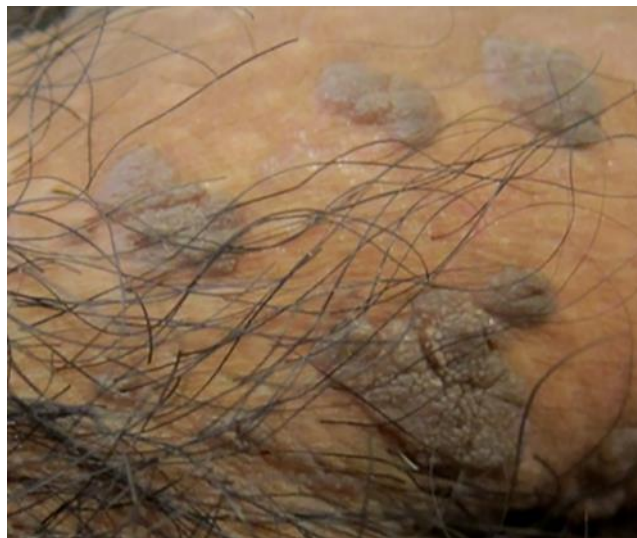1. **Bartholin cyst and abscess:**
  - Cystic dilation of the Bartholin gland.
  - Usually occurs in **women of reproductive age**.
  - One Bartholin gland is present on each side of the vaginal canal and produces mucus-like fluid that drains via ducts into the lower vestibule.
  - These pea-sized glands **provide lubrication to the vestibule and are not palpable unless ductal blockage occurs resulting in fluid buildup and cyst formation**.
  - Small cysts may be diagnosed incidentally on routine examination, or a partner may discover it during sexual activity. Larger cysts may cause discomfort during sexual activity, walking, sitting, or exercise.
  - **An abscess of the Bartholin gland may occur due to infection** (mostly caused by *E. coli* and anaerobic *Bacteroides* species).

Bartholin gland cyst/abscess



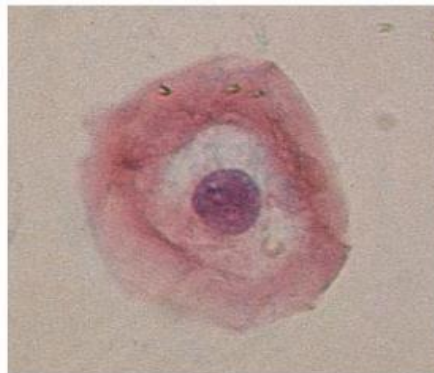## 2. Condyloma:

- Warty neoplasm of vulvar skin, often large.
- Most commonly due to HPV types 6 or 11 (condyloma acuminatum); secondary syphilis (condyloma latum due to infection with treponema pallidum) is a less common cause.
- Both are sexually transmitted.
- Histologically, HPV-associated condylomas are characterized by koilocytes (hallmark of HPV-infected cells).
- Condylomas rarely progress to carcinoma (6 and 11 are low-risk HPV types).



### ❖ N.B:

- Koilocytosis is a hallmark of HPV infection.
- The slide below shows a typical koilocyte, which is a sign of infection with human papilloma virus (HPV).
- Koilocytes are pyknotic superficial or immature squamous cells with a dense, irregularly staining cytoplasm and perinuclear clearing.

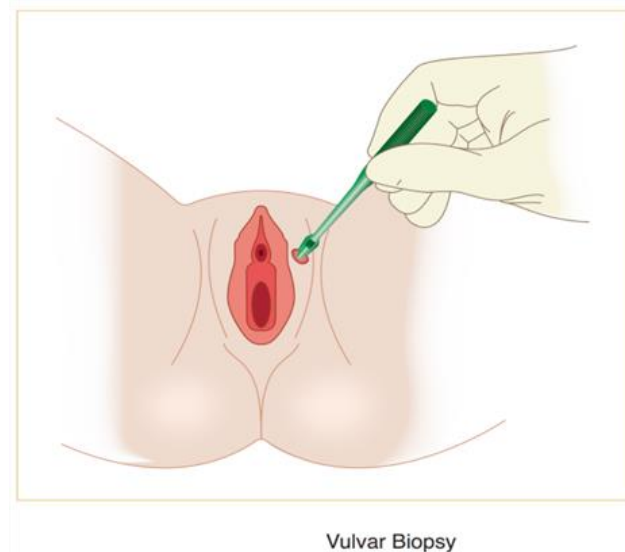
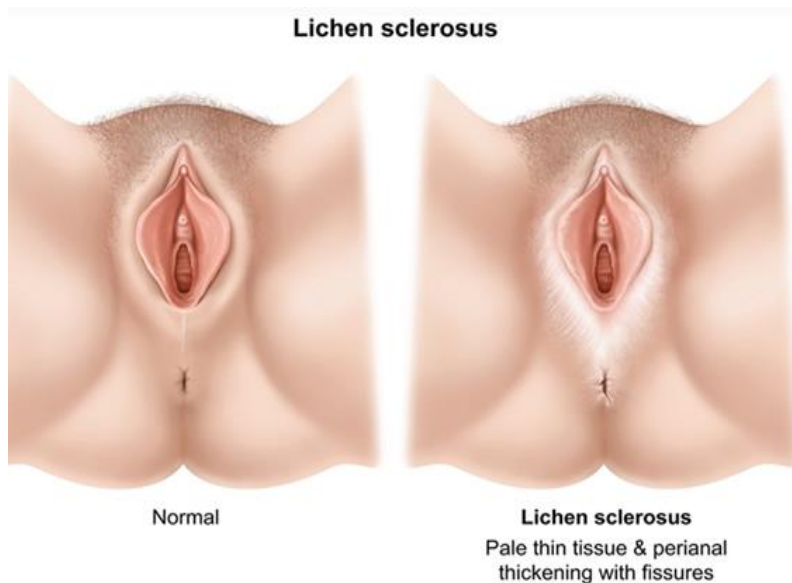


- HPV infection causes cutaneous and genital warts as well as benign and malignant epithelial neoplasia.
- The human papilloma virus has a predilection for squamous epithelia such as the skin and vaginal/ectocervical mucosa.

- Infection with HPV may be asymptomatic, or may present as:
  - Skin warts (verruca vulgaris) - caused by HPV strains 1-4.
  - Genital warts (condylomata acuminatum) - commonly associated with strains 6 and 11.
  - Intraepithelial neoplasia of the cervix (CIN) and vulva - caused by strains 16, 18, 31, 33, 35 and others. HPV-associated oncogenesis is attributed to viral proteins E6 and E7.

### 3. Lichen sclerosis:

- The most common symptom of both benign as well as malignant lesions is **vulvar itching resulting in scratching**.
- Most commonly seen in **postmenopausal women**; possible autoimmune etiology.
- Characterized by **thinning of the epidermis and fibrosis (sclerosis) of the dermis**.
- Presents as a white patch (**leukoplakia**) with **porcelain-white plaques with a red or violet border**.
- Benign, but **associated with a slightly increased risk for squamous cell carcinoma**.
- Punch biopsy confirms the diagnosis and rules out vulvar squamous cell carcinoma. Histologically, they show **epithelial thinning**.

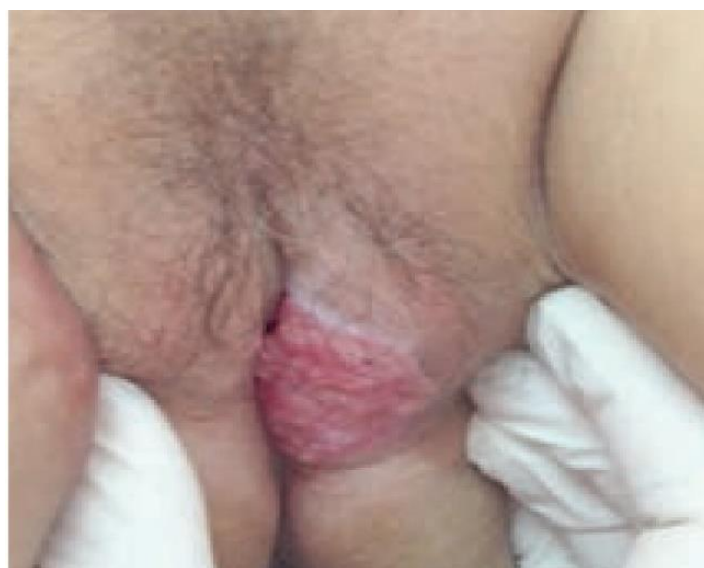

### 4. Lichen simplex chronicus:

- Associated with **chronic irritation and scratching**.
- Characterized by **hyperplasia of the vulvar squamous epithelium**.
- Presents as **leukoplakia** with **thick, leathery vulvar skin**.
- Benign; **no increased risk of squamous cell carcinoma**.

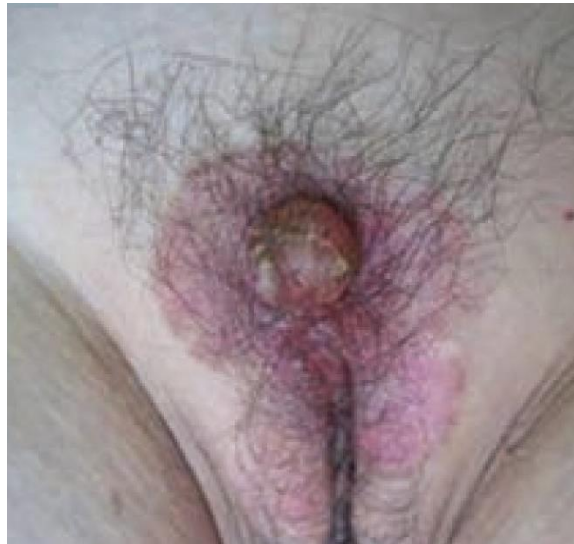**Neoplastic****1. Vulvar carcinoma:**

- Carcinoma arising from **squamous epithelium lining the vulva (> 90%)**.
  - Relatively rare, accounting for only a **small percentage of female genital cancers**.
  - Presents as **leukoplakia**; punch biopsy is required to distinguish carcinoma from other causes of leukoplakia.
  - Etiology may be HPV related or non-HPV related:
- A. **HPV-related vulvar carcinoma:**
- HPV-related vulvar carcinoma is due to high-risk HPV types **16 and 18**.
  - Risk factors are related to HPV exposure and include **multiple partners** and **early first age of intercourse**.
  - Generally, occurs in **women of reproductive age**.
  - Arises from vulvar intraepithelial neoplasia (VIN), a dysplastic precursor lesion characterized **by koilocytic change**, disordered cellular maturation, nuclear atypia, and increased mitotic activity
- B. **Non-HPV vulvar carcinoma:**
- Non-HPV related vulvar carcinoma arises, most often, from **long-standing lichen sclerosis**.
  - **Chronic inflammation and irritation** eventually lead to carcinoma.
  - Generally seen in elderly women (**average age is > 70 years**)



## 2. Extramammary Paget disease:

- **Intraepithelial** adenocarcinoma.
- A rare, slow growing, **usually noninvasive intraepithelial** (in the skin) adenocarcinoma outside the mammary gland and includes Paget's disease of the vulva and the extremely rare Paget's disease of the penis.
- **Carcinoma in situ, low risk of underlying carcinoma** (vs Paget disease of the breast, which is always associated with underlying carcinoma).
- Presents as **erythematous, pruritic, ulcerated vulvar skin**.
- Must be distinguished from **melanoma**, which rarely can occur on the vulva:
  - Paget cells are **PAS+**, **keratin+**, and **S100-**.
  - Melanoma is **PAS-**, **keratin-**, and **S100+**.



### Vagina

- Canal leading to the cervix.
- Mucosa is lined by **non-keratinizing squamous epithelium**.
- Upper 1/3 vagina → from Mullerian duct → columnar epithelium.
- Lower 2/3 vagina → from urogenital sinus → squamous epithelium.
- During development, squamous epithelium from the lower 2/3 of the vagina grows upward to replace the columnar epithelium lining of the upper 1/3 of the vagina → **all vaginal mucosa are squamous epithelium**.

### Vaginal Adenosis

- Focal persistence of columnar epithelium in the upper 1/3 of the vagina
- During development, squamous epithelium from the lower 2/3 of the vagina (derived from the urogenital sinus) grows upward to replace the columnar epithelium lining of the upper 1/3 of the vagina (derived from the Mullerian ducts).
- **Increased incidence in females who were exposed to diethylstilbestrol (DES) in utero** a drug used in high risk pregnancies (not used anymore).

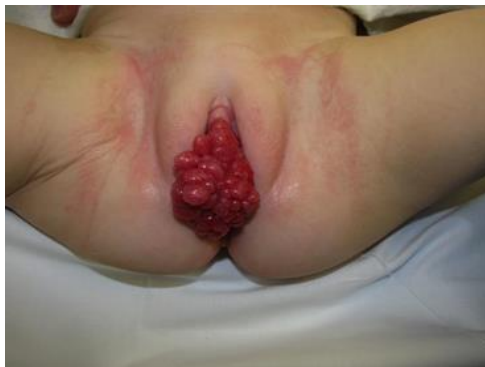### Clear cell adenocarcinoma

- Vaginal adenosis → clear cell adenocarcinoma.
  - Rare, but feared, **complication of DES-associated vaginal adenosis**.
  - Malignant proliferation of glands with clear cytoplasm.
- ❖ N.B:
- Diethylstilbestrol (DES) is a synthetic estrogen that was widely used from 1938-1971 for **prevention of spontaneous abortion, premature delivery, and postpartum lactation suppression**.
  - DES was subsequently banned in the United States **due to its lack of efficacy and its potential for carcinogenic and teratogenic effects in offspring**.
  - **Daughters of women who used DES during their pregnancy are at a 40-fold increased risk of developing clear cell adenocarcinoma (CCA) of the vagina and cervix.**
  - Many of these women have **cervical or uterine malformations** as well as difficulty conceiving and **maintaining pregnancy**.
  - Males exposed in utero are **at risk of cryptorchidism, microphallus, hypospadias, and testicular hypoplasia**.



### Sarcoma botryoides (Embryonal rhabdomyosarcoma)

- Embryonal rhabdomyosarcoma variant.
- Malignant mesenchymal proliferation of immature skeletal muscle; rare.
- Presents as **bleeding and a grape-like mass protruding from the vagina** or penis of a child (usually < 4 yrs. of age).
- Exhibits cytoplasmic **cross-striations** and positive immunohistochemical staining for **desmin and myogenin**.



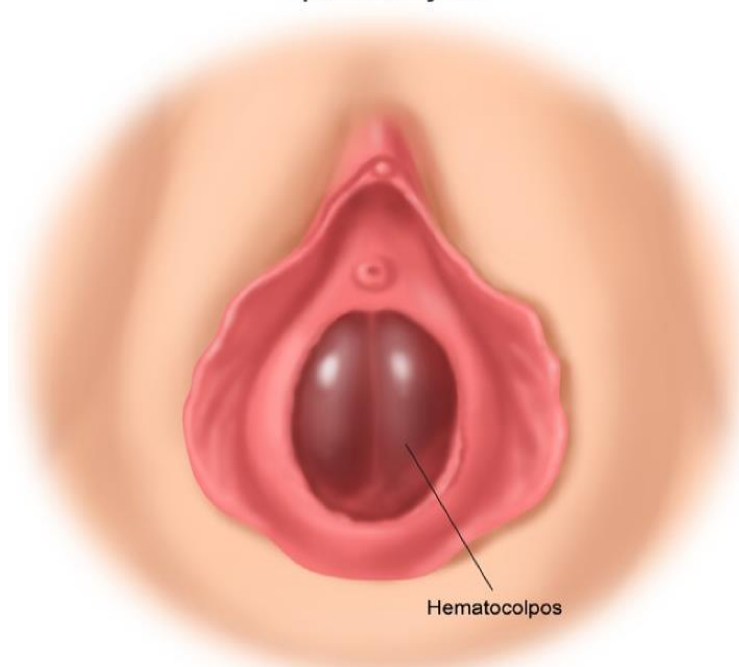
### Vaginal squamous cell carcinoma

- Carcinoma arising from squamous epithelium lining the vaginal mucosa.
- **Metastatic disease to the vagina is more common than primary disease.**
- Usually **2° to cervical SCC. 1° vaginal carcinoma is rare.**
- The risk factors for primary SCC of the vagina are very similar to those for cervical cancer, most significantly **smoking and human papillomavirus (HPV) infection**.
- The most common symptoms of vaginal cancer are **postcoital vaginal bleeding and malodorous vaginal discharge**.
- **The definitive diagnosis is made by biopsy of the lesion**, and treatment is determined after staging.
- When spread to regional lymph nodes occurs, cancer from the **lower 2/3** of vagina goes to **inguinal nodes**, and cancer from the **upper 1/3** goes to regional **iliac nodes** (different lymphatic drainage due to different embryonic origin).

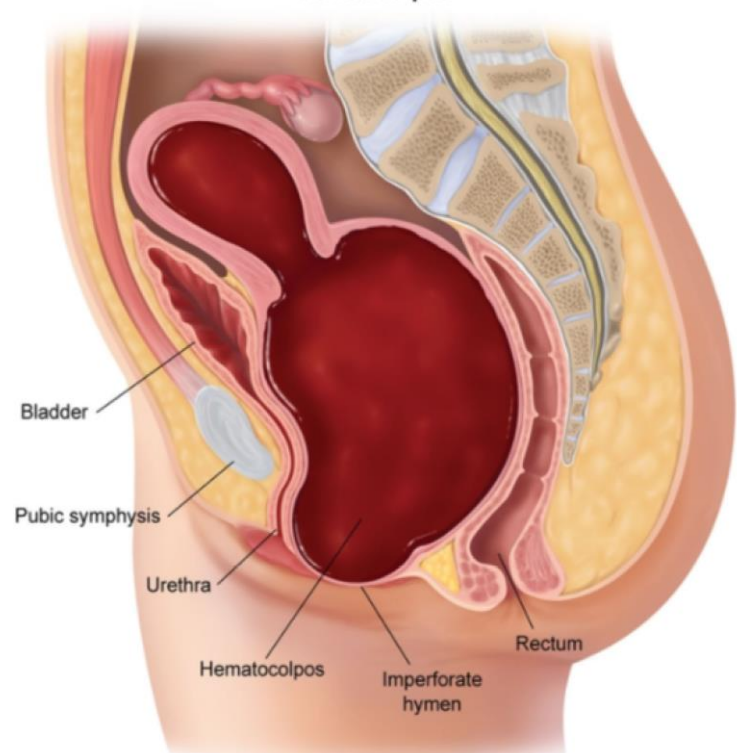
## Imperforate hymen

- Imperforate hymen is a **common anatomic cause of primary amenorrhea**.
- This occurs **when the hymen fails to fenestrate during embryonic development**.
- **Infants** may present with a **bulging membrane due to mucus collection**, but this typically resolves, and patients **remain asymptomatic until menarche**.
- When menstruation occurs, **blood collects in the vagina behind the hymenal membrane (hematocolpos)**.
- The enlarging blood collection with each menstrual period causes **increasing pressure on the surrounding pelvic organs, resulting in lower back pain, pelvic pressure, or defecatory rectal pain**.
- Pelvic examination typically reveals a **blue, bulging vaginal mass or membrane that swells with increased intraabdominal pressure (Valsalva)**.
- **Treatment is with incision of the hymen and drainage of the hematocolpos.**

Imperforate hymen

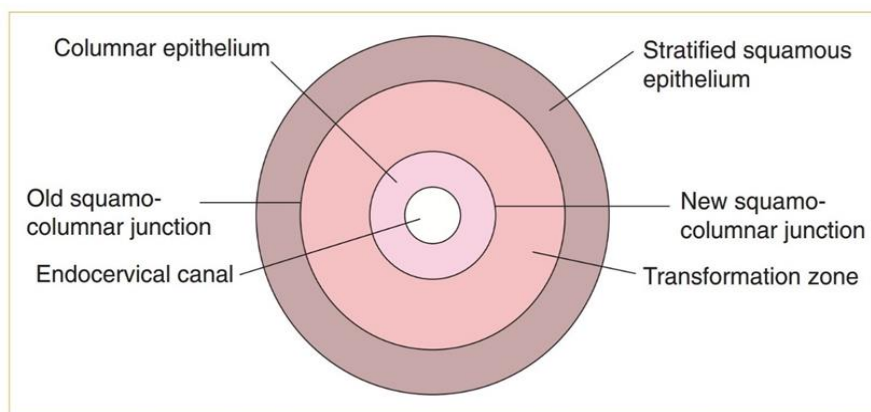


Hematocolpos



## Cervix

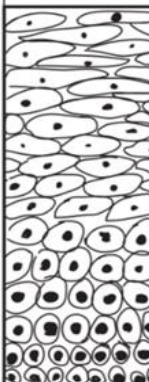





- Anatomically, comprises the "neck" of the uterus.
- Divided into the **ectocervix** (visible on vaginal exam) and **endocervix**.
- **Ectocervix** is lined by **nonkeratinizing squamous epithelium**.
- **Endocervix** is lined by a **single layer of columnar cells**.
- Junction between the ectocervix and endocervix is called the **transformation zone (squamocolumnar junction)**.
- HPV infects the lower genital tract, especially the cervix in the **transformation zone**.
- **Persistent** infection leads to an **increased risk for cervical dysplasia** (cervical intraepithelial neoplasia, CIN).
- Risk of CIN depends on HPV type. High-risk-HPV types **16, 18, 31, and 33**.
- High-risk HPV produce **E6** and **E7** proteins which result in increased destruction of **p53** and **Rb**, respectively.
- Loss of these tumor suppressor proteins **increases the risk for CIN**.
- Having **multiple sexual partners** has been shown to correlate with a higher risk of infection with high-risk HPV strains and a higher risk of development of invasive cervical lesions. Other risk factors include lower socioeconomic status, **cigarette smoking**, **early age at first intercourse**, oral contraceptive use, and **immunosuppression** (such as HIV).
- Consistent use of barrier contraceptives is extremely important for preventing sexually transmitted infections, including human papillomavirus (HPV).



Development of T-Zone

### Cervical intraepithelial neoplasia

- Characterized by **koilocytic** change, disordered cellular maturation, nuclear atypia, and increased mitotic activity within the cervical epithelium.
- Divided into grades based on the extent of epithelial involvement by immature dysplastic cells:
  - CIN I involves < 1/3 of the thickness of the epithelium.
  - CIN II involves < 2/3 of the thickness of the epithelium.
  - CIN III involves slightly less than the entire thickness of the epithelium.
  - Carcinoma in situ (CIS) involves the entire thickness of the epithelium.
- CIN classically **progresses** in a stepwise fashion through CIN I, CIN II, CIN III, and CIS to **become invasive squamous cell carcinoma**.
- Progression is not inevitable (CIN I often regresses).
- Although high-grade dysplasia (involving most or the entire epithelial layer) often progresses to invasive cancer, **low-grade dysplasia (involving a small portion of epithelium) typically spontaneously regresses**.

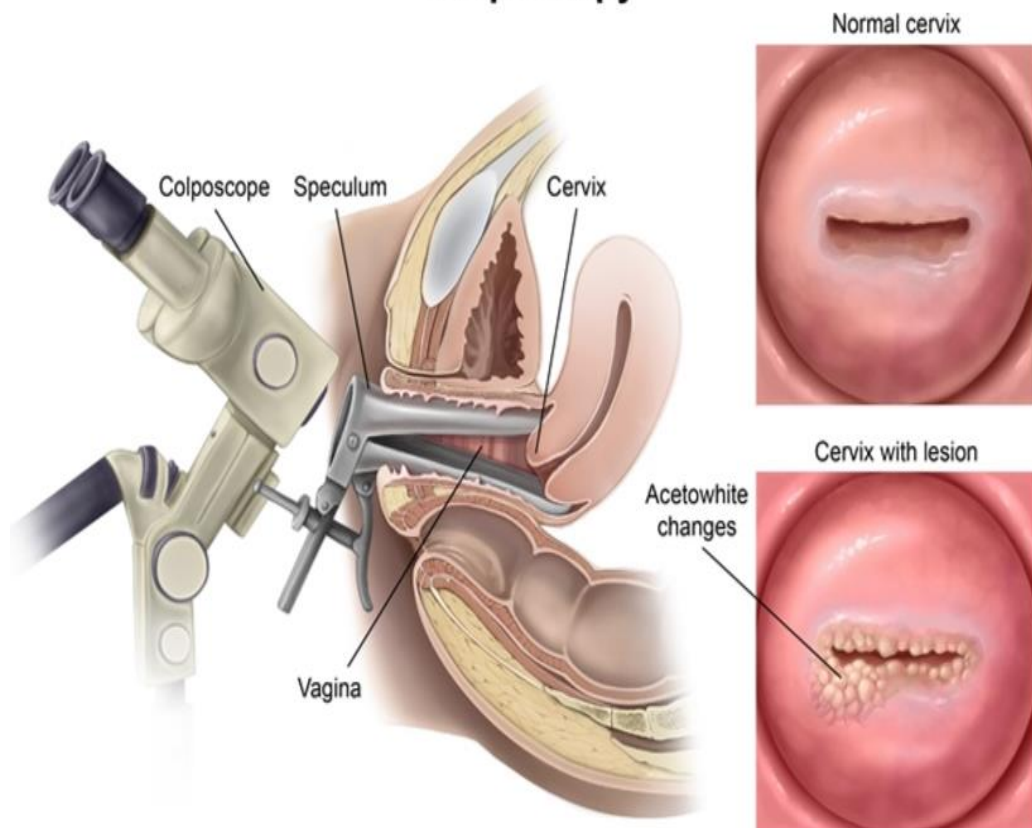
Histology	CIN 1		CIN 2	CIN 3		
	Normal	Very mild dysplasia	Mild dysplasia	Moderate dysplasia	Severe dysplasia	Cancer in situ
						
Cytology		Low-Grade SIL		High-Grade SIL		

Histologic Appearance of Cervical Dysplasia with Progressive Severity

## Cervical carcinoma

- Invasive carcinoma that arises from the cervical epithelium.
- Most commonly seen in **middle-aged women** (average age is 40-50 years)
- Presents as vaginal bleeding, especially postcoital bleeding, or cervical discharge.
- Most common subtypes of cervical carcinoma are **squamous cell carcinoma** (80% of cases) and **adenocarcinoma** (15% of cases).
- **Advanced tumors often invade through the anterior uterine wall into the bladder, blocking the ureters. Hydronephrosis with postrenal failure is a common cause of death in advanced cervical carcinoma.**
- Screening and prevention of cervical carcinoma:
  - The goal of screening is to **catch dysplasia (CIN) before it develops into carcinoma.**
  - Progression from CIN to carcinoma, on average, takes 10-20 years.
  - **Pap smear** is the gold standard for screening. Screening begins at age 21.
  - Cells are scraped **from the transformation zone** using a brush and analyzed under a microscope.
  - Dysplastic cells are classified as **low grade (CIN I)** or **high grade (CIN II and III)**.
  - High-grade dysplasia is characterized by cells with hyperchromatic (dark) nuclei and high nuclear to cytoplasmic ratios.
  - Pap smear is the most successful screening test developed to date. It is responsible for a **significant reduction in the morbidity and mortality of cervical carcinoma** (cervical carcinoma went from being the most common to one of the least common types of gynecologic carcinoma in the US).
  - An abnormal Pap smear is **followed by confirmatory colposcopy** (visualization of cervix with a magnifying glass) **and biopsy.**
  - Limitations of the Pap smear **include inadequate sampling of the transformation zone** (false negative screening) and **limited efficacy in screening for adenocarcinoma.**
  - Despite Pap smear screening, the incidence of adenocarcinoma has not decreased significantly.

## Colposcopy



- Prevention of Cervical Dysplasia by Vaccination:
  - Immunization is effective in preventing HPV infections.
  - The quadrivalent vaccine covers HPV types 6, 11, 16, and 18.
  - Antibodies generated against types 6 and 11 protect against condylomas.
  - Antibodies generated against types 16 and 18 protect against CIN and carcinoma.
  - Protection lasts for 5 years.
  - Pap smears are still necessary **due to the limited number of HPV types covered by the vaccine.**



## Uterus

- Endometrium is **the mucosal lining of the uterine cavity**.
- Myometrium is **the smooth muscle wall underlying the endometrium**.
- Endometrium is hormonally sensitive:
  - Growth of the endometrium is **estrogen driven** (proliferative phase).
  - Preparation of the endometrium for implantation is **progesterone driven** (secretory phase).
  - Shedding occurs with **loss of progesterone support** (menstrual phase).

## Acute endometritis

- Bacterial infection of the endometrium (Group B strep).
- Usually due to **retained products of conception** (after delivery or miscarriage); retained products **act as a nidus for infection**.
- Presents as **fever, abnormal uterine bleeding, and pelvic pain**.

## Chronic endometritis

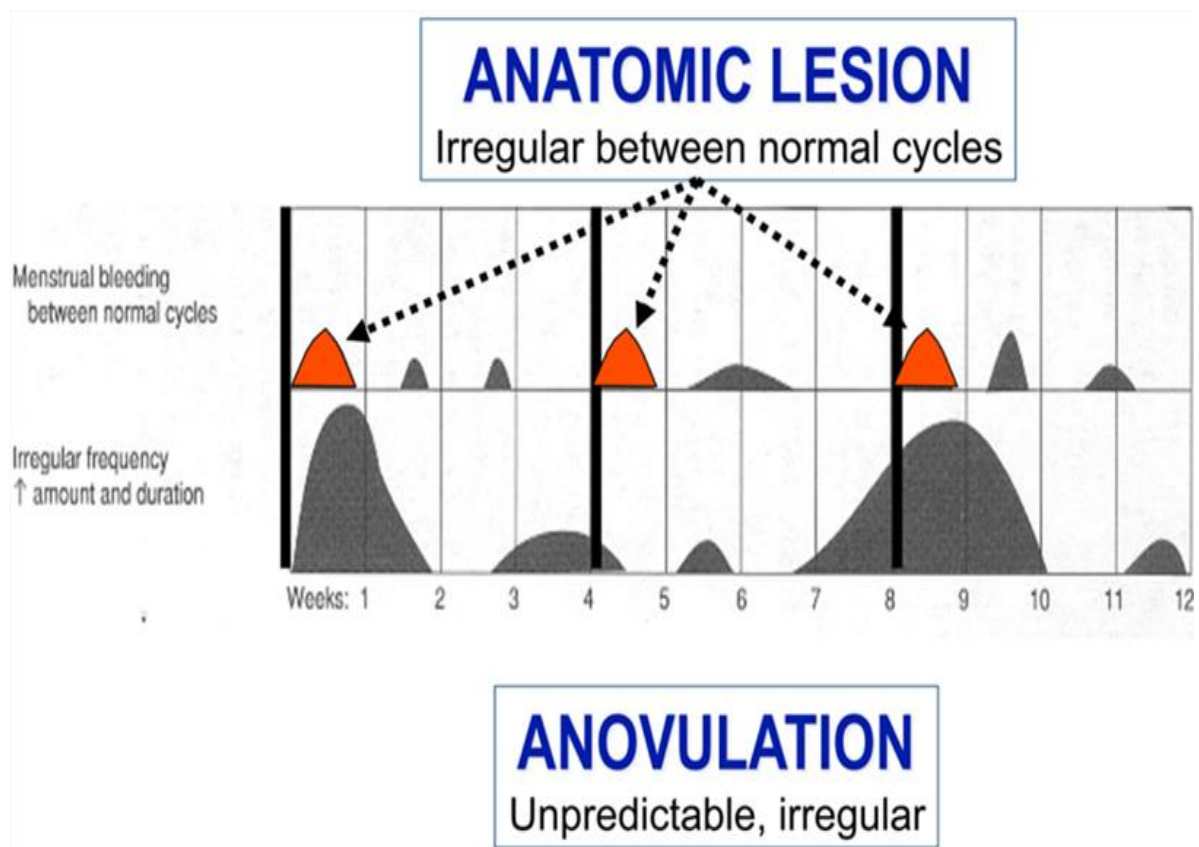
- Chronic inflammation of the endometrium.
- Characterized **plasma cells**. Plasma cells are necessary for the diagnosis of chronic endometritis given that **lymphocytes are normally found in the endometrium**.
- Causes include retained products of conception, chronic pelvic inflammatory disease (Chlamydia), IUD (Actinomyces israelii), and TB.
- Presents as **abnormal uterine bleeding, pain, and infertility**.

## Asherman syndrome

- Endometrium is composed of two layers, **the functional layer** (adjacent to the uterine cavity) which is shed during menstruation and an **underlying basal layer** (adjacent to the myometrium), which is necessary for regenerating the functional layer.
- Asherman syndrome is a **secondary amenorrhea** due to loss of the basal layer and scarring.
- Result of **overaggressive dilation and curettage** (D&C) performed after a miscarriage, or delivery, or for surgical termination of pregnancy.

### Abnormal uterine bleeding

- Characterized as either heavy menstrual bleeding (**AUB/HMB**) or intermenstrual bleeding (**AUB/IMB**).
- These are further subcategorized by **PALMCOEIN**:
  - A. **Structural causes (PALM)**:
    - Polyp, Adenomyosis, Leiomyoma, or Malignancy/hyperplasia
  - B. **Non-structural causes (COEIN)**:
    - Coagulopathy, Ovulatory, Endometrial, Iatrogenic, Not yet classified
- Terms such as dysfunctional uterine bleeding, menorrhagia, oligomenorrhea are no longer recommended.



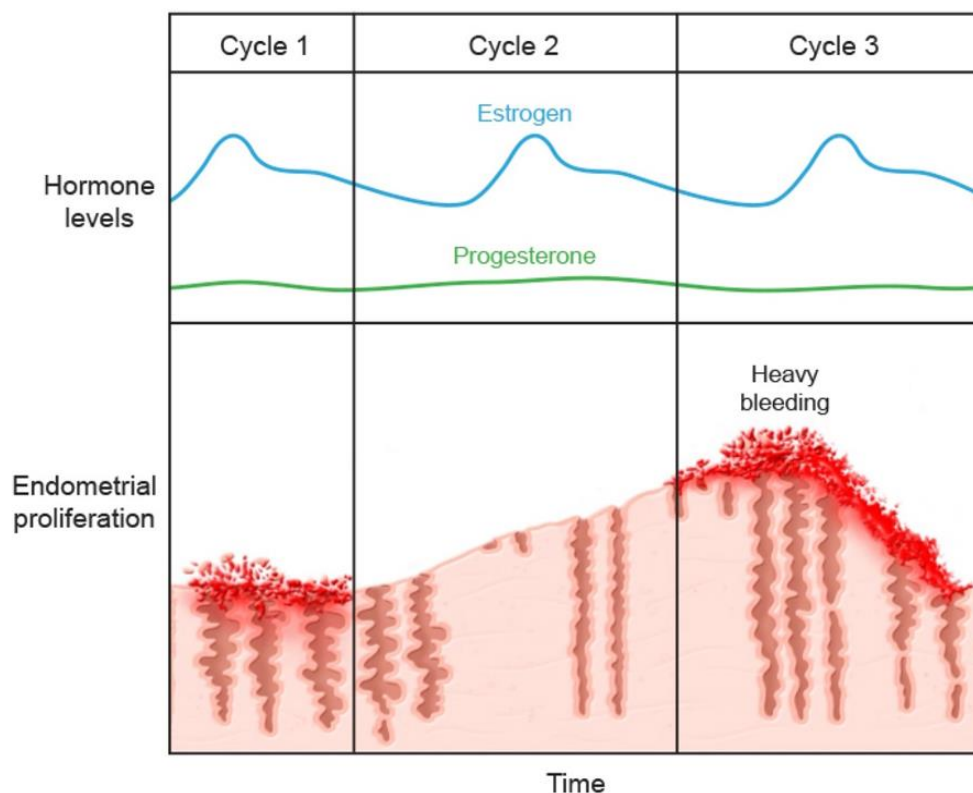
## Anovulatory cycle

- **Lack of ovulation.**
- Anovulation is **common in the first several years after menarche and the last few years before menopause.**
- It manifests with **marked menstrual cycle variability.**
- However, adolescents typically have an **immature hypothalamic-pituitary-ovarian axis for several years following menarche.** During this time, they may have longer menstrual cycles and irregular bleeding patterns due to the presence of anovulatory cycles.
- In the absence of ovulation, the ovarian follicle does not degenerate and become a corpus luteum.
- As a result, **no progesterone is produced and estrogen levels remain persistently high, causing the endometrium to remain in the proliferative phase.**
- **Chronically proliferative endometrium becomes disorganized and fragile with unstable venous capillaries,** resulting in irregular periods of stromal breakdown with variable, but often heavy, bleeding.
- By young adulthood, ovulation occurs regularly and menstrual cycles become more predictable.
- However, as women approach menopause in their late 40s, anovulation becomes more prevalent and menstrual irregularity ensues **due to decrease in the number and quality of the ovarian follicles.**
- **Most common causes of anovulation:**
  - Pregnancy.
  - Polycystic ovarian syndrome.
  - Obesity.
  - HPO axis abnormalities/immaturity.
  - Premature ovarian failure.
  - Hyperprolactinemia, thyroid disorders.
  - Eating disorders, competitive athletics.
  - Cushing syndrome, Adrenal insufficiency.
  - Chromosomal abnormalities (Turner syndrome).
- **Progesterone Challenge Test (PCT):**
  - **Administer either a single IM dose of progesterone or 7 days of oral medroxyprogesterone acetate (MPA):**
    - Any degree of withdrawal bleeding is diagnostic of **anovulation.**
    - Cyclic MPA is required to prevent endometrial hyperplasia.
    - Clomiphene ovulation induction will be required if pregnancy is desired.

## ❖ N.B:

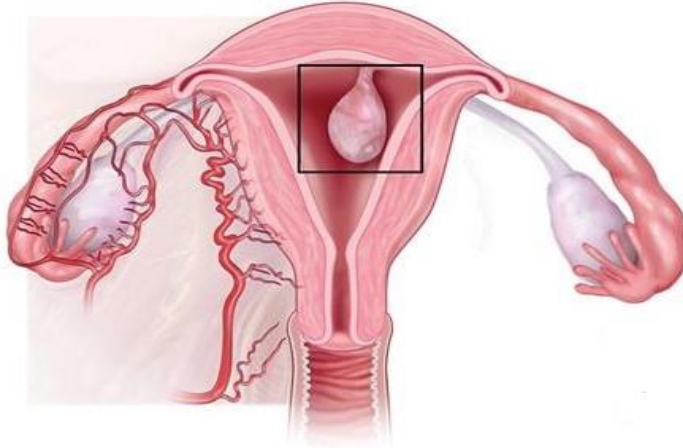
- Anovulation is a common cause of infertility.
- One way to treat anovulation is the administration of drugs that act like FSH and LH.
- Treatment with menotropin (human menopausal gonadotrophin) acts like FSH and leads to the formation of a dominant ovarian follicle.
- Ovulation is then induced by administration of a large dose of hCG, which simulates the LH surge.

### Effect of anovulatory cycles on the endometrium



### Endometrial polyp

- Well-circumscribed collection of endometrial tissue within uterine wall.
- Can extend into endometrial cavity in the form of a polyp.
- May be asymptomatic or present with painless abnormal uterine bleeding.
- Can arise as a side effect of tamoxifen, which has anti-estrogenic effects on the breast but weak pro-estrogenic effects on the endometrium.



## Endometriosis

### ▪ Definition:

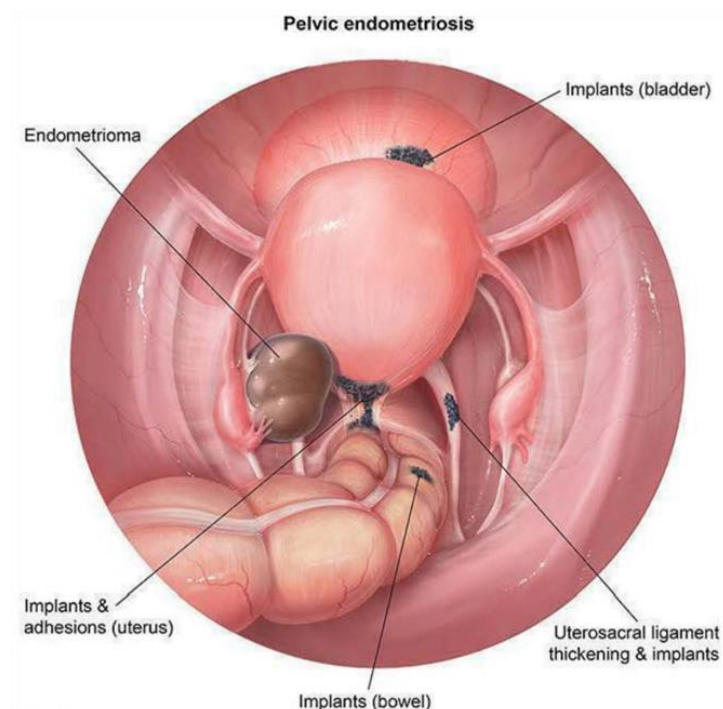
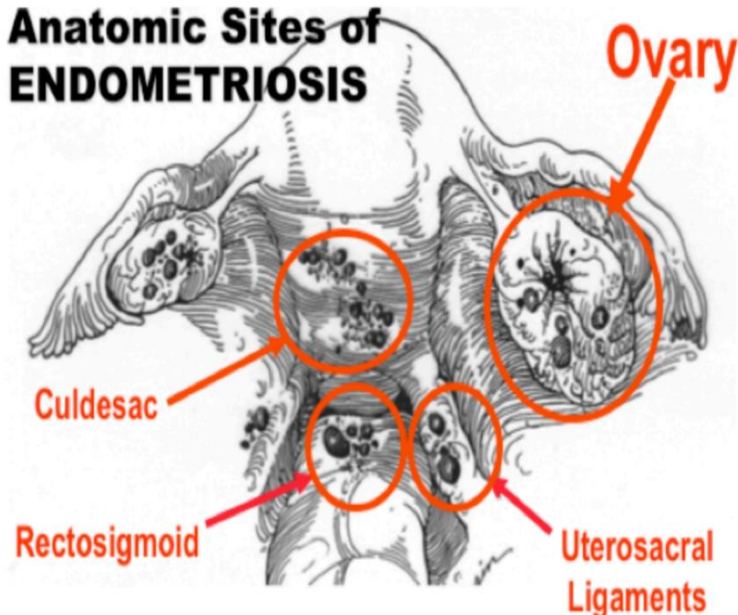
- Endometriosis is a benign condition in which endometrial glands and stroma are seen outside the uterus.

### ▪ Pathophysiology:

- Most likely due to retrograde menstruation with implantation at an ectopic site, metaplastic transformation of multipotent cells, transportation of endometrial tissue via lymphatic system.
- With time, the blood undergoes hemolysis and induces an inflammatory response around the ectopic endometrium. Local inflammation is followed by the formation of adhesions and distortion of organ structure.
- The most common site of endometriosis is the ovary (frequently bilateral), and because this is functioning endometrium, it bleeds on a monthly basis and can create adnexal enlargements known as endometriomas, also known as a chocolate cyst.
- The second most common site of endometriosis is the cul-de-sac, and in this area the endometriotic nodules grow on the uterosacral ligaments, giving the characteristic uterosacral ligament nodularity and tenderness appreciated by rectovaginal examination.
- Menstruation into the cul-de-sac creates fibrosis and adhesions of bowel to the pelvic organs and a rigid cul-de-sac, which accounts for dyspareunia.



## Anatomic Sites of ENDOMETRIOSIS



### ■ Clinical Findings:

#### A. Symptoms:

- Patients with endometriosis can have **chronic pelvic pain and/or infertility, or be completely asymptomatic** and diagnosed during an unrelated surgical procedure.
- Endometriosis is a **common cause of chronic pelvic pain (>6 months) in reproductive-age women**.
- The hallmarks of endometriosis (the "3 Ds") are **dysmenorrhea** (shedding of the ectopic tissue causes pain during the menstrual period), deep **dyspareunia** (related to retroversion of the uterus and endometrial implants on the uterosacral ligaments), and **dyschezia** (pain with defecation due to pelvic adhesions).
- **Infertility** is commonly the sole presenting symptom of endometriosis, which is present in one quarter of all patients with infertility. **Cyclic accumulation of ectopic foci of hemorrhage and adhesions can distort pelvic anatomy and impair fertility by obstructing oocyte release or sperm entry.** The presence of an **endometrioma** (ovarian endometriosis cyst) is also associated with **impaired ovarian function**.

#### B. Examination:

- Physical examination findings vary but commonly include a **fixed, retroverted and immobile uterus and rectovaginal nodularity** often caused by cul-de-sac adhesions.
- **Adnexal mass or fullness should be confirmed by ultrasonography**, and the finding of a homogeneous cystic ovarian mass is highly suggestive of an ovarian **endometrioma**. An endometrioma can be the only clinical manifestation of endometriosis.



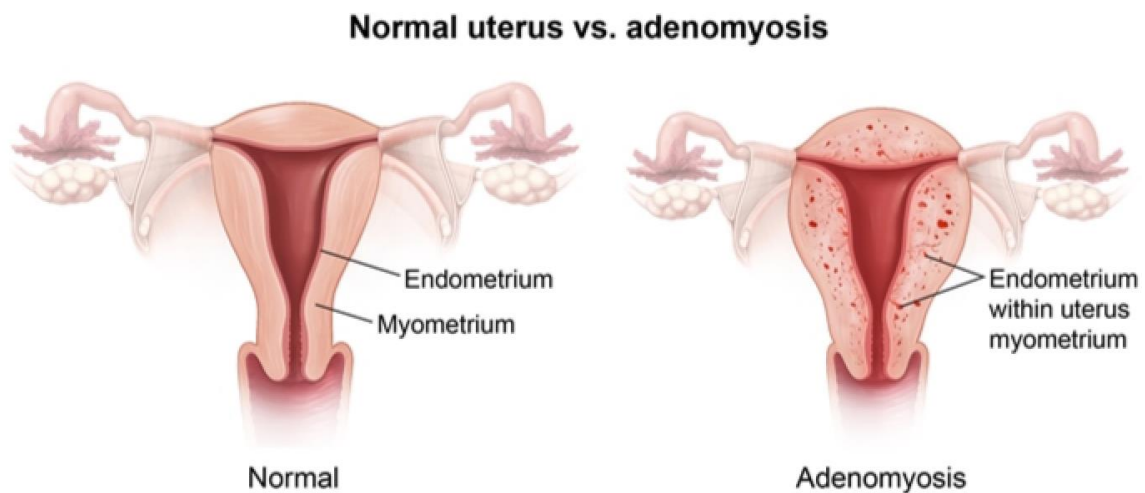
▪ Treatment:

- Asymptomatic patients do not require treatment.
- Nonsteroidal anti-inflammatory drugs (ibuprofen, naproxen) and/or combined (estrogen and progestin) oral contraceptives (COCs) are first-line empiric treatment options that are appropriate without definitive surgical diagnosis. COC therapy is thought to reduce pain by ovulation suppression, which may result in atrophy of endometrial tissue.
- GnRH analogs (leuprolide or Lupron): GnRH stimulates the pituitary in a pulsatile fashion, and GnRH analogs stimulate by continuous stimulation, which produces a condition known as down-regulation of the pituitary.
- Failure of conservative treatment, presence of an adnexal mass, and infertility necessitate laparoscopic evaluation.
- Surgical resection of endometriomas usually improves fertility.

### Adenomyosis

▪ Definition:

- Ectopic endometrial glands and stroma are located within the myometrium of the uterine wall due to hyperplasia of basal layer of endometrium.



▪ Clinical Findings:

- In most cases the diagnosis is made clinically by identifying an enlarged, symmetric, tender uterus in the absence of pregnancy.
- Tenderness is most common immediately before and during menses.

- The disruption of the arrangement of the smooth muscle fibers **interferes with normal uterine contraction and causes dysmenorrhea**.
- The continued accumulation of endometrial tissue within the myometrium **causes an increase in the endometrial cavity surface area resulting in heavy menstrual bleeding**.

Leiomyoma	Adenomyosis
Asymmetric	Symmetric
Firm	Soft
Nontender	Tender

- Treatment:
- Medical treatment includes the **GnRH analogs (leuprolide or Lupron)**.
- Surgery, in the form of hysterectomy, is the definitive treatment.

### Primary dysmenorrhea

- Primary dysmenorrhea refers to **recurrent, crampy lower abdominal pain, along with nausea, vomiting, and diarrhea, that occurs during menstruation in the absence of pelvic pathology**. It is the most common gynecologic complaint among adolescent girls.
- The symptoms typically begin several hours prior to the onset of menstruation and continue for 1 to 3 days.
- Symptoms appear to be caused by **excess production of endometrial prostaglandin** resulting from the spiral arteriolar constriction and necrosis that follow progesterone withdrawal as the corpus luteum involutes.
- The prostaglandins cause **dysrhythmic uterine contractions, hypercontractility, and increased uterine muscle tone, leading to uterine ischemia**.
- The effect of the prostaglandins on the gastrointestinal smooth muscle also can account for **nausea, vomiting, and diarrhea via stimulation of the gastrointestinal tract**.
- **Nonsteroidal anti-inflammatory drugs (prostaglandin synthetase inhibitors) are the first choice in treatment**.

## Secondary dysmenorrhea

- Secondary dysmenorrhea refers to painful menstruation **in the presence of pelvic pathology**. It is more common **among women in the fourth and fifth decades of life**.

### Secondary Dysmenorrhea: Etiology

**Endometriosis**

**Adenomyosis**

**Chronic PID**

## Leiomyoma (fibroids)

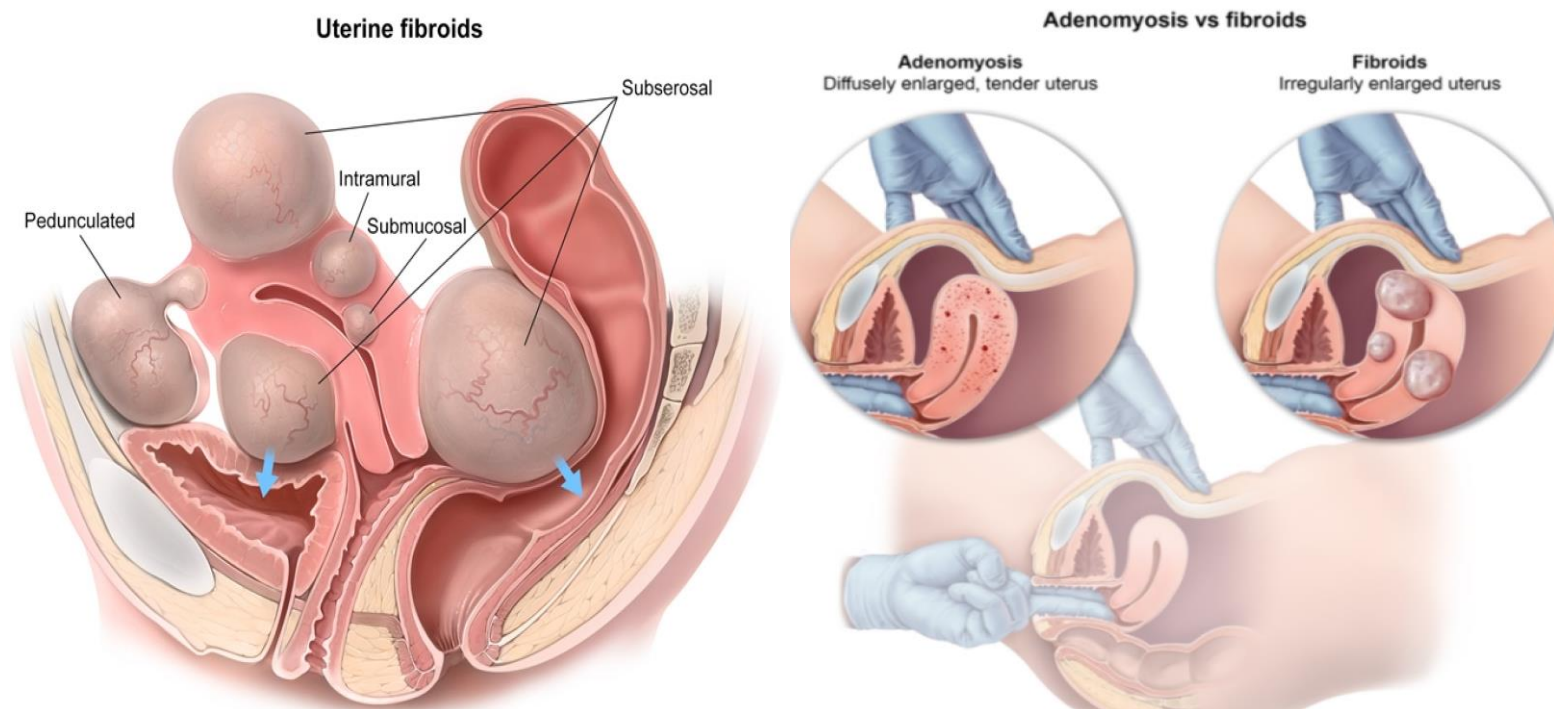
- Definition:
  - It is a **benign smooth muscle growth of the myometrium**.
  - It is **the most common benign uterine tumor**.
  - It is **5 times more common in African Americans**.
  - Malignant transformation to leiomyosarcoma is **rare**.
  - **Related to estrogen exposure**. Estrogen sensitive: tumor size ↑ with pregnancy and ↓ with menopause.
  - Common in **premenopausal women**.
  - Often **multiple**. Gross exam shows multiple, well-defined, white, whorled masses that may distort the uterus and impinge on pelvic structures.
- Location:
  - It can develop in a number of anatomic locations:
    - A. **Intramural:**
      - **The most common location of a leiomyoma is within the wall of the uterus**.
      - When **small** it is usually **asymptomatic** and cannot be felt on examination unless it **enlarges** to where the normal uterine **external contour is altered**.

**B. Submucosal:**

- These myomas are located beneath the endometrium and **can distort the uterine cavity**.
- The distorted overlying endometrium may not respond appropriately to the normal hormonal fluctuations, resulting in **unpredictable, often intermenstrual, bleeding**.
- **Abnormal vaginal bleeding is the most common symptom of a submucosal myoma and can result in anemia**.
- Most fibroids do not affect pregnancy. However, **having large or multiple fibroids can increase the risk of obstetrical complications** (miscarriage, malrepresentation, abruptio placentae, preterm birth).

**C. Subserosal:**

- These are located **beneath the uterine serosa**.
- As they grow, **they distort the external contour of the uterus causing the firm, nontender asymmetry**. Leiomyomata can cause an **irregularly enlarged uterus and size-date discrepancy during pregnancy**.
- Depending on their location they can **put pressure on the bladder, rectum, or ureters**.
- Subserosal and pedunculated uterine leiomyomata can cause **bulk-related symptoms** (pelvic pressure, back/pelvic pain, sensation of incomplete voiding, and constipation).

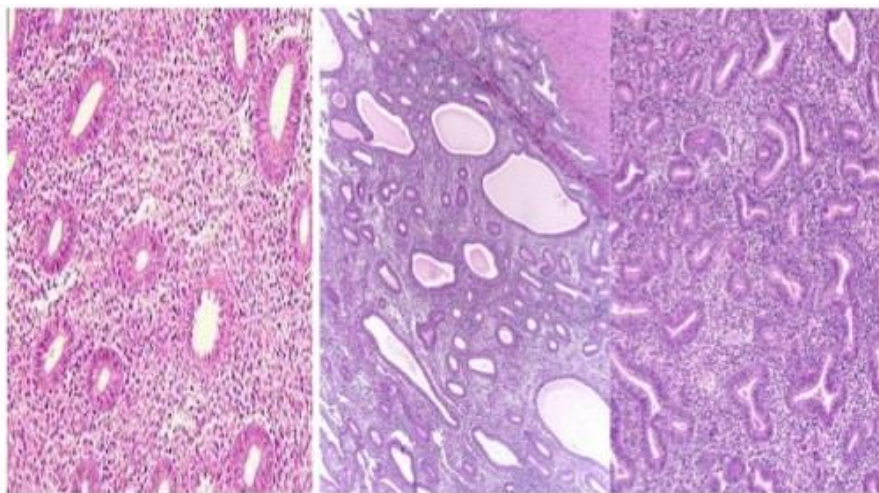


### Leiomyosarcoma

- **Malignant** proliferation of smooth muscle arising from the myometrium.
- Arises **de novo**: leiomyosarcomas do not arise from leiomyomas.
- Usually seen in **postmenopausal women**.
- Gross exam often shows a **single lesion with areas of necrosis and hemorrhage**; histological features include necrosis, mitotic activity, and cellular atypia.

### Endometrial hyperplasia

- Hyperplasia of endometrial glands relative to stroma.
- Classically presents as **postmenopausal uterine bleeding**.
- Occurs as a consequence of **unopposed estrogen**.
- Risk factors include **anovulatory cycles, hormone replacement therapy, polycystic ovarian syndrome, granulosa cell tumor**.
- Classified histologically based on **architectural growth pattern** (simple or complex) and the **presence or absence of cellular atypia**.
- Simple:
  - ↑ number of glands with **no crowding**.
- Complex:
  - ↑ number of branching glands **with crowding**.



NORMAL ENDOMETRIUM

SIMPLE HYPERPLASIA

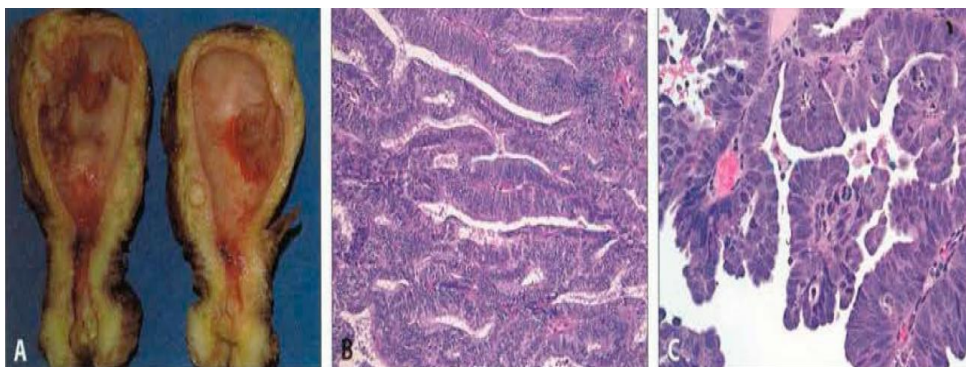
COMPLEX HYPERPLASIA



- Atypical:
  - ↑ number of **atypical** glands with crowding
  - Highest risk of progression to endometrial cancer
- Most important predictor for progression to carcinoma (major complication) is **the presence of cellular atypia**; simple hyperplasia with atypia often progresses to cancer (30%); whereas, complex hyperplasia without atypia rarely does (<5%).

### Endometrial carcinoma

- **Malignant** proliferation of endometrial glands.
- **Most common gynecologic malignancy.**
- Presents as **postmenopausal bleeding.**
- Arises via two distinct pathways (hyperplasia and sporadic):
  - A. Hyperplastic pathway (75% of cases):
    - In the hyperplasia pathway, carcinoma arises from **endometrial hyperplasia.**
    - Risk factors are related to **unopposed estrogen exposure** and include early menarche/late menopause, nulliparity, infertility with anovulatory cycles, and obesity.
    - Average age of presentation is 60 years.
    - Histology is **endometrioid** (normal endometrium-like).
  - B. Sporadic pathway (25% of cases):
    - In the sporadic pathway, carcinoma arises in an **atrophic endometrium with no evident precursor lesion.**
    - Average age at presentation is 70 years.
    - Histology is usually **serous** and is characterized by **papillary structures with psammoma body formation**; p53 mutation is common, and the tumor exhibits **aggressive behavior.**





## Ovaries

## Polycystic ovarian syndrome (PCOS)

▪ Definition:

- Polycystic ovarian syndrome (PCOS), historically called Stein-Leventhal syndrome, is a condition of **chronic anovulation with resultant infertility**.
- The patient presents typically with **irregular vaginal bleeding**. Other symptoms include **hirsutism**.
- Associated with **obesity, acanthosis nigricans** (Hyperinsulinemia and/or insulin resistance hypothesized to **alter hypothalamic hormonal feedback response**).
- Characterized by **increased LH and low FSH** (LH: FSH > 3).
- Affects roughly **5%** of women of reproductive age.

▪ Pathophysiology:A. Chronic anovulation:

- Instead of showing the characteristic hormone fluctuation of the normal menstrual cycle, PCOS gonadotropins and sex steroids are in **a steady state**, resulting in **anovulation and infertility**.
- Without ovulation, there is **no corpus luteum to produce progesterone**. Without progesterone there is **unopposed estrogen**. Endometrium, which is chronically stimulated by estrogen, without progesterone ripening and cyclic shedding, becomes **hyperplastic with irregular bleeding**.
- **With time endometrial hyperplasia can result, which could progress to endometrial cancer**.

B. Increased testosterone:

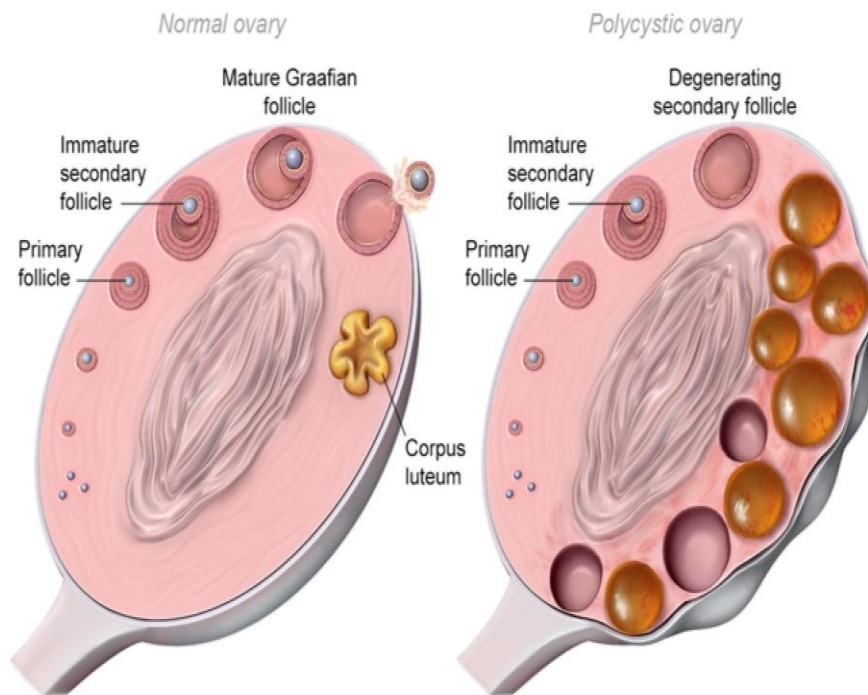
- Increased LH levels cause **increased ovarian follicular theca cell production of androgens**.
- The increased levels of androstenedione and testosterone **suppress hepatic production of SHBG by 50%**.
- The combined effect of increased total testosterone and decreased SHBG leads to **mildly elevated levels of free testosterone**. This results in **hirsutism**.

C. Ovarian enlargement:

- **On ultrasound the ovaries demonstrate the presence of the necklace-like pattern of multiple peripheral cysts (20-100 cystic follicles in each ovary)**.

- This is due to **high circulating androgens and high circulating insulin levels causing arrest of follicular development in various stages.**
- This along with stromal hyperplasia and a thickened ovarian capsule result in **enlarged ovaries bilaterally.**

### Polycystic Ovary Syndrome (PCOS)



- **Diagnosis:**
  - Diagnosis is based on the Rotterdam criteria, which requires **2 of the following 3 findings:**
    1. Oligomenorrhea or menstrual dysfunction.
    2. Hyperandrogenism, clinically or biochemically.
    3. Polycystic ovaries on sonogram ( $\geq 12$  peripheral cysts).

### Diagnosis of PCO

**Suspected**  
(Clinical)

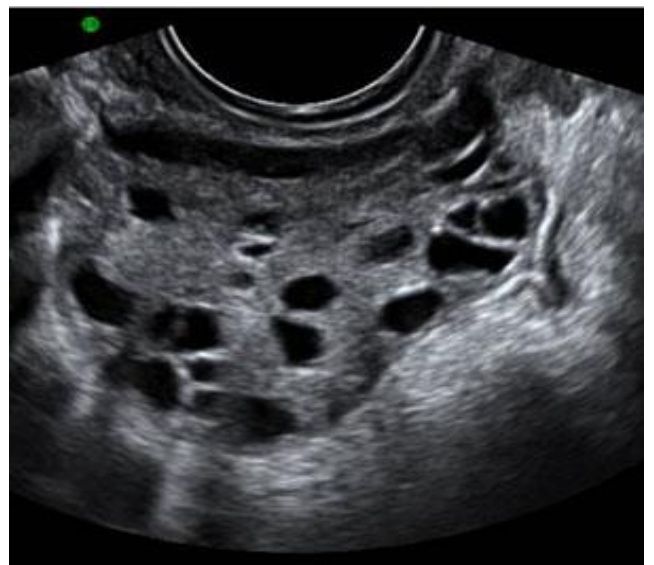
**Infertility, Irreg bleeding**

**Obesity, Hirsutism**

**Confirmed**  
(Lab test)

**LH/FSH ratio (3:1)**

Normal is 1.5:1

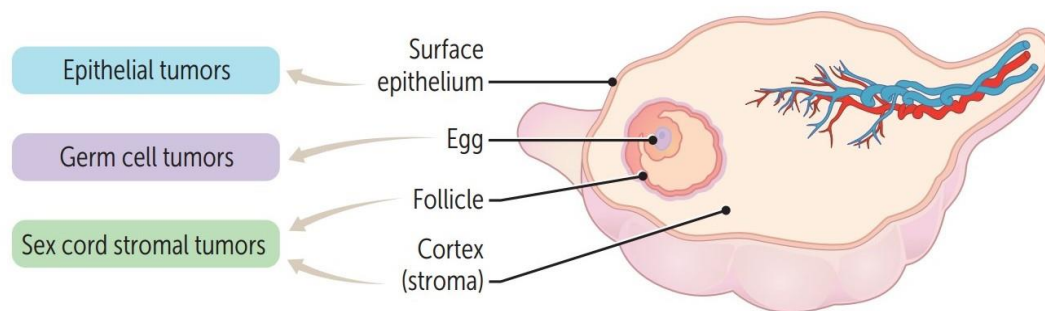


▪ Treatment:

- The first-line therapy for menstrual regulation is a combination of **weight loss and combined estrogen/progestin oral contraceptives**. Combined oral contraceptives **contain progesterone** to stabilize the uterine lining, which restores normal cycles.
- **Excess male-pattern hair growth can be suppressed 2 ways:**
  - OCPs will **lower testosterone production** by suppressing LH stimulation of the ovarian follicle theca cells. OCPs will also increase **SHBG**, thus decreasing free testosterone levels.
  - Spironolactone **suppresses hair follicle 5- $\alpha$  reductase enzyme conversion of andro- stenedione and testosterone to the more potent dihydrotestosterone**.
- If she desires pregnancy, **ovulation induction can be achieved through clomiphene citrate (Clomid) or human menopausal gonadotropin (HMG)**.
- **Clomiphene is a selective estrogen receptor modulator that prevents negative feedback inhibition on the hypothalamus by circulating estrogen, which results in increased gonadotropin production (FSH and LH) and ovulation.**
- **Metformin**, a hypoglycemic agent that increases insulin sensitivity, can enhance the likelihood of ovulation both with and without clomiphene.

## Ovarian tumors

- Ovarian cancer is **the leading cause of gynecological cancer deaths**.
- **Most common adnexal mass in women >55 years old.**
- Ovaries in the postmenopausal age group **should be atrophic; anytime they are enlarged, the suspicion of ovarian cancer arises.**
- Risk factors:
  - Risk ↑ with advanced age, Early menarche and late menopause, infertility, endometriosis, PCOS, genetic predisposition (**BRCA1 or BRCA2 mutations**, Lynch syndrome, strong family history). Nulliparous women are at increased risk for ovarian cancer **due to frequent ovulation, resulting in continued disruption and repair of the ovarian epithelium.**
  - Risk ↓ with previous pregnancy, history of breastfeeding, **OCPs**, tubal ligation. These are conditions that **decrease the total number of lifetime ovulations.**



- Ovary is composed of three cell types: surface epithelium, germ cells, and sex cord stroma.
- Tumor can arise from any of these cell types or from metastases.
- Can be **benign or malignant**.
- **Majority of malignant tumors are epithelial** (serous cystadenocarcinoma most common).
- Presents with **adnexal mass**, abdominal distension, bowel obstruction, pleural effusion.
- The most common method of ovarian carcinoma spread is by **peritoneal dissemination** (exfoliation) and is commonly seen metastatic to the omentum and to the GI tract. The presence of peritoneal fluid in a postmenopausal woman is pathologic and is the origin of the typical symptoms of **bloating, early satiety/anorexia, and abdominal distension seen in ovarian cancer.**

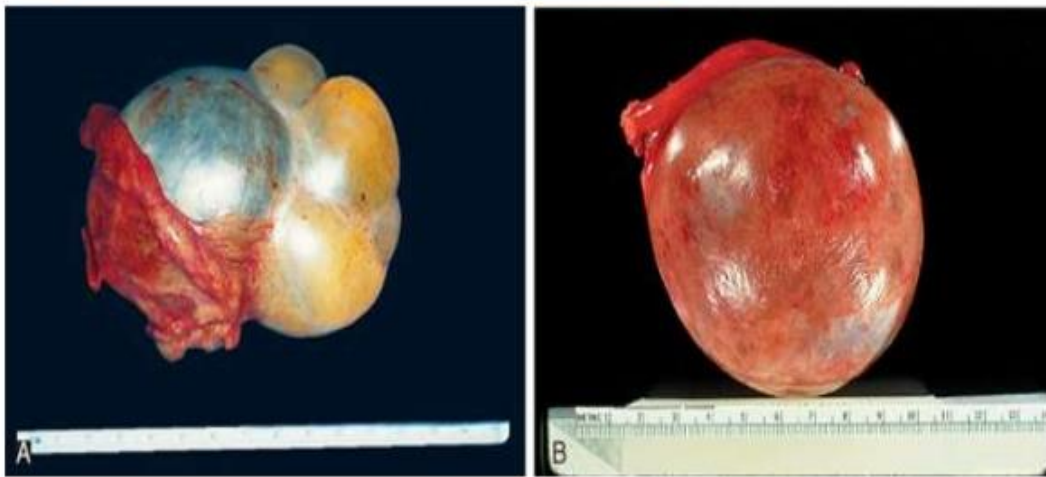## Surface epithelial tumors

- Most common type of ovarian tumor (70% of cases).
- Derived from **coelomic epithelium that lines the ovary**; coelomic epithelium embryologically produces the epithelial lining of **the fallopian tube** (serous cells), **endometrium**, and **endocervix** (mucinous cells).
- The two most common subtypes of surface epithelial tumors are **serous and mucinous**; both are usually **cystic**.
- Serous tumors are full of **watery fluid**. Mucinous tumors are full of **mucus-like fluid**.
- **Monitor response to therapy/recurrence by measuring CA 125 levels (not good for screening).**
- Prognosis is generally poor for surface epithelial carcinoma (**worst prognosis of female genital tract cancers**).
- Mucinous and serous tumors can be benign or malignant:
  1. **Serous cystadenoma:**
    - Commonly **bilateral**.
    - **Benign**.
    - Histology shows **fallopian tube-like epithelium**.
    - **Most common ovarian neoplasm**.
  2. **Serous cystadenocarcinoma:**
    - Commonly **bilateral**.
    - Most common **malignant** ovarian neoplasm.
    - **Histology shows psammoma bodies**.
  3. **Mucinous cystadenoma:**
    - Multilocular cyst
    - **Benign**
    - Lined by mucus-secreting epithelium (endocervix-like tissue).

## 4. Mucinous cystadenocarcinoma:

- Malignant.
- Rare.
- May be metastatic from appendiceal or GI tumors.
- Can result in pseudomyxoma peritonei (intraperitoneal accumulation of mucinous material).

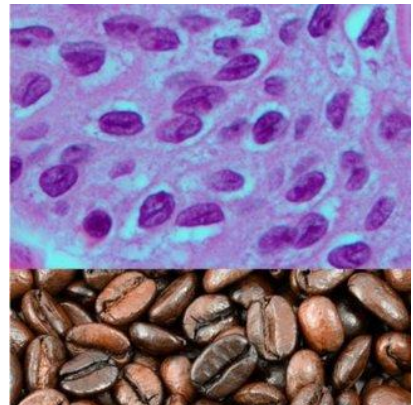
## SEROUS /MUCINOUS CYSTADENOMA



**Gross appearance of a mucinous (A) and serous (B) cystadenoma of the ovary. The mucinous type is generally multiloculated and can be quite large.**

## 5. Brenner tumor:

- Usually benign.
- “Coffee bean” nuclei on H&E stain.
- Histology shows transitional epithelium (similar to Bladder).
- Rare, usually solid.



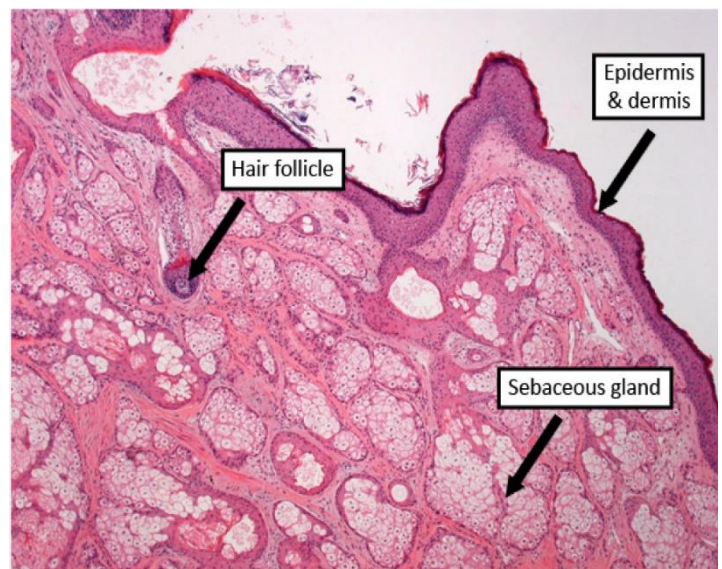
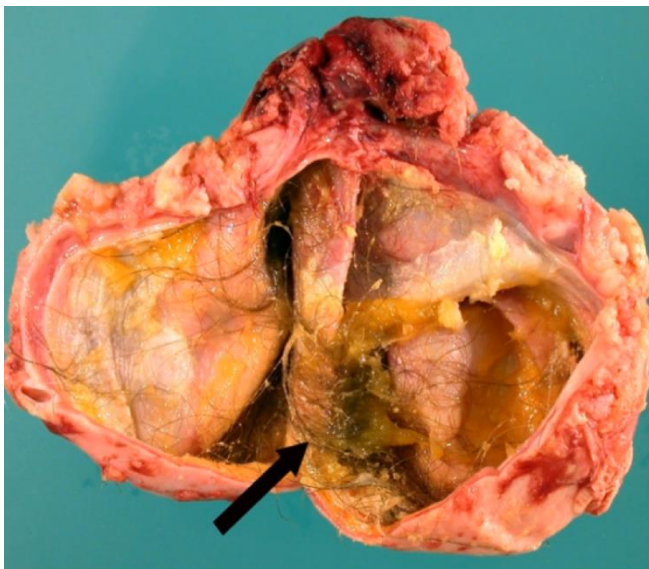


## Germ cell tumors

- 2nd most common type of ovarian tumor (15% of cases).
- Usually occur in women of reproductive age.
- Tumor subtypes mimic tissues normally produced by germ cells:
  - Fetal tissue → cystic teratoma.
  - Oocytes → dysgerminoma.
  - Yolk sac → endodermal sinus tumor.
  - Placental tissue → choriocarcinoma.

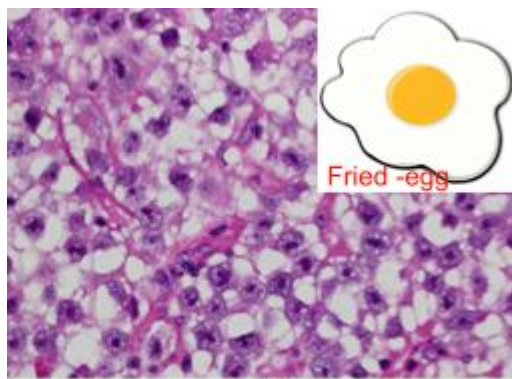
### A. Cystic teratoma:

- Cystic tumor composed of fetal tissue derived from two or three embryologic layers (skin, hair, sebum, teeth, bone, cartilage, gut, and thyroid).
- Monodermal form with thyroid tissue (*struma ovarii*) may present with hyperthyroidism.
- Most common germ cell tumor in females; bilateral in 10% of cases.
- Mature teratoma ("dermoid cyst"):
  - Benign tumor.
  - Malignant transformation rare (usually to squamous cell carcinoma).
- Immature teratoma (5%):
  - Aggressively malignant. Commonly diagnosed before age 20.
  - Contains fetal tissue, neuroectoderm.
  - Typically represented by immature/embryonic-like neural tissue.

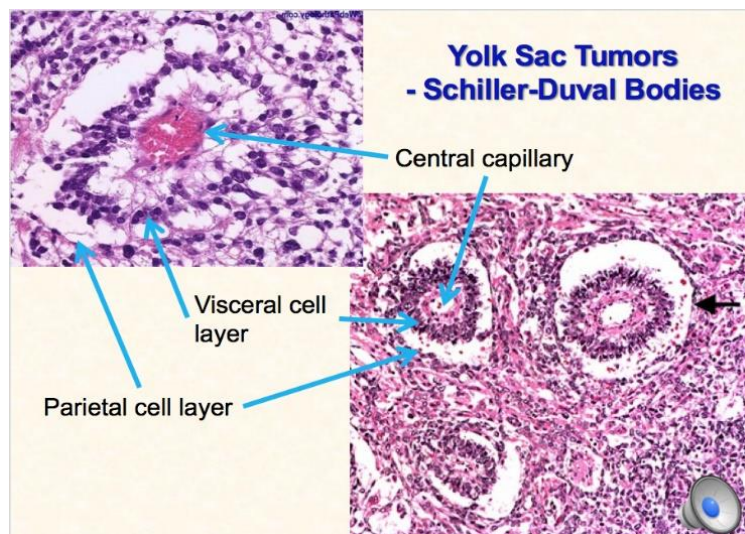


B. **Dysgerminoma:**

- Tumor composed of **large cells with clear cytoplasm and central nuclei (resemble oocytes)**.
- **Most common malignant germ cell tumor in adolescents.**
- Seen commonly in **Turner syndrome**.
- Composed of undifferentiated germ cells. Sheets of uniform (**fried egg**) cells.
- **Testicular counterpart is called seminoma, which is a relatively common germ cell tumor in males.**
- Tumor markers:  $\uparrow$  hCG, **LDH**.

C. **Yolk sac (Endodermal sinus) tumor:**

- Malignant tumor that mimics the yolk sac (Yellow, friable, hemorrhagic mass).
- **Most common germ cell tumor in children.**
- **Serum AFP is often elevated.**
- 50% have Schiller-Duval bodies (**glomerulus-like structures**) are classically seen on histology.



D. **Choriocarcinoma:**

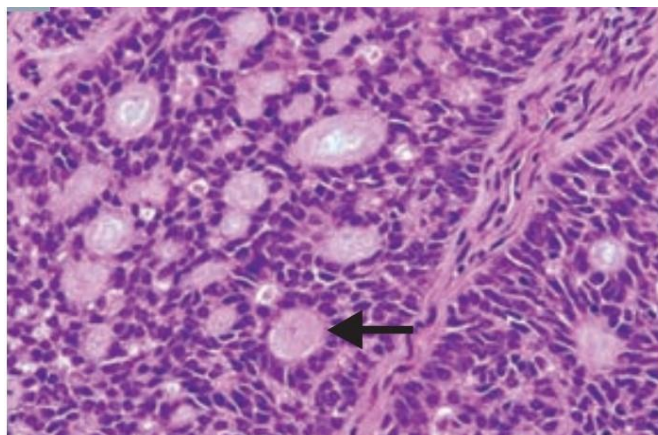
- Malignant tumor composed of trophoblasts and syncytiotrophoblasts; **mimics placental tissue, but villi are absent.**
- Small, hemorrhagic tumor with **early hematogenous spread.**
- **High  $\beta$ -hCG is characteristic** (produced by syncytiotrophoblasts); may lead to **thecal cysts in the ovary.**
- Poor response to chemotherapy.

**Sex cord stromal tumors**

- Sex cord stromal tumors develop from **embryonic sex cord** (develops into theca and granulosa cells of follicle, Sertoli and Leydig cells of seminiferous tubules) and **stromal** (ovarian cortex) **derivatives.**
- May **produce hormones** (androgens, estrogens).
- Mostly **benign.**

A. **Granulosa-theca cell tumor:**

- Neoplastic proliferation of granulosa and theca cells.
- **Most common malignant stromal tumor.**
- Often **produces estrogen and/or progesterone**; presents with signs of estrogen excess:
  - Prior to puberty → precocious puberty.
  - Reproductive age → menorrhagia or metrorrhagia.
  - Postmenopause (most common setting for granulosa-theca cell tumors) → endometrial hyperplasia with postmenopausal uterine bleeding.
- Malignant, but minimal risk for metastasis.
- Histology shows **Call-Exner bodies** (granulosa cells arranged haphazardly around collections of eosinophilic fluid, resembling primordial follicles).



## B. Sertoli-Leydig cell tumor:

- Resembles testicular histology with tubules/cords lined by pink Sertoli cells.
- May produce androgens → virilization (hirsutism, male pattern baldness, clitoral enlargement).

## C. Thecoma:

- Benign tumor.
- May produce estrogen.
- Usually presents as abnormal uterine bleeding in a postmenopausal woman.

## D. Fibroma:

- Benign tumor of fibroblasts.
- Bundles of spindle-shaped fibroblasts.
- Associated with Meigs syndrome; triad of ovarian fibroma, ascites, pleural effusion (hydrothorax).  
“Pulling” sensation in groin.

## Metastasis

- Krukenberg tumor is a metastatic mucinous tumor that involves both ovaries; most commonly due to metastatic gastric adenocarcinoma (diffuse type).
- The cardinal histologic feature is nests of signet ring cells. The appearance is a result of large amounts of mucin displacing the nucleus.
- Bilaterality helps distinguish metastases from primary mucinous carcinoma of the ovary, which is usually unilateral.

## ❖ In a nutshell:

- Produces AFP → Yolk sac (endodermal sinus) tumor.
- Estrogen- secreting, leading to precocious puberty → granulosa- theca cell tumor.
- Intraperitoneal accumulation of mucinous material → mucinous cystadenocarcinoma.
- Testosterone- secreting, leading to virilization → sertoli-leyding cell tumor.
- Psammoma bodies → serous cystadenocarcinoma.
- Multiple different tissue types → cystic teratoma.
- Lined with fallopian tube-like epithelium → serous cystadenoma.
- Ovarian tumor + ascites + hydrothorax → ovarian fibroma.
- Call-Exner bodies → granulosa-theca cell tumor.
- Resembles bladder epithelium → brenner tumor.

- Elevated  $\beta$ -hCG  $\rightarrow$  choriocarcinoma or dysgerminoma.

<b>Malignant ovarian neoplasms</b>		
<b>Histologic type</b>	<b>Diagnosis</b>	<b>Key features</b>
<b>Epithelial</b>	<b>Serous cystadenocarcinoma</b>	<ul style="list-style-type: none"> <li>• Most common ovarian cancer</li> <li>• Often bilateral</li> <li>• Histology: Psammoma bodies</li> </ul>
	<b>Mucinous cystadenocarcinoma</b>	<ul style="list-style-type: none"> <li>• Pseudomyxoma peritonei</li> <li>• Mucin-producing epithelial cells</li> </ul>
<b>Germ cell</b>	<b>Dysgerminoma</b>	<ul style="list-style-type: none"> <li>• Adolescents</li> <li>• <math>\uparrow</math> <math>\beta</math>-hCG, <math>\uparrow</math> LDH</li> <li>• Histology: "Fried egg cells"</li> </ul>
	<b>Endodermal sinus (yolk sac)</b>	<ul style="list-style-type: none"> <li>• <math>\uparrow</math> AFP</li> <li>• Aggressive</li> <li>• Schiller-Duval bodies resemble glomeruli</li> </ul>
<b>Stroma (sex cord)</b>	<b>Granulosa cell</b>	<ul style="list-style-type: none"> <li>• <math>\uparrow</math> Estrogen (eg, endometrial hyperplasia, postmenopausal bleeding)</li> <li>• <math>\uparrow</math> Inhibin</li> <li>• Histology: Call-Exner bodies, coffee bean nuclei</li> </ul>
	<b>Sertoli-Leydig</b>	<ul style="list-style-type: none"> <li>• <math>\uparrow</math> Androgens (eg, hirsutism, clitoromegaly)</li> </ul>



## Ovarian cysts

## Functional Cysts

- The most common cause of a simple cystic mass in the reproductive age years is a physiologic cyst (luteal or follicular cyst).
- During the reproductive years the ovaries are functionally active, producing a dominant follicle in the first half of the cycle and a corpus luteum after ovulation in the second half of the menstrual cycle.
- Either of these structures, the follicle or the corpus luteum, can become fluid-filled and enlarged, producing a functional cyst.
- May be associated with hyperestrogenism, endometrial hyperplasia.

## Theca Lutein Cysts

- These are benign neoplasms stimulated by high levels of FSH and  $\beta$ -hCG (ovarian hyperstimulation).
- They are associated with twins and molar pregnancies, but they are only rarely associated with a normal singleton pregnancy.
- The natural course of these tumors is postpartum spontaneous regression and require only conservative management.

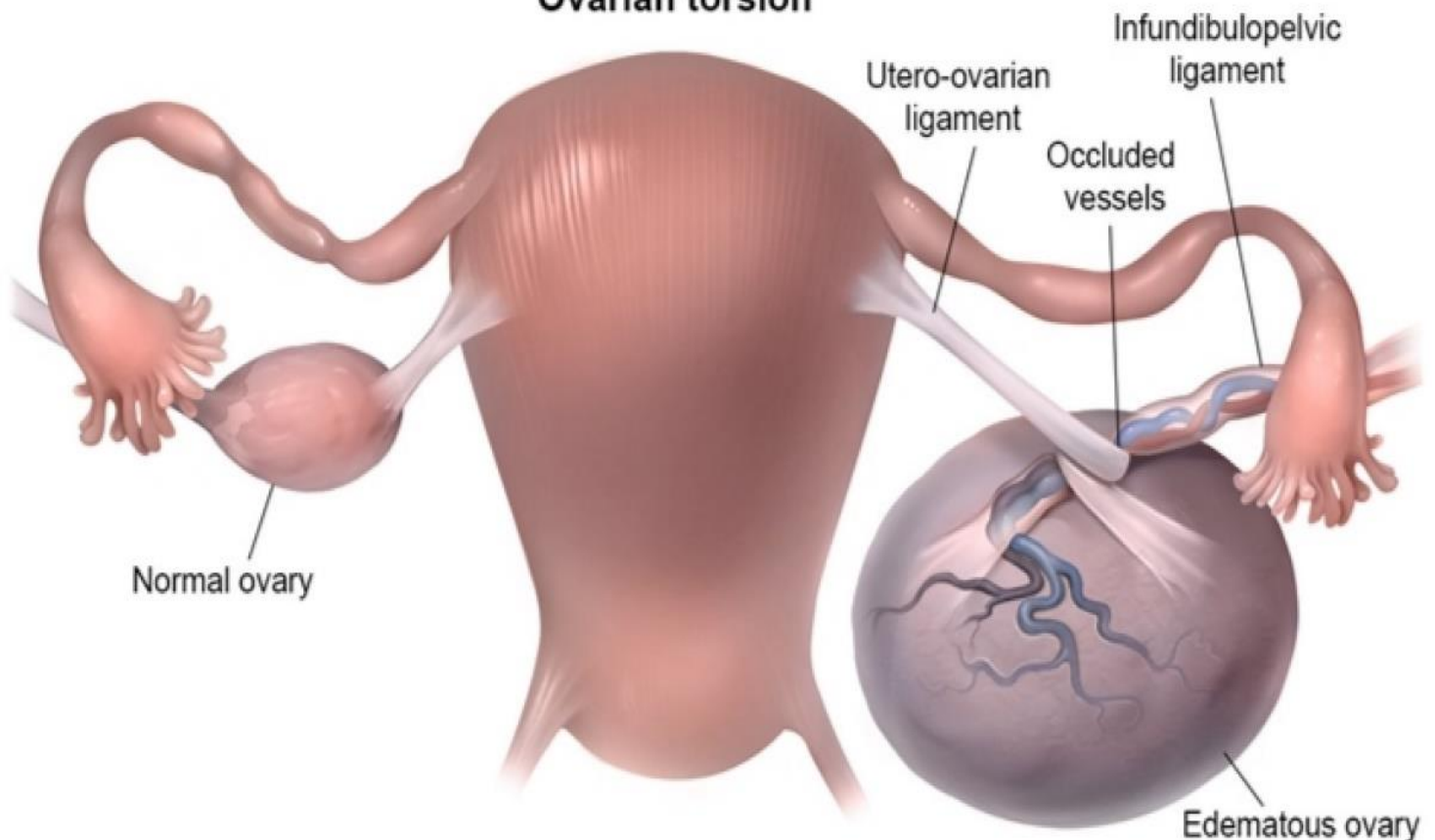
## Ovarian torsion

- Ovarian torsion is a gynecologic emergency typically occurring in premenopausal patients, including adolescents.
- Twisting of ovary and fallopian tube around infundibulopelvic ligament and ovarian ligament → compression of ovarian vessels in infundibulopelvic ligament → blockage of lymphatic and venous outflow.
- Continued arterial perfusion → ovarian edema → complete blockage of arterial inflow → necrosis, local hemorrhage.
- Sudden onset Pelvic pain, nausea, vomiting, and low-grade fever in a patient with a known ovarian mass should be suspected as ovarian torsion until proven otherwise. Symptoms arise due to ischemia and eventually necrosis of the ovary.
- Dermoid cysts in particular have a higher likelihood of torsion than other types of ovarian masses. A mass on the ovary puts weight on the adnexa and makes it vulnerable to twisting around its supporting structures.



- Diagnosis is with ultrasound demonstrating **absent blood flow to the ovary with doppler**; the **presence of an ovarian mass makes torsion more likely**.
- The management of the torsion should be to **untwist the ovary and observe the ovary for a few minutes in the operating room to ensure revitalization**. This can be performed with **laparoscopy or laparotomy**. If **revitalization** occurs, an ovarian cystectomy can be performed with **preservation of the ovary**. If the ovary is **necrotic**, a unilateral salpingo-oophorectomy is performed.

### Ovarian torsion



## Amenorrhea

▪ May be primary or secondary:- Primary:

- Amenorrhea means **absence of menstrual bleeding**.
- Primary means that menstrual bleeding has **never occurred**.
- Primary amenorrhea is diagnosed with absence of menses **at age 14 without secondary sexual development** or **age 16 with secondary sexual development**.

- Secondary:

- Amenorrhea means **absence of menstrual bleeding**.
- **Secondary** means that **previously menstrual bleeding had occurred**.
- Secondary amenorrhea is diagnosed with absence of menses for **3 months if previously regular menses** or **6 months if previously irregular menses**.

▪ Causes:A. Hypothalamic dysfunction:

- Situational stress.
- Anorexia.
- Serious illness.
- Excessive exercise.
- Excess cortisol, androgens, and prolactin.
- Malignancy.

B. Pituitary dysfunction:

- Pituitary neoplasm.
- Pituitary infarct (Sheehan's syndrome).

C. Ovarian failure:

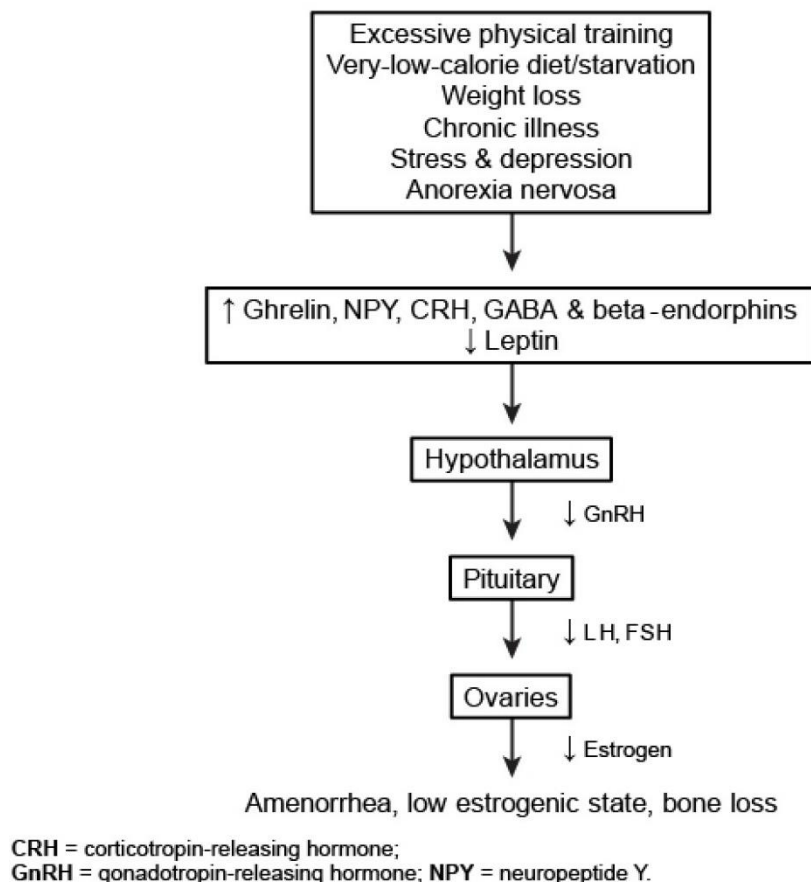
- Menopause.
- Polycystic ovarian syndrome.

- **Premature ovarian failure:**
  - Autoimmune destruction
  - Radiation
  - Chemotherapy
- Anovulatory cycles.
- Endometriosis.
- Turner syndrome (streak ovaries).
- D. **End-organ:**
  - Imperforate hymen (primary amenorrhea).
  - Mullerian agenesis (primary amenorrhea).
  - Endometrial scarring (secondary amenorrhea): Asherman syndrome.
- **Evaluation:**
  - The first thing is to **exclude pregnancy**.
  - Hypothalamic/pituitary:
    - ↓ FSH and LH
    - Hypogonadotropic hypogonadism.
  - Ovarian:
    - ↑ FSH and LH.
    - Hypergonadotropic hypogonadism.
  - End-organ:
    - Normal FSH and LH.
    - Normal estrogen and progesterone.

### Functional hypothalamic amenorrhea

- Also called exercise-induced amenorrhea.
- **Functional hypothalamic amenorrhea** is due to suppression of the hypothalamic-pituitary-ovarian axis by strenuous exercise, anorexia nervosa, marijuana use, starvation, stress depression, or chronic illness.
- Severe caloric restriction, ↑ energy expenditure, and/or stress (**inadequate nutritional intake as compared to the amount energy expended**) → functional disruption of pulsatile GnRH secretion → ↓ LH, FSH, estrogen.
- Pathogenesis includes ↓ leptin (due to ↓ fat) and ↑ cortisol (stress, excessive exercise).
- Associated with eating disorders and “**female athlete triad**” (↓ calorie availability/excessive exercise, ↓ bone mineral density, menstrual dysfunction).
- These amenorrhoeic women are therefore at increased risk for all conditions associated with estrogen deficiency, including infertility, vaginal atrophy, breast atrophy, and **osteopenia**. First-line treatment is with **lifestyle changes, specifically increased caloric intake and exercise reduction**.

### Pathophysiology of functional hypothalamic amenorrhea

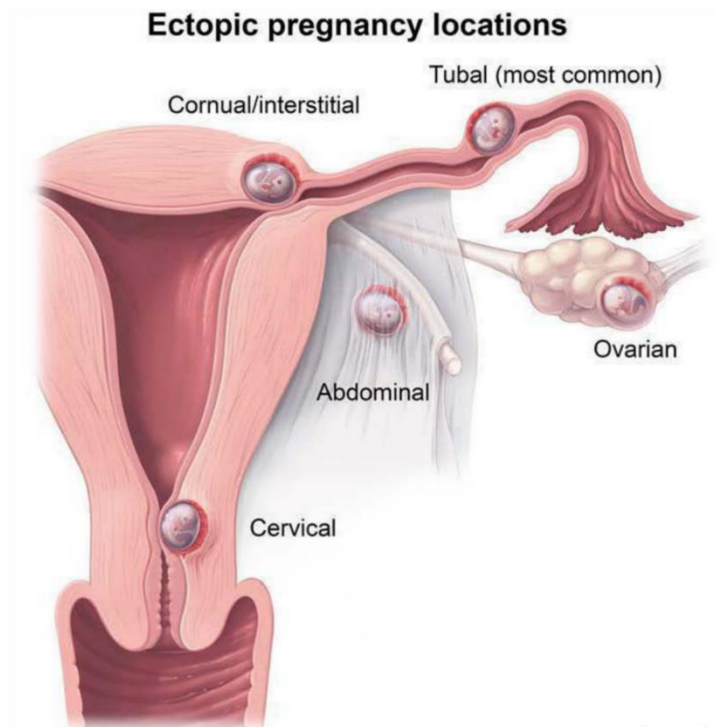


## Gestational pathology

## Ectopic Pregnancy

▪ Definition:

- This is a pregnancy in which implantation has occurred outside of the uterine cavity.
- The most common location of ectopic pregnancies is fallopian tube.
- The most common location within the fallopian tube is the distal ampulla.



▪ Risk Factors:

- The most common predisposing cause is previous pelvic inflammatory disease (PID).
- Ectopic pregnancy risk is increased from any obstruction of normal zygote migration to the uterine cavity from tubal scarring or adhesions from any origin:
  - Infectious (PID, IUD, Salpingitis).
  - Postsurgical (tubal ligation, tubal surgery).
  - Congenital (diethylstilbestrol [DES] exposure).
  - Endometriosis.
- Prior ectopic pregnancy. One percent of pregnancies are ectopic pregnancies, and if the patient has had one ectopic pregnancy, the incidence becomes 15%.
- Other risk factors include Smoking, Advanced maternal age.

- Presentation:
- The classic triad with an unruptured ectopic pregnancy is **amenorrhea, vaginal bleeding, and unilateral pelvic-abdominal pain**.
- $\beta$ -hCG should **double every 24 hours** in an intra-uterine pregnancy. In tubal pregnancy, there is prolonged doubling times (**lower-than-expected rise in hCG based on dates**).
- **Failure to see a normal intrauterine gestational sac when the serum  $\beta$ -hCG titer is  $>1,500$  mIU is presumptive diagnosis of an ectopic pregnancy**. It is based on the assumption that when a normal intrauterine pregnancy has progressed to **where it can be seen on vaginal sonogram at 5 weeks' gestation**, the serum  $\beta$ -hCG titer will exceed 1,500 mIU.
- With a **ruptured** ectopic pregnancy, the findings **reflect peritoneal irritation and the degree of hypovolemia due to intraperitoneal bleeding**. This results in **abdominal guarding and rigidity**. **Hypotension and tachycardia indicate significant blood loss**.

### Spontaneous abortion

- Miscarriage of fetus occurring **before 20 weeks gestation** (usually during first trimester).
- Common; occurs in up to 1/4 of recognizable pregnancies
- Presents as vaginal bleeding, cramp-like pain, and passage of fetal tissues.
- **Most often due to chromosomal anomalies**; other causes include hypercoagulable states (**antiphospholipid syndrome**), congenital infection, and exposure to teratogens (especially during the first 2 weeks of embryogenesis).

### Placental abruption (abruptio placentae)

- Etiology/Pathophysiology:
- **A normally implanted placenta (not in the lower uterine segment) separates from the uterine wall before delivery of the fetus**.
- **Most commonly bleeding is overt and external**. In this situation blood dissects between placental membranes exiting out the vagina.
- **Less commonly**, if bleeding **remains concealed or internal**, the retroplacental hematoma remains within the uterus.
- Risk Factors:
- Abruptio placentae is seen more commonly with **previous abruption, hypertension, and maternal blunt trauma** (motor vehicle accident).



- Other risk factors are **smoking and maternal cocaine abuse**.
- Presentation:
- Abruptio placentae is **the most common cause of painful late-trimester bleeding**, occurring in **1%** of pregnancies at term.
- Diagnosis is based on the presence of **painful late-trimester vaginal bleeding with a normal fundal or lateral uterine wall placental implantation** not over the lower uterine segment.
- Significant bleeding puts the patient at risk for hypovolemic shock and **disseminated intravascular coagulation due to tissue factor released by decidual bleeding**. May be life threatening for mother and fetus.

### Etiology: LATE PREGNANCY BLEEDING?

**Abruptio placenta**

**Placenta previa**

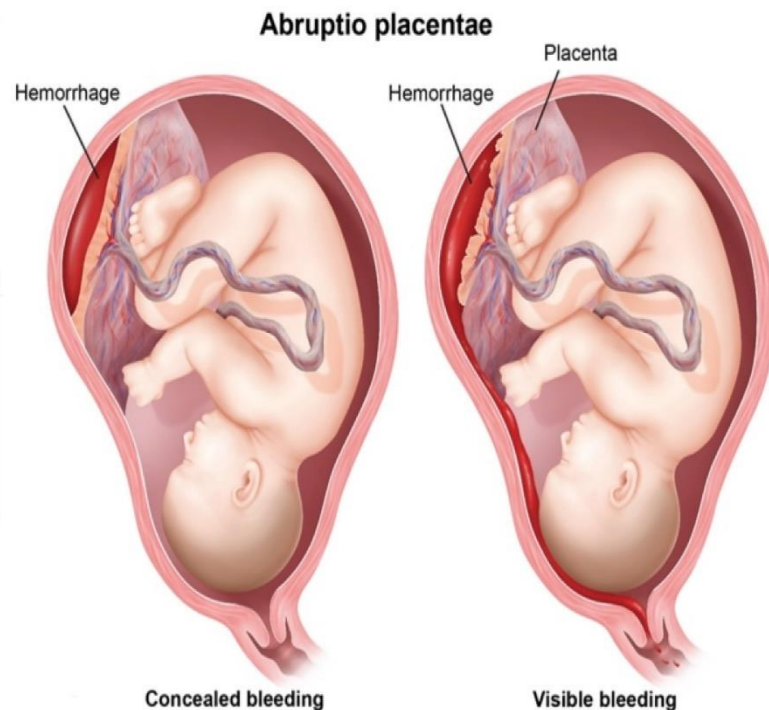
**Vasa previa**

**Uterine rupture**

**Lower Genital Tract**

Pain  
LESS

Pain  
FULL

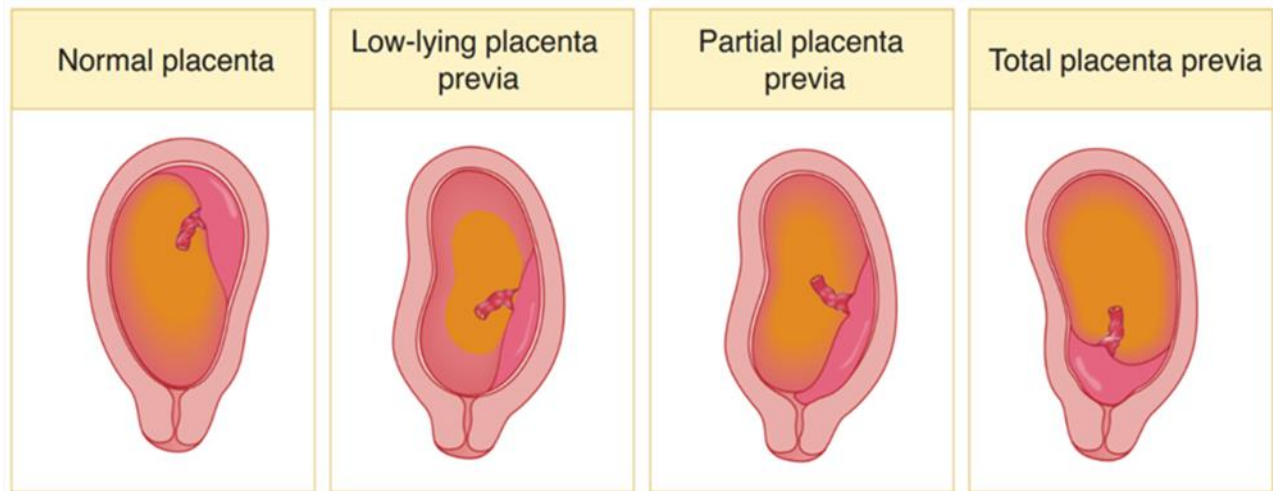


❖ N.B:

- Late pregnancy bleeding: Vaginal bleeding occurring **after 20 weeks' gestation**.

### Placenta previa

- Etiology/Pathophysiology:
- Placenta previa is present **when the placenta is implanted in the lower uterine segment**.
- Usually the lower implanted placenta atrophies and the upper placenta hypertrophies, resulting in migration of the placenta.
- At term placenta previa is found in only **0.5% of pregnancies**.



▪ Risk Factors:

- Placenta previa is seen more commonly with previous placenta previa, multiparity, and multiple gestation (increase placental surface area).
- Increasing cesarean delivery rates have caused an increased incidence of placenta previa because the uterine scar and change in vascularity likely alter early pregnancy implantation.

▪ Presentation:

- This is based on the presence of painless late-trimester vaginal bleeding with an obstetric ultrasound showing placental implantation over the lower uterine segment.
- Painless vaginal bleeding develops due to avulsion of the anchoring villi of an abnormally implanted placenta as lower uterine segment stretching occurs in the latter part of pregnancy.
- Often requires delivery of fetus by caesarian section. Pelvic exam is contraindicated.

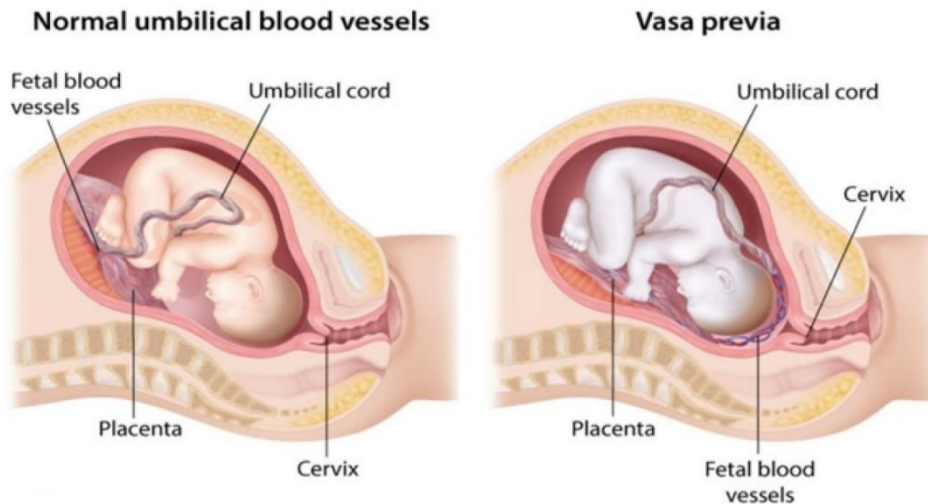
Vasa previa

▪ Etiology/Pathophysiology:

- Vasa previa is present when fetal vessels traverse the fetal membranes over the internal cervical os.
- These vessels may be from either a velamentous insertion of the umbilical cord (cord inserts in chorioamniotic membrane rather than placenta → fetal vessels travel to placenta unprotected by Wharton jelly) or may be joining an accessory (succenturiate) placental lobe to the main disk of the placenta.
- If these fetal vessels rupture the bleeding is from the fetoplacental circulation, and fetal exsanguination will rapidly occur, leading to fetal death.

▪ **Presentation:**

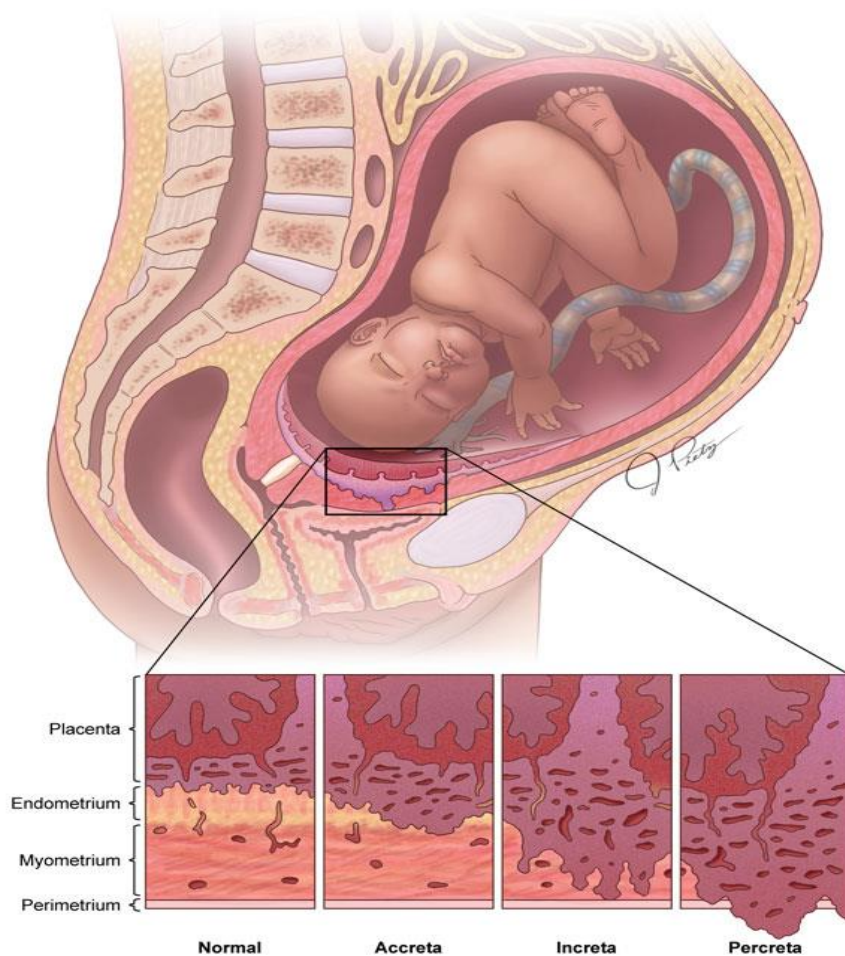
- The classic triad is **rupture of membranes and painless vaginal bleeding, followed by fetal bradycardia (< 110 beats/min).**
- **Immediate cesarean delivery of the fetus is essential, or the fetus will die from hypovolemia.**



**Placenta accreta/increta/percreta**

- Placental villi **normally invade only the superficial layers of the endometrial decidua basalis.**
- When the villi invade too deeply into the wall of the uterus, the condition is known as placenta accreta, placenta increta, or placenta percreta, depending the depth of the invasion:
  - **Placenta accreta occurs when the villi invade the deeper layers of the endometrial decidua basalis but do not penetrate the myometrium. Placenta accreta is the most common, accounting for approximately 80% of all cases.**
  - Placenta **increta** occurs when the villi **invade the myometrium but do not reach the uterine serosal surface or the bladder.** It accounts for approximately 15% of all cases.
  - Placenta **percreta** occurs when the villi **invade all the way to the uterine serosa (invades entire uterine wall) or into the rectum or bladder (can result in hematuria).** Placenta percreta is **the least common of the 3 conditions**, accounting for approximately 5% of all cases.
- Risk factors for placenta accreta include a **prior cesarean delivery, a history of dilation and curettage, placenta previa, and maternal age >35.**
- Antenatally diagnosed placenta accreta is delivered by **planned cesarean hysterectomy.**

- Undiagnosed placenta accreta **presents as difficulty with placental delivery**. The placenta does not detach from the uterus and necessitates a manual extraction, which is then complicated by **severe hemorrhage (can cause Sheehan syndrome)**. Often requires **hysterectomy**.



### Postpartum hemorrhage

- Postpartum hemorrhage (PPH) is an obstetrical emergency and a major cause of maternal mortality. Hemostasis after placental delivery is achieved by **clotting** and by compression of the placental site blood vessels by **myometrial contraction**. Disruption of either of these processes can lead to PPH.
- Due to 4 **T**'s: **T**one (uterine atony; most common), **T**rauma (lacerations, incisions, uterine rupture), **T**hrombin (coagulopathy), **T**issue (retained products of conception).
- Atony is the most common cause of excessive postpartum bleeding.**
- Atony occurs when the uterus becomes **fatigued** (prolonged labor), **over-distended** (fetal weight >4000, multiple gestation), or **unresponsive to oxytocin** from oxytocin receptor saturation.
- Treatment:** uterine massage, oxytocin. **If refractory, surgical ligation of uterine or internal iliac artery (will preserve fertility since ovarian arteries provide collateral circulation).**

## ❖ N.B:

- Ovarian vein thrombosis is an example of **septic pelvic thrombophlebitis**, a complication that can occur via vaginal or cesarean delivery.
- Patients with ovarian vein thrombosis typically present with **fever and localized abdominal pain one week after delivery and are usually hospitalized for a presumed uterine infection**. When fever persists despite antibiotics, a CT or MRI scan can confirm the presence of a thrombus in the ovarian vein.
- Ovarian venous drainage is asymmetric; the left ovarian vein drains into the left renal vein while **the right ovarian vein drains directly into the IVC**, and a clot can potentially extend into the IVC. Ovarian vein thrombosis is more commonly right-sided, but pulmonary emboli are uncommon and morbidity/mortality is low.

Postpartum ovarian vein thrombosis	
<b>Risk factors</b>	<ul style="list-style-type: none"> <li>• Venous stasis (ovarian venous dilation)</li> <li>• Hypercoagulability (hormonally-mediated increase in clotting factors)</li> <li>• Endothelial damage (intrapartum vascular injury)</li> </ul>
<b>Clinical features</b>	<ul style="list-style-type: none"> <li>• Persistent fever after delivery</li> <li>• Localized abdominal/flank pain</li> <li>• No response to antibiotics</li> </ul>

### Hypertension in pregnancy

- Pathophysiology:

- Pathophysiology involves **diffuse vasospasm** caused by:
  - Loss of the normal pregnancy-related refractoriness to vasoactive substances such as **angiotensin**.
  - Relative or absolute changes in the following prostaglandin substances: **increases in the vasoconstrictor thromboxane along with decreases in the potent vasodilator prostacyclin**.
- This vasospasm contributes to intravascular volume constriction and **decreased perfusion of most organs including uteroplacental unit, kidneys, liver, brain, and heart**.
- Decreased renal blood flow leads to **decreased clearance of body metabolic wastes**.
- Capillary injury leads to loss of intravascular volume into the interstitial space and subsequent **edema**.
- Uteroplacental insufficiency can lead to **fetal growth restriction/low birth weight (small for gestational age infant) even if the neonate is delivered at term**.

### Gestational hypertension (pregnancy-induced hypertension)

- Definition:

- Gestational hypertension is diagnosed with **sustained elevation of BP  $\geq$  140/90 mmHg after 20 weeks of pregnancy without proteinuria**.
- BP **returns to normal baseline postpartum**.
- **Preeclampsia should always be ruled out**. No proteinuria or end-organ damage.

- Symptoms:

- **No symptoms of preeclampsia are seen** (headache, epigastric pain, visual disturbances).

- Treatment:

- Antihypertensives (**H**ydralazine,  **$\alpha$ -M**ethyldopa, **L**abetalol, **N**ifedipine), deliver at 37–39 weeks. **H**ypertensive **M**oms **L**ove **N**ifedipine.
- Close observation since **30% of patients will develop preeclampsia**.



## Preeclampsia

- Presentation:
  - New-onset hypertension with either **proteinuria or end-organ dysfunction** after 20th week of gestation (< 20 weeks suggests molar pregnancy).
  - End-organ dysfunction may include **symptoms** (headache, epigastric pain, visual changes), **thrombocytopenia** (platelet count <100,000/mL), **doubling of liver transaminases, pulmonary edema, serum creatinine >1.1 mg/dL, or doubling of serum creatinine.**
  - Edema may or may not be seen.
  - Incidence ↑ in patients with pre-existing hypertension, diabetes, chronic renal disease, autoimmune disorders.
  - May proceed to **eclampsia** (+ seizures) and/or **HELLP syndrome.**
- Complications: placental abruption, coagulopathy, renal failure, uteroplacental insufficiency, eclampsia.
- Treatment: antihypertensives, IV magnesium sulfate (to prevent seizure); definitive treatment is delivery of fetus.

## Eclampsia

- Preeclampsia + **maternal seizures.**
- Eclampsia is the presence of **unexplained generalized seizures in a hypertensive, proteinuric pregnant woman in the last half of pregnancy.**
- Maternal death due to stroke, intracranial hemorrhage, or ARDS.
- Treatment: IV magnesium sulfate, antihypertensives, immediate delivery.

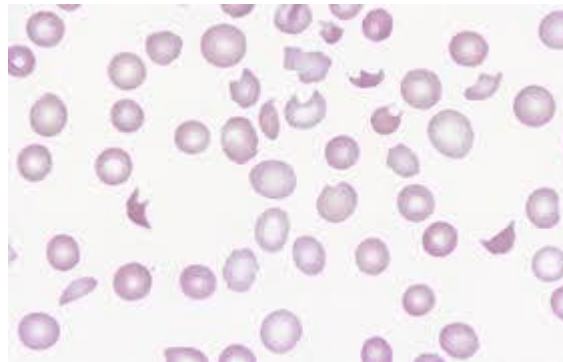
## HELLP syndrome

- HELLP syndrome is **a potential manifestation of severe preeclampsia** (preeclampsia with thrombotic microangiopathy involving the liver).
- Characterized by **Hemolysis, Elevated Liver enzymes, Low Platelets.**
- Blood smear shows **schistocytes.**

- Can lead to hepatic subcapsular hematomas → rupture → **severe hypotension**.
- Treatment: immediate delivery.

### Hypertensive disorders of pregnancy

<b>Chronic hypertension</b>	<ul style="list-style-type: none"> <li>• Systolic pressure <math>\geq 140</math> mm Hg &amp;/or diastolic pressure <math>\geq 90</math> mm Hg prior to conception or 20 weeks gestation</li> </ul>
<b>Gestational hypertension</b>	<ul style="list-style-type: none"> <li>• New-onset elevated blood pressure at <math>\geq 20</math> weeks gestation</li> <li>• No proteinuria or end-organ damage</li> </ul>
<b>Preeclampsia</b>	<ul style="list-style-type: none"> <li>• New-onset elevated blood pressure at <math>\geq 20</math> weeks gestation</li> <li><b>AND</b></li> <li>• Proteinuria <b>OR</b> signs of end-organ damage</li> </ul>
<b>Eclampsia</b>	<ul style="list-style-type: none"> <li>• Preeclampsia</li> <li><b>AND</b></li> <li>• New-onset grand mal seizures</li> </ul>



## Gestational Trophoblastic disease (GTD)

### ▪ Definition:

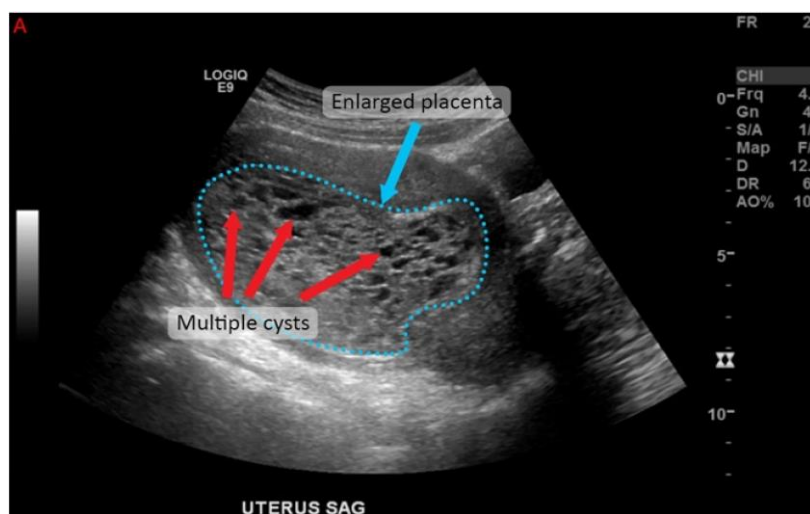
- GTD is an **abnormal proliferation of placental tissue involving both the cytotrophoblast and/or syncytiotrophoblast.**
- **It can be benign or malignant.**

### ▪ Classification:

- **Benign GTN is the classic hydatidiform mole.**
- Hydatidiform mole is **cystic swelling of chorionic villi and proliferation of chorionic epithelium (only trophoblast).**

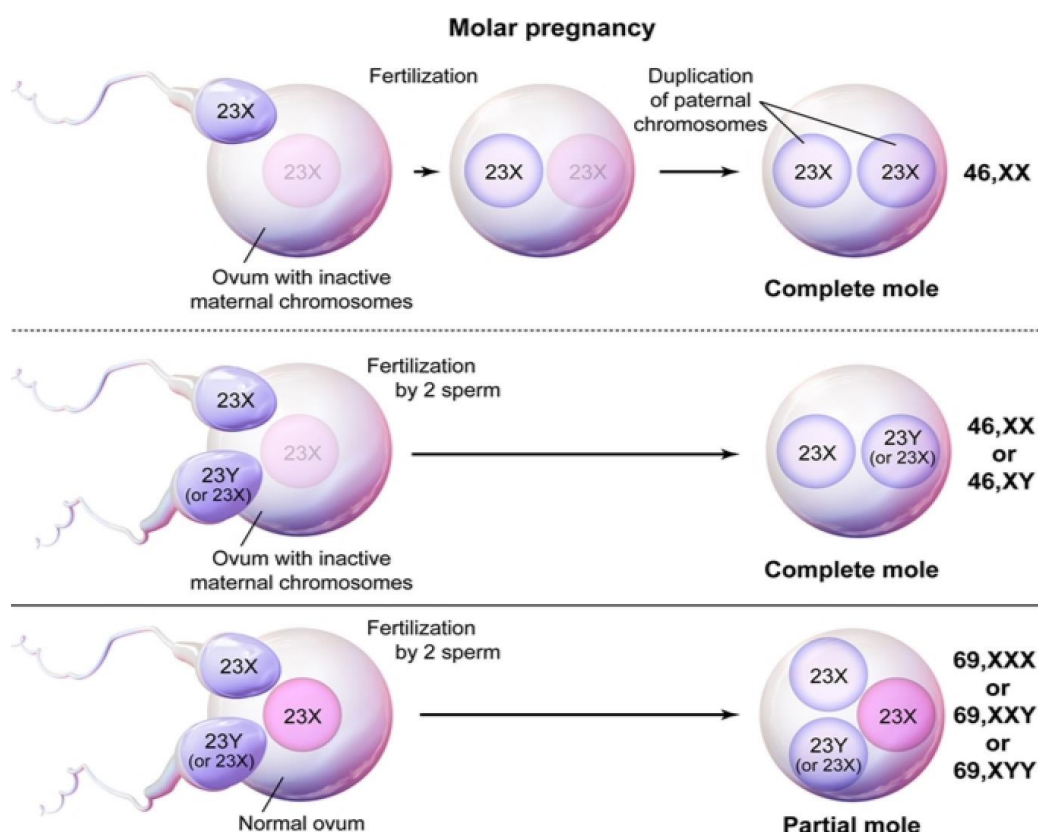
#### A. Complete mole:

- Complete mole is **the most common benign GTN.**
- It results from **fertilization of an empty egg with a single X sperm** resulting in **paternally derived (androgenetic) normal 46, XX karyotype.**
- **No fetus, umbilical cord or amniotic fluid is seen.**
- The uterus is filled with **grape-like vesicles** composed of **edematous avascular villi.**
- The characteristic ultrasound finding of a complete hydatidiform mole is an endometrium with a **"snowstorm appearance"**. This appearance is due to **cystic hydropic villi that create a heterogenous mass but no fetus or amniotic fluid.** Additional ultrasound findings may include theca lutein cysts: large, bilateral, multilocular cysts that occur due to ovarian hyperstimulation.
- **Progression to malignancy is 20%.**



B. **Partial mole:**

- Incomplete mole is the **less common benign GTN**.
- It results **from fertilization of a normal egg with two sperm** resulting in **triploid 69, XXY karyotype**.
- **A fetus, umbilical cord and amniotic fluid is seen** which results ultimately in **fetal demise**.
- **Progression to malignancy is 10%**.



	Complete mole	Partial mole
<b>Karyotype</b>	46,XX; 46,XY (only from the father)	69,XXX; 69,XXY; 69,XYY
<b>Components</b>	Most commonly enucleated egg + single sperm (subsequently duplicates paternal DNA)	2 sperm + 1 egg
<b>Villous edema</b>	Most villi are hydropic	Some villi are hydropic, and some are normal.
<b>Trophoblastic proliferation</b>	Diffuse, circumferential proliferation around hydropic villi	Focal proliferation present around hydropic villi.
<b>Fetal parts</b>	No	Yes ( <b>partial</b> = fetal <b>parts</b> )
<b>Uterine size</b>	↑	---
<b>Hcg</b>	↑↑↑↑	↑

Imaging	"Honeycombed" uterus or "clusters of grapes", "snowstorm" on ultrasound.	Fetal parts
Risk of malignancy (gestational trophoblastic neoplasia)	15–20%	< 5%
Risk of choriocarcinoma	2%	Rare

▪ Presentation:

- Presents with vaginal bleeding and passage of grape-like masses through the vaginal canal, emesis, uterine enlargement more than expected, absence of fetal heart tones, pelvic pressure/pain.
- Associated with hCG-mediated sequelae (increased hCG secretion by the proliferating trophoblast): early preeclampsia (before 20 weeks), theca-lutein cysts, hyperemesis gravidarum, hyperthyroidism.
- Hydatidiform mole can present with theca lutein cysts, bilateral multiloculated ovarian cysts that are associated with ovarian hyperstimulation from markedly elevated  $\beta$ -hCG levels. The theca lutein cysts resolve after treatment of the hydatidiform mole when the  $\beta$ -hCG level decreases.

▪ Treatment:

- Dilation and curettage to evacuate the uterine contents.
- Serial measurements of  $\beta$ -hCG should be performed following evacuation of a hydatidiform mole. Persistently elevated or rising levels may signify the development of an invasive mole or choriocarcinoma.
- In the majority of patients with a complete mole, evacuation leads to recovery.
- In some, however, an invasive mole (penetrates the uterine wall) or choriocarcinoma (malignancy of trophoblastic cells) may develop.
- An invasive mole would consist of hydropic villi and proliferated trophoblast, while choriocarcinoma would contain atypical cytotrophoblastic and syncytiotrophoblastic cells with foci of hemorrhage and necrosis and no villi.

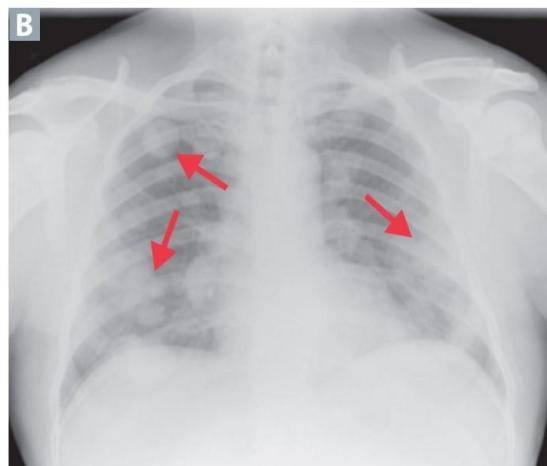
## Choriocarcinoma

### ▪ Definition:

- Malignant tumor composed of trophoblasts and syncytiotrophoblasts; mimic placental tissue, but **villi are absent**.
- Choriocarcinoma may arise as a **complication of gestation** (spontaneous abortion, normal pregnancy, or hydatidiform mole) or as a **spontaneous germ cell tumor**.
- Although it most commonly **follows a hydatidiform mole, choriocarcinoma can occur after a normal gestation or spontaneous abortion**. Choriocarcinoma typically presents <6 months after a pregnancy.
- Choriocarcinomas that arise from the gestational pathway **respond well to chemotherapy**; those that arise from the germ cell pathway **do not**.

### ▪ Presentation:

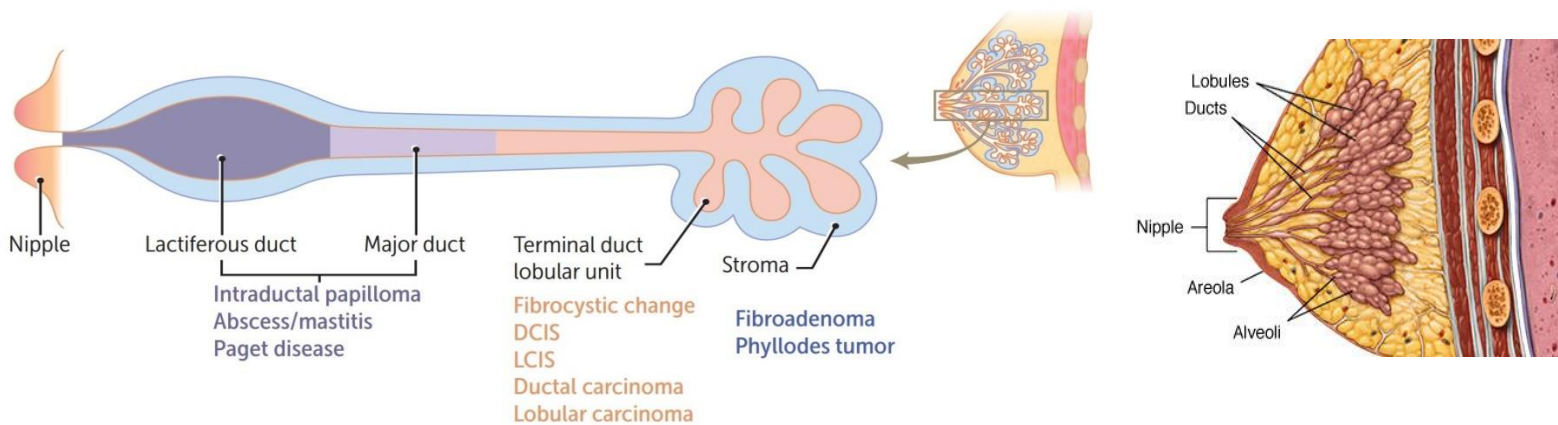
- Clinically, the tumor causes **abnormal vaginal bleeding, uterine enlargement, and significantly increased chorionic gonadotropin levels**.
- High hCG is characteristic (produced by syncytiotrophoblasts); may lead to thecal cysts in the ovary.
- Histologically, it is composed of abnormal proliferations of both cytotrophoblasts and syncytiotrophoblasts. **No villi are present**.
- Choriocarcinoma is an **aggressive tumor** that rapidly invades the uterine wall and metastasizes **hematogenously**.
- **The lungs are the most common site of distal spread “cannonball” metastases**. Symptoms of pulmonary metastasis include **chest pain, hemoptysis, and dyspnea**.
- This tumor is **highly sensitive to chemotherapy**.





## Breast

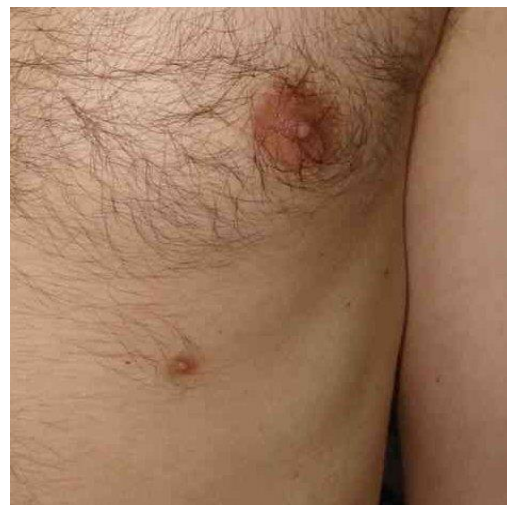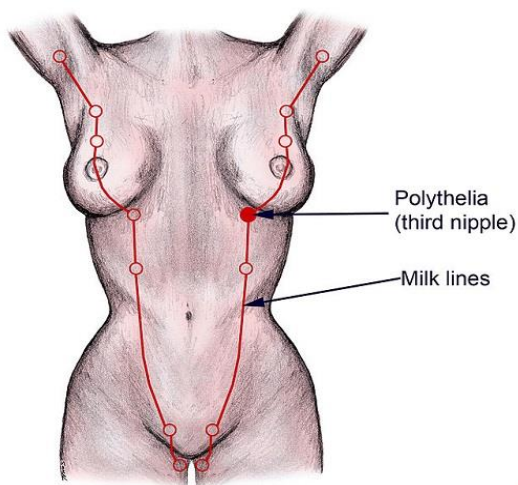
- Modified sweat gland embryologically derived from the skin.
- **The terminal duct lobular unit is the functional unit of the breast.**
- Lobules make milk that drains via ducts to the nipple.
- Lobules and ducts are lined by two layers of epithelium:
  - **Luminal cell layer:** inner cell layer lining the ducts and lobules; **responsible for milk production in the lobules.**
  - **Myoepithelial cell layer:** outer cell layer lining ducts and lobules; **contractile function propels milk towards the nipple.**



- Breast tissue is hormone sensitive:
  - **Estrogen** is responsible for **the growth of the ducts, nipples and fat.**
  - **Progesterone** is responsible for **the growth of lobules and alveoli.**
  - **Prolactin** is responsible for **production of milk.**
  - **Oxytocin** is responsible for **ejection of milk.**
- Development after menarche is primarily driven by estrogen and progesterone.
- Breast tenderness during the menstrual cycle is a common complaint, especially prior to menstruation.
- During pregnancy, breast lobules undergo hyperplasia under the effect of estrogen and progesterone.
- After menopause, breast tissue undergoes atrophy.

### Polythelia

- The most common breast congenital anomalies seen in women (and men) are accessory nipples (polythelia).
- Breast tissue can develop anywhere along the milk line, which runs from the axilla to the vulva (supernumerary nipples) and are bilateral in 50% of patients.
- They are due to failure of appropriate involution of the mammary ridge.
- Accessory nipples are usually asymptomatic, though they may swell or become tender along with the other breast tissue before or during menses.
- They are often confused with nevi.
- Accessory nipples also can become symptomatic during pregnancy and lactation.
- Accessory nipples can be excised, but no treatment is normally needed.

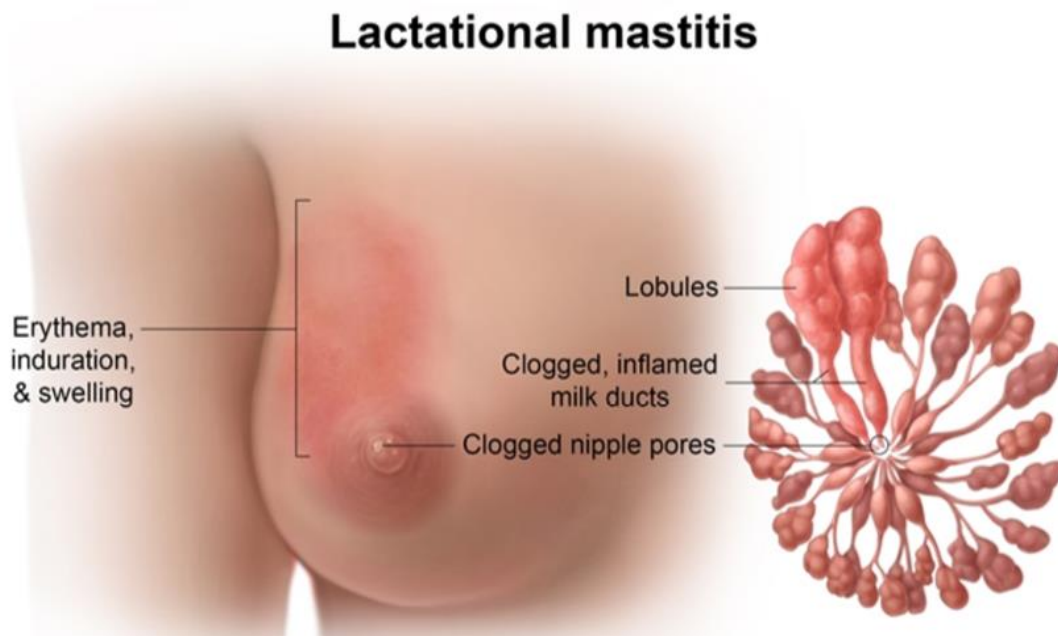


### Inflammatory conditions

#### Lactational mastitis

- Bacterial infection of the breast, usually due to *Staphylococcus aureus*.
- Associated with breast-feeding; fissures develop in the nipple providing a route of entry for microbes.

- Presents as an **erythematous breast with purulent nipple discharge**; may progress to abscess formation (without adequate antibiotic treatment).
- Treatment involves **continued drainage (breast-feeding)** and antibiotics (dicloxacillin). **Continue breast feeding in affected breast, it helps to reduce the risk of developing into a breast abscess.**

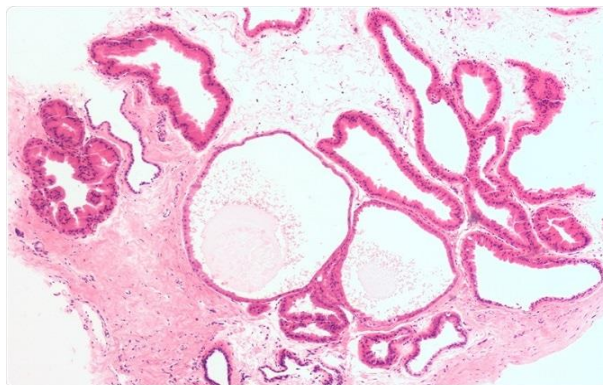


### Fat necrosis

- **Necrosis of breast fat.**
- Usually related to **trauma** (breast surgery or seatbelt injury); however, a history of trauma may not always be evident.
- Presents as a **painless mass on physical exam or abnormal calcification** on mammography (due to saponification).
- Fat necrosis can **mimic breast cancer in its clinical and radiographic presentation** because it **commonly presents as a fixed mass with skin or nipple retraction and gives the appearance of calcifications on mammography.**
- Biopsy shows **necrotic fat with associated calcifications and giant cells.**

## Fibrocystic Breast Changes

- Development of fibrosis and cysts in the breast.
- Most common in **premenopausal women > 35 years**; thought to be hormone mediated.
- **Fibrocystic breast changes are a common cause of cyclic breast pain in women of reproductive age.**
- Classic clinical findings are **diffusely nodular breasts with nonfocal tenderness (often bilateral) and no nipple discharge or lymphadenopathy.**
- The changes may develop from **fluctuations in estrogen and progesterone during the menstrual cycle.**
- Symptoms typically **improve during or after menstruation.**
- Cysts have a **blue-dome appearance** on gross exam.

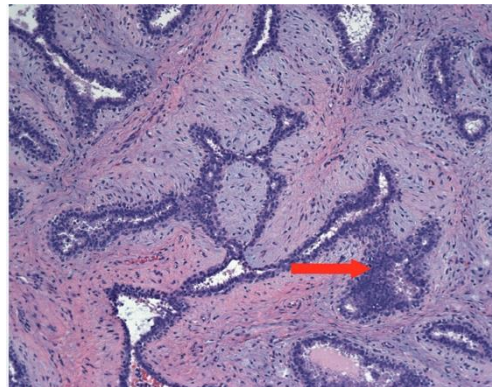


- **Benign**, but some fibrocystic-related changes are associated with an increased risk for invasive carcinoma (**increased risk applies to both breasts**):
  - Fibrosis, simple cysts (fluid-filled duct dilation, blue dome), and apocrine metaplasia → no increased risk.
  - **Sclerosing adenosis** (↑ acini and stromal fibrosis, associated with calcifications) → 2x increased risk.
  - **Epithelial hyperplasia** (↑ cells in terminal ductal or lobular epithelium) → 5x increased risk with atypical cells.
- Patients can be offered nonsteroidal anti-inflammatory drugs and/or oral contraceptives (OCs) for symptomatic relief.

## Benign Breast Tumors

## Fibroadenoma

- Tumor of fibrous tissue and glands. Histologically, fibroadenomas are characterized by a benign-appearing cellular or myxoid stroma that encircles epithelium-lined glandular and cystic spaces (arrow).
- Fibroadenomas are the most common breast tumors found in adolescence and young women.
- The mass is typically rubbery, mobile, and well-circumscribed, and is located in the outer quadrant of the right breast (breast mouse).
- ↑ size and tenderness with ↑ estrogen (pregnancy, prior to menstruation) as the pathogenesis of fibroadenoma is related to fluctuating estrogen and progesterone levels.
- The most distinctive gross feature of fibroadenomas that allows them to be distinguished from other breast lumps is their mobility.
- Frequently regress after menopause.
- Benign with no increased risk of carcinoma.

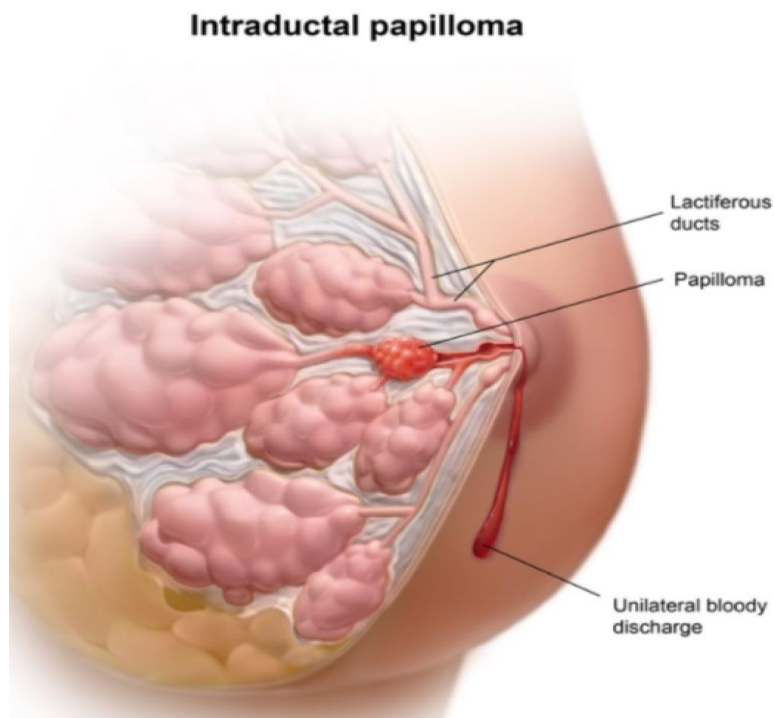


## Intraductal papilloma

- Papillary growth, usually into a large duct.
- Characterized by fibrovascular projections lined by epithelial (luminal) and myoepithelial cells.
- Bloody discharge without a corresponding breast mass or nipple changes in the setting of normal mammography is the classic presentation of intraductal papilloma, a benign breast condition.
- The most common cause of unilateral bloody discharge in premenopausal females without a coexisting breast mass is an intraductal papilloma.
- Typically, this benign condition is nonpalpable on clinical breast examination due to the small size of the papilloma inside the duct.
- Must be distinguished from papillary carcinoma, which also presents as bloody nipple discharge.
- Papillary carcinoma is characterized by fibrovascular projections lined by epithelial cells without underlying myoepithelial cells.

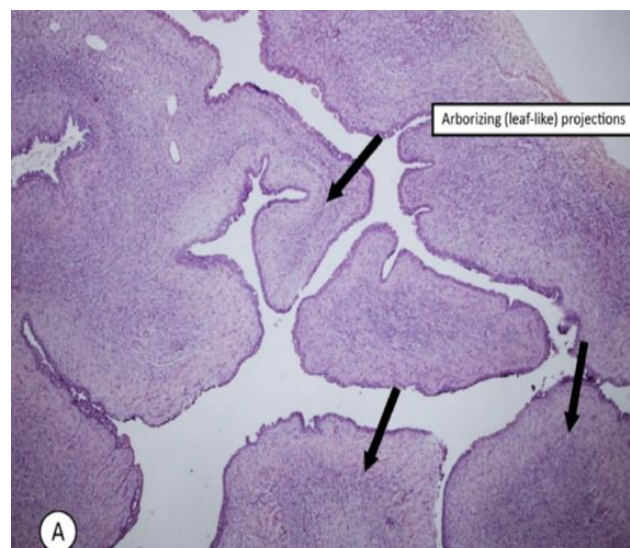


- Risk of papillary carcinoma increases with age; thus, it is more commonly seen in postmenopausal women.



### Phyllodes tumor

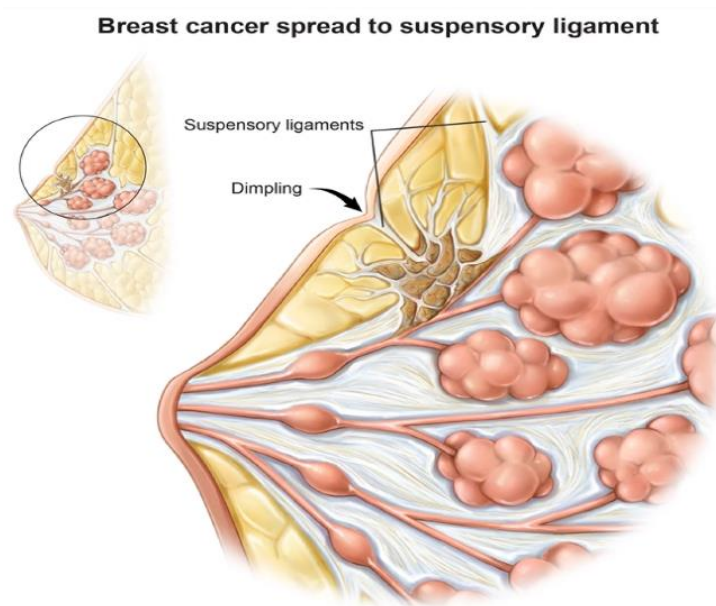
- Fibroadenoma-like tumor with overgrowth of the fibrous component; characteristic 'leaf-like' projections are seen on biopsy.
- Most commonly seen in postmenopausal women.
- Can be malignant in some cases.





### Malignant breast tumors

- **Most common carcinoma in women by incidence** (excluding skin cancer).
- **2nd most common cause of cancer mortality in women.**
- Commonly **postmenopausal**. Often presents as a **palpable hard mass**, most often in the **upper outer quadrant**. **Overlying skin retractions (dimpling) signal involvement of suspensory ligaments of the breast (Cooper ligament)**. Malignant infiltration of these ligaments causes fibrosis and shortening, leading to traction on the skin with distortion in breast contour.

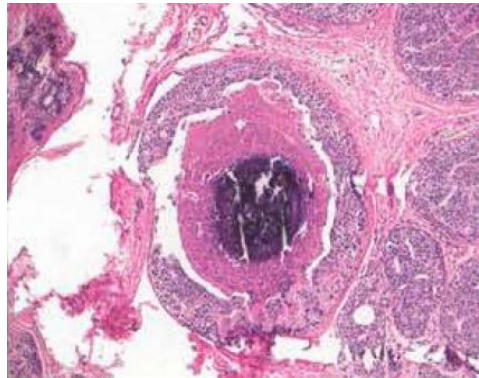


- **Axillary lymph node metastasis** is the most important prognostic factor in early-stage disease.
- **Risk factors:**
  - ↑ Age: Cancer usually arises in **postmenopausal women**, with the notable exception of hereditary breast cancer.
  - Race (Caucasians at highest risk).
  - RCA1/BRCA2 mutations.
  - Important risk factors include nulliparity, obesity, and prolonged hormone replacement therapy, all of which contribute to **increased lifetime estrogen exposure**.
  - Alcohol consumption has a known dose-dependent causal effect on breast cancer. **A decrease in alcohol consumption will reduce risk of breast cancer.**
  - Postmenopausal Obesity (adipose tissue converts androstenedione to estrone).

### Noninvasive carcinomas

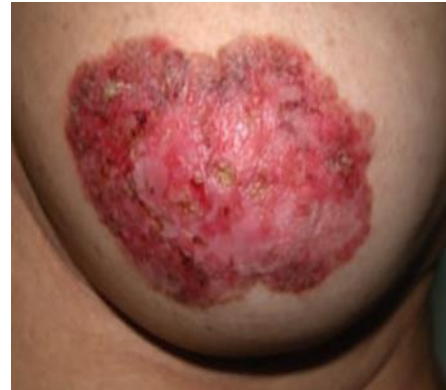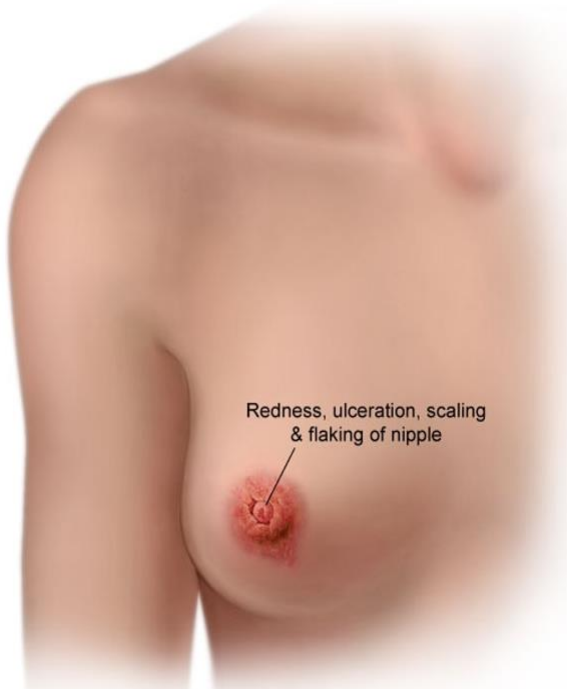#### 1. Ductal carcinoma in situ (DCIS):

- Malignant proliferation of cells in ducts with **no invasion of the basement membrane**.
- Fills ductal lumen (black arrow in indicates neoplastic cells in duct; blue arrow shows engorged blood vessel).
- Often detected as **microcalcifications on mammography**; DCIS **does not usually produce a mass**.
- Mammographic calcifications can also be associated with benign conditions such as **fibrocystic changes** (especially sclerosing adenosis) and **fat necrosis**. Biopsy of calcifications is often necessary to distinguish between benign and malignant conditions.
- Classically, DCIS is divided into five different subtypes: comedocarcinoma, solid, cribriform, papillary, and micropapillary.
- **Comedocarcinoma (DCIS) is characterized by solid sheets of pleomorphic, high-grade nuclei with extensive central necrosis and dystrophic calcification in the center of ducts.**

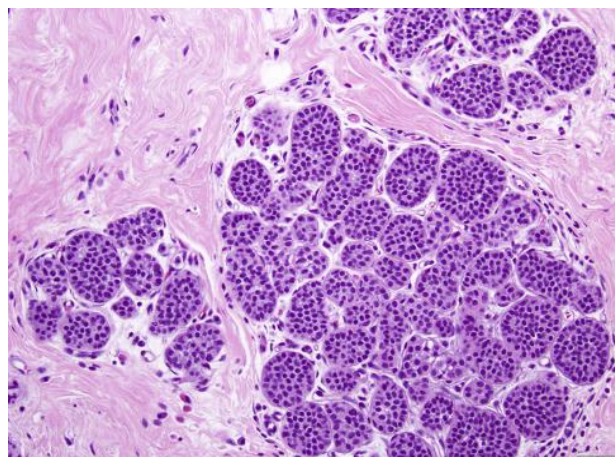


#### 2. Paget disease of the breast:

- Paget disease of the breast is **DCIS that extends up the ducts to involve the skin of the nipple**.
- Presents as **nipple ulceration and erythema (eczematous patches on nipple)**.
- Histology shows Paget cells (intraepithelial adenocarcinoma cells).
- Paget disease of the breast is **almost always associated with an underlying carcinoma (DCIS or IDC)**.

**Mammary Paget disease****3. Lobular carcinoma in situ (LCIS):**

- Malignant proliferation of cells in lobules with **no invasion of the basement membrane**.
- **LCIS does not produce a mass or calcifications and is usually discovered incidentally on biopsy.**
- Characterized by dyscohesive cells **lacking E-cadherin adhesion protein**.
- Often multifocal and **bilateral**.
- **↑ risk of cancer in either breast** (vs DCIS, same breast and quadrant).
- Treatment is tamoxifen (to reduce the risk of subsequent carcinoma) and close follow-up.
- Low risk of progression to invasive carcinoma.

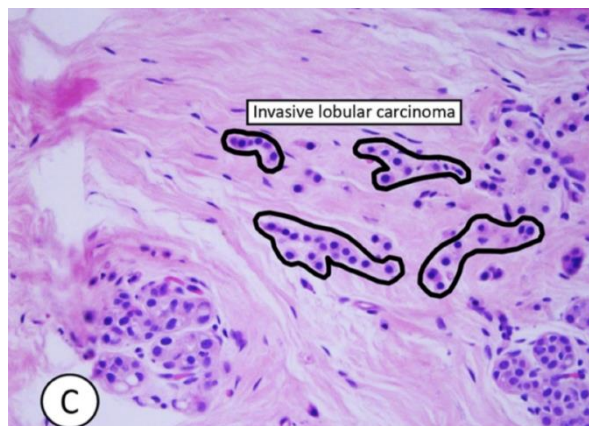


**Invasive carcinomas****1. Invasive ductal carcinoma:**

- Most common type of invasive carcinoma in the breast, accounting for > 80% of cases.
- Presents as Firm, fibrous, "rock-hard" mass with sharp margins duct-like cells in desmoplastic stroma.
- Advanced tumors may result in dimpling of the skin or retraction of the nipple (indicates involvement of Cooper's ligament).

**2. Invasive lobular carcinoma:**

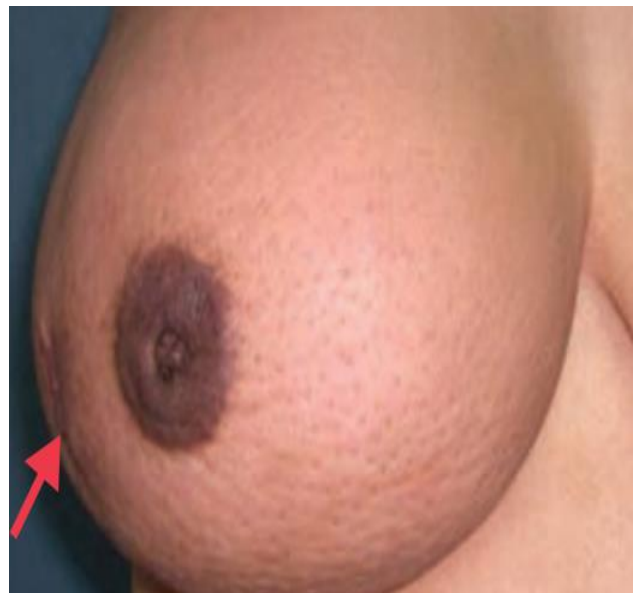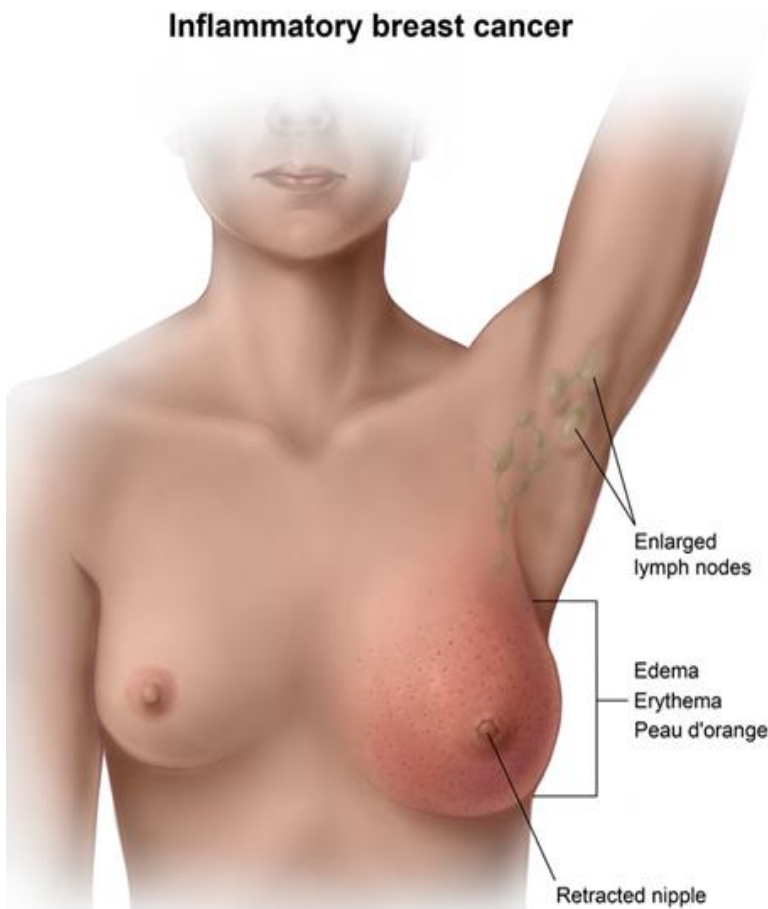
- Invasive carcinoma that characteristically grows in a single-file pattern "Indian file".
- No duct formation due to lack of E-cadherin.
- Often lacks desmoplastic response.
- Often bilateral with multiple lesions in the same location.
- Lines of cells = Lobular.

**3. Medullary carcinoma of the breast:**

- Characterized by large, anaplastic cells growing in sheets with associated lymphocytes and plasma cells.
- Grows as a well-circumscribed mass that can mimic fibroadenoma on mammography.
- Relatively good prognosis.
- Increased incidence in BRCA I carriers.

**4. Inflammatory breast cancer:**

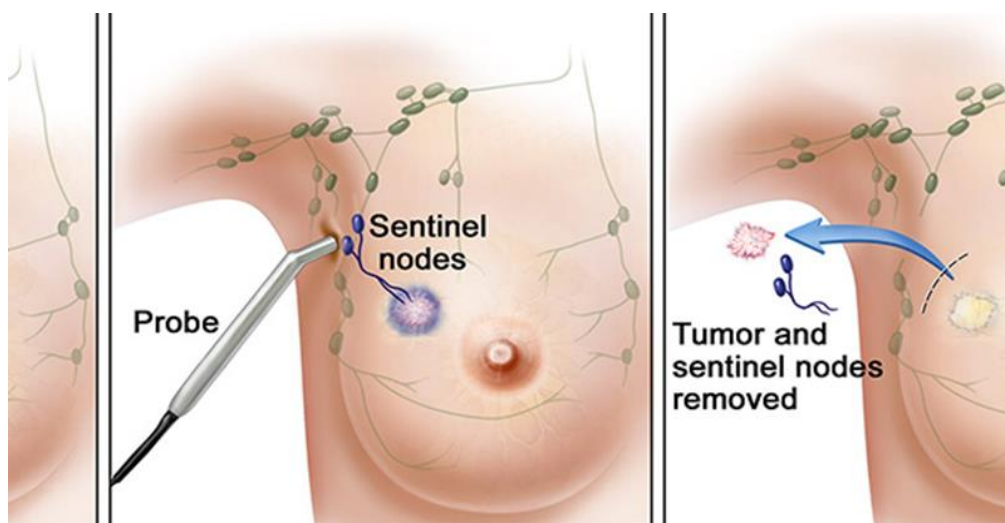
- This is an **uncommon** breast malignancy that can **mimic mastitis**.
- This malignancy causes lymphatic obstruction and tissue swelling when **collections of neoplastic cells plug the dermal lymphatic channels**.
- Diffuse breast erythema, warmth, pain, and edema with a **peau d'orange** (superficial dimpling, fine pitting) appearance are hallmark features of inflammatory breast carcinoma.
- Usually **lacks a palpable mass**.
- Peau d'orange describes **the presence of pitting edema in subcutaneous breast tissue accompanied by skin thickening around exaggerated hair follicles**.
- This is an **aggressive form of breast cancer that may be metastatic on initial presentation**.
- Itching, a palpable breast mass and **nipple changes** (flattening/retraction) may also be present. Patients commonly have **axillary lymphadenopathy** suggesting metastatic disease.
- **Poor prognosis**.

**Inflammatory breast cancer**



### Prognostic and predictive factors

- Prognosis in breast cancer is based on TNM staging.
- Metastasis is the most important factor, but most patients present before metastasis occurs.
- Spread to axillary lymph nodes is the most useful prognostic factor (given that metastasis is not common at presentation); sentinel lymph node biopsy is used to assess axillary lymph nodes.
- Predictive factors predict response to treatment.
- Most important factors are estrogen receptor (ER), progesterone receptor (PR), and the ERB-B2 gene (also called HER2/neu gene) amplification (overexpression) status.
- Presence of ER and PR is associated with response to antiestrogenic agents (tamoxifen), both receptors are located in the nucleus.
- ERB-B2 gene (HER2/neu) amplification is associated with response to trastuzumab (Herceptin), antibody directed against the HER2 receptor.
- HER2/neu is a growth factor receptor present on the cell surface.
- Overexpression of this protein is associated with increased rates of breast and ovarian cancer (accelerates cell proliferation).
- “Triple-negative” tumors are negative for ER, PR, and HER2/neu and have a poor prognosis; African American women have an increased propensity to develop triple-negative carcinoma.





### Hereditary breast cancer

- Represents **10%** of breast cancer cases.
- Clinical features that suggest hereditary breast cancer include:
  - Multiple first-degree relatives with breast cancer.
  - Tumor at an early age (premenopausal).
  - Multiple tumors in a single patient.
- **BRCA 1 and BRCA 2 mutations** are the most important single gene mutations associated with hereditary breast cancer.
- These are tumor suppressor genes that function in **DNA repair and regulation of the cell cycle**.
- BRCA 1 mutation is associated with **breast and ovarian carcinoma**.
- BRCA2 mutation is associated with **breast carcinoma in males**.
- Women with a genetic propensity to develop breast cancer may choose to undergo removal of both breasts (bilateral mastectomy) to decrease the risk of developing carcinoma.
- A small risk for cancer remains because breast tissue sometimes extends into the axilla or subcutaneous tissue of the chest wall.

### Male breast cancer

- Breast cancer is **rare** in males (represents **1%** of all breast cancers).
- Usually presents as a **subareolar mass in older males**.
- Highest density of breast tissue in males is underneath the nipple.
- May produce nipple discharge.
- Most common histological subtype is **invasive ductal carcinoma**.
- Lobular carcinoma is **rare** (the male breast develops very few lobules).
- Associated with **BRCA2 mutations and Klinefelter syndrome**.

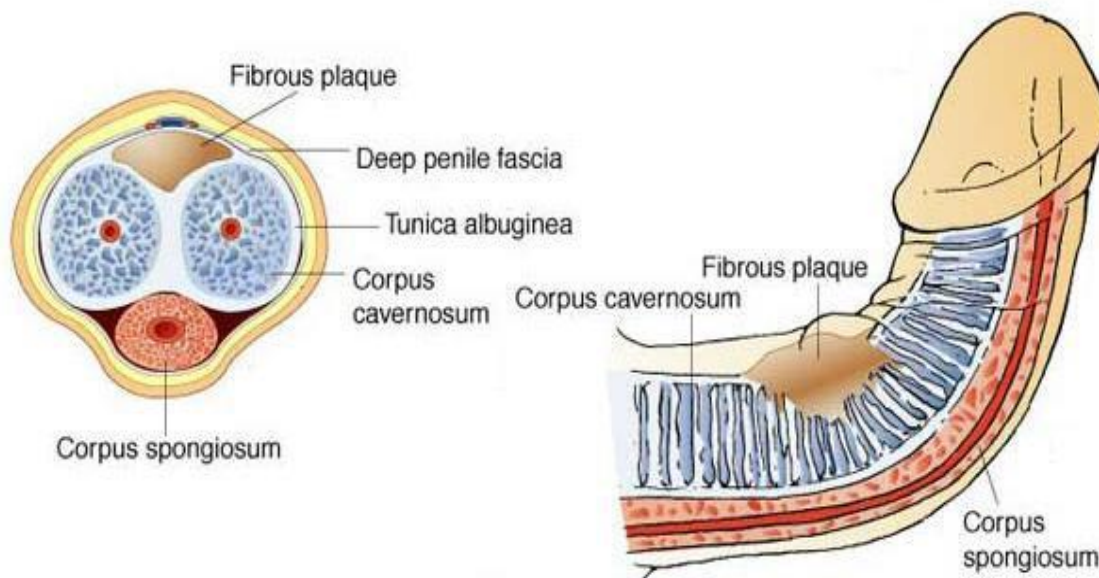
## Gynecomastia

- Refers to the enlargement of the male breast.
  - All cases involve a **relative imbalance between estrogen and androgen at the level of the mammary gland**.
  - Occurs normally (not pathologic) **in the male newborn due to placental transfer of estrogen**. Occurs during **puberty** because of the high estrogen/ androgen ratio in the early stages, and with aging as a result of the increased adipose tissue and increased aromatase activity.
  - Other causes include cirrhosis, hypogonadism (Klinefelter syndrome), testicular tumors, and drugs (**Spiro**nolactone, Hormones, **Cimetidine**, Ketoconazole).
  - “Some Hormones Create Knockers”).
- ❖ In a nutshell:
- Most common breast tumor in women under 25 → Fibroadenoma.
  - Most common breast mass in postmenopausal women → Invasive ductal carcinoma.
  - Most common breast mass in premenopausal women → Fibrocystic change of the breast.
  - Small, mobile, firm mass with sharp edges in premenopausal women → Fibroadenoma.
  - Histological "leaf-like projections" → Phyllodes tumor.
  - Loss of E-cadherin cell adhesion gene → Invasive lobular carcinoma.
  - Commonly present with nipple discharge → Intraductal papilloma.
  - Eczematous patches on the nipple → Paget disease of the nipple.
  - Red, itchy, swollen rash on the areola and nipple → Paget disease of the nipple.
  - Multiple bilateral fluid-filled lesions with diffuse breast pain → Fibrocystic change of the breast.
  - Blue dome cyst in the breast → Fibrocystic change of the breast.
  - Firm, fixed, rock hard mass in postmenopausal women → Invasive ductal carcinoma.

## Penile pathology

## Peyronie disease

- **Abnormal curvature** of penis due to fibrous plaque within tunica albuginea.
- **Associated with erectile dysfunction.**
- Can cause **pain, anxiety.**
- Consider **surgical repair** or treatment with **collagenase injections** once curvature stabilizes.
- Distinct from penile fracture (rupture of corpora cavernosa due to forced bending).

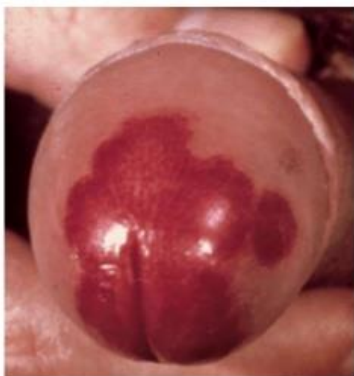

## Ischemic priapism

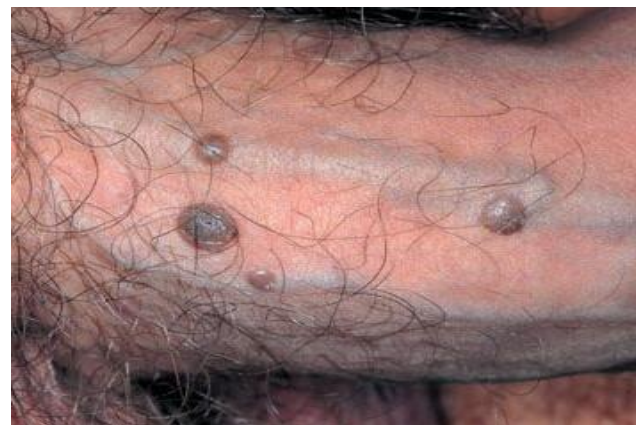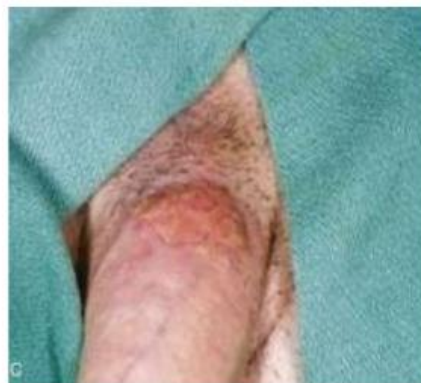- Painful sustained erection lasting > 4 hours.
- Associated with **sickle cell disease** (sickled RBCs get trapped in vascular channels), medications (sildenafil, **trazodone**).
- Treat immediately with corporal aspiration, intracavernosal phenylephrine, or surgical decompression to prevent ischemia.

## Squamous cell carcinoma

- Malignant proliferation of squamous cells of penile skin.
- Seen in the US, but more common in Asia, Africa, South America.
- Risk factors:
  - High risk HPV (2/3 of cases).
  - Lack of circumcision: Foreskin acts as a nidus for inflammation and irritation if not properly maintained.
- Precursor in situ lesions:
  1. **Bowen disease (shaft):** in situ carcinoma of the penile **shaft** that presents as **leukoplakia** (white plaque).
  2. **Erythroplasia of Queyrat (glans):** in situ carcinoma on the **glans** that presents as **erythroplakia** (red plaque).
  3. **Bowenoid papulosis (shaft):**
    - In situ carcinoma that presents as **multiple reddish papules**.
    - Seen in younger patients (40s) relative to Bowen disease and erythroplasia of Queyrat.
    - Does not progress to invasive carcinoma.



Copyright ©2006 by The McGraw-Hill Companies, Inc.  
All rights reserved.



ERYTHROPLASIA OF QUEYRAT

BOWEN'S DISEASE

## Testicular pathology

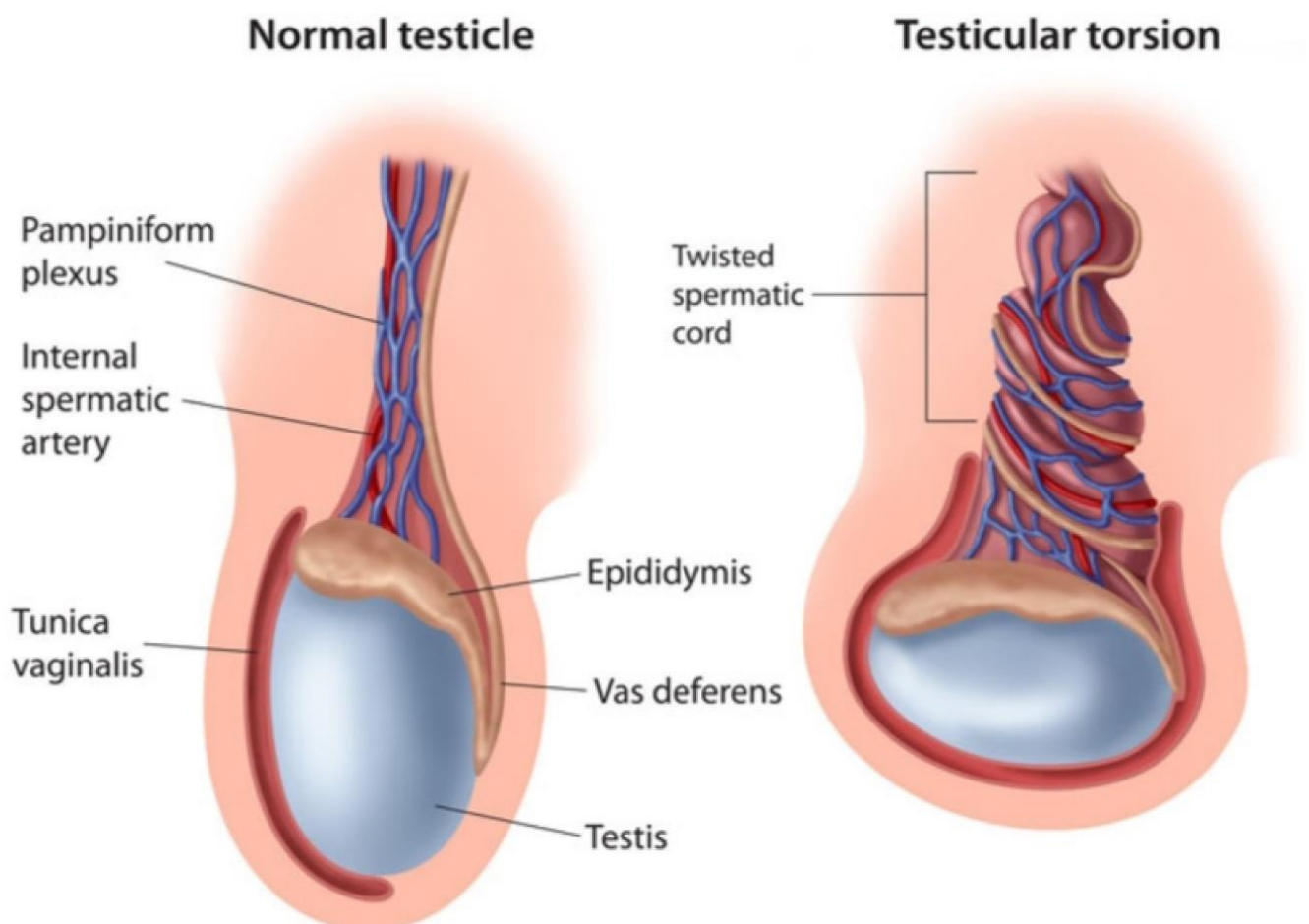
## Epididymitis and orchitis

- Most common causes:
  - **C. trachomatis and N. gonorrhoeae (sexually transmitted infections in young men).**
  - E coli and Pseudomonas (elderly, associated with UTI and BPH).
  - Autoimmune (granulomas involving seminiferous tubules).
1. **Epididymitis:**
    - Inflammation of epididymis.
    - Most cases arise **when pathogens from the urethra travel in a retrograde fashion through the ejaculatory duct to the ductus deferens and epididymis.**
    - Presents with localized pain and tenderness over **posterior testis.**
    - ⊕ Prehn sign (**pain relief with scrotal elevation**).
    - May progress to involve testis.
  2. **Orchitis:**
    - Inflammation of testis.
    - Presents with testicular pain and swelling.
    - Mumps orchitis ↑ infertility risk.
    - Rare in boys < 10 years old.

## Testicular torsion

- **Twisting of the spermatic cord;** thin-walled veins become obstructed leading to congestion and infarction.
- Usually due to congenital failure of testes to attach to the inner lining of the scrotum (via the processus vaginalis).

- Physical examination classically reveals a **profoundly tender, enlarged, high-riding testicle associated with marked scrotal swelling and erythema**. The cremasteric reflex (elevation of the ipsilateral testicle when the inner thigh is stroked) is **absent**.
- Commonly presents in **males 12–18 years old**. May occur after an inciting event (**trauma**) or **spontaneously**.
- This is one of the few **urologic emergencies**, and time wasted doing any tests is tantamount to malpractice.
- The diagnosis is often made **clinically**. However, Doppler ultrasound of the scrotum can be used for confirmation or in case of equivocal findings. It may **demonstrate twisting of the spermatic cord or reduced blood flow**, and a reactive hydrocele may be present.
- Treatment:
  - Surgical correction (orchiopexy) within 6 hours, manual detorsion if surgical option unavailable in timeframe.
  - If testis is not viable, orchiectomy. Orchiopexy, when performed, should be bilateral because the contralateral testis is at risk for subsequent torsion.

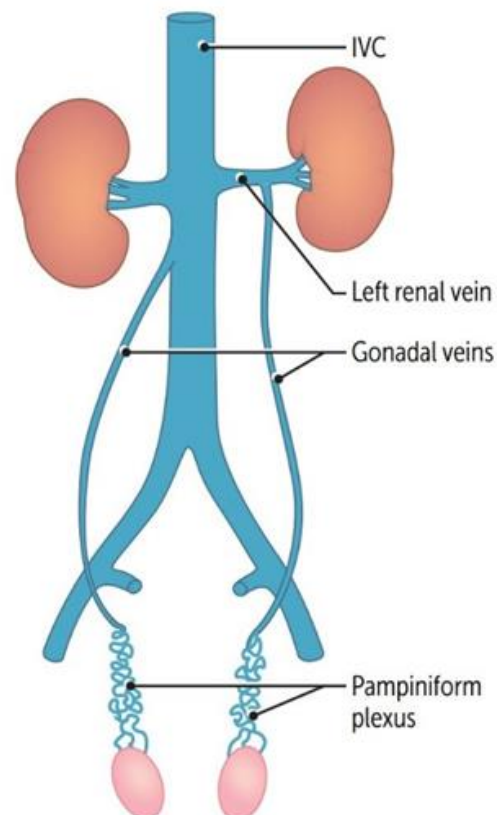
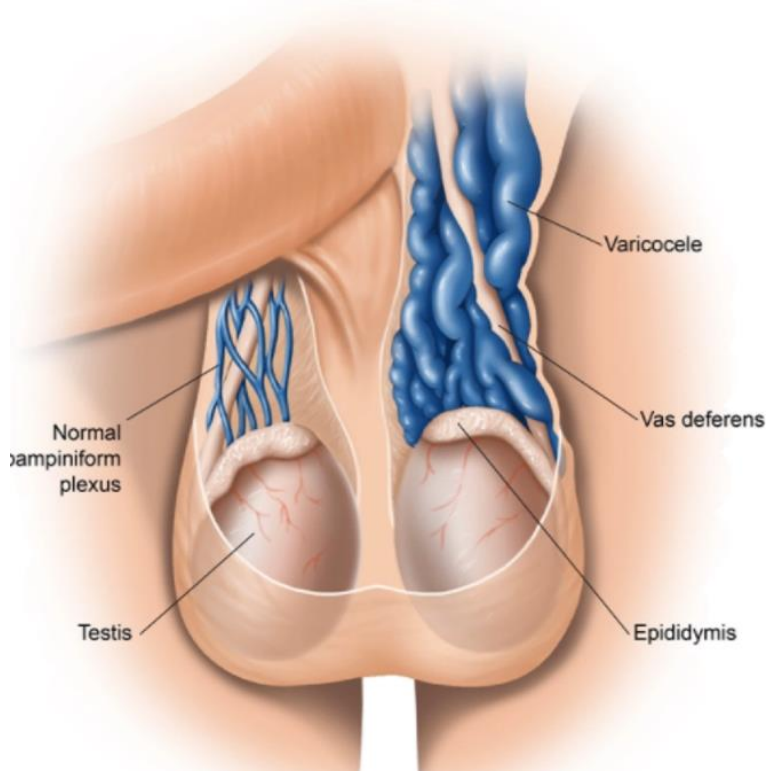




## Varicocele

- A varicocele is a **tortuous dilation of the pampiniform plexus of veins surrounding the spermatic cord and testis**.
- Presents as scrotal swelling that increases in size with standing and Valsalva with a "**bag of worms**" appearance that **does not transilluminate**.
- Varicoceles can cause elevated scrotal temperatures, **increasing the risk for infertility and testicular atrophy**.
- **Varicoceles are more common on the left side**. The left spermatic (gonadal) vein drains to the left renal vein at a 90° angle (flow is less laminar on left than on right), which then passes between the superior mesenteric artery (SMA) and the aorta.
- The left renal vein is vulnerable to compression beneath the SMA ("**nutcracker effect**"), leading to increased pressure in the spermatic vein, incompetence of the valves, retrograde blood flow, and venous dilation.
- Treatment: consider surgical ligation or embolization if associated with pain or infertility.

**Varicocele**

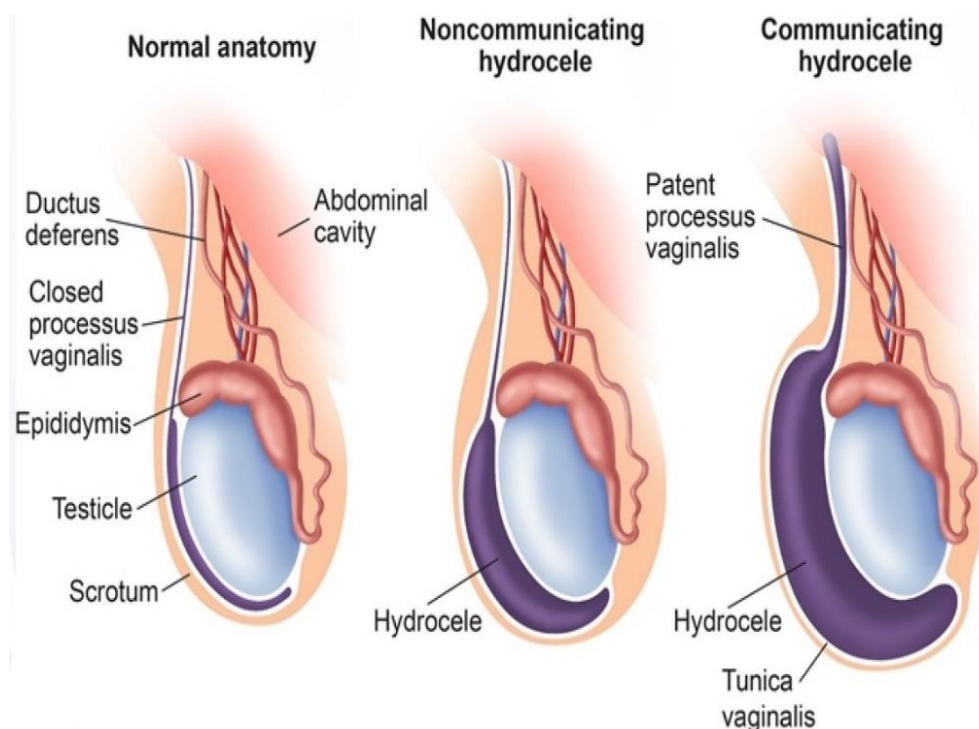


## Cryptorchidism

- Embryologically, the testes originate within the abdomen and then migrate to the scrotal sac via the inguinal canal.
- Undescended testes may be unilateral or bilateral and can lie anywhere along the path from the abdomen to the scrotal sac.
- The temperature inside the scrotal sac is lower than normal body temperature, creating an ideal environment for the seminiferous tubules, which are very temperature sensitive and prone to heat-induced damage.
- Patients with cryptorchidism are at **increased risk for testicular cancer**, especially when orchiopexy (moving the undescended testes into the scrotal sac) is not performed at an early age. Patients whose testes are located intra-abdominally have a higher risk of malignancy compared with those whose testes are located in the inguinal region.
- There is **↓ testosterone in bilateral cryptorchidism** (Leydig cells are mostly unaffected by temperature), **normal in unilateral**, **↓ inhibin but ↑ LH and ↑ FSH** (atrophy/hyalinization of the seminiferous tubules due to **↑ body temperature**).
- If undescended testes are not surgically moved to the scrotal sac, the seminiferous tubules become atrophic and hyalinized overtime, resulting in a **low sperm count** (Sertoli cells are sensitive to **↑ temperature**).
- Because the Sertoli cells are also responsible for the secretion of inhibin, **circulating levels of inhibin decrease as the seminiferous tubules degenerate**. **FSH levels become elevated** due to loss of negative inhibition by inhibin.
- Hormonal function of Leydig cells is usually not impaired. Thus, secondary sexual characteristics and sexual performance are normal.
- **Most cases resolve spontaneously**; otherwise, orchiopexy performed before 2 years of age.

## Congenital Hydrocele

- Hydrocele is a **painless, swollen fluid-filled sac** along the spermatic cords within the scrotum that **transilluminates** upon inspection (**vs varicocele and solid testicular tumors**).
- Hydrocele is a fluid collection within the processus or tunica vaginalis (the peritoneal projection that accompanies the testis during its descent into the scrotum).
- **When the processus vaginalis fails to obliterate, peritoneal fluid may accumulate within the processus vaginalis causing a communicating hydrocele.**
- A collection of fluid within a tunica vaginalis that has properly obliterated its communication with the peritoneum is a noncommunicating hydrocele.
- **Hydrocele can be differentiated from other testicular masses by transillumination;** a hydrocele will transilluminate while other masses will not.
- Most hydroceles, both communicating and noncommunicating, **will resolve spontaneously by the age of 12 months and can be safely observed during that period.**
- Hydroceles that do not resolve spontaneously should be removed surgically **due to the risk of inguinal hernia.**
- **Hydrocele and indirect inguinal hernia are formed by a similar mechanism.** Both conditions are caused by incomplete obliteration of the processus vaginalis. Hydrocele occurs when there is a connection between the scrotum and abdominal cavity that only allows for the leakage of fluid; whereas a hernia occurs when the opening allows the protrusion of abdominal organs along the inguinal canal.

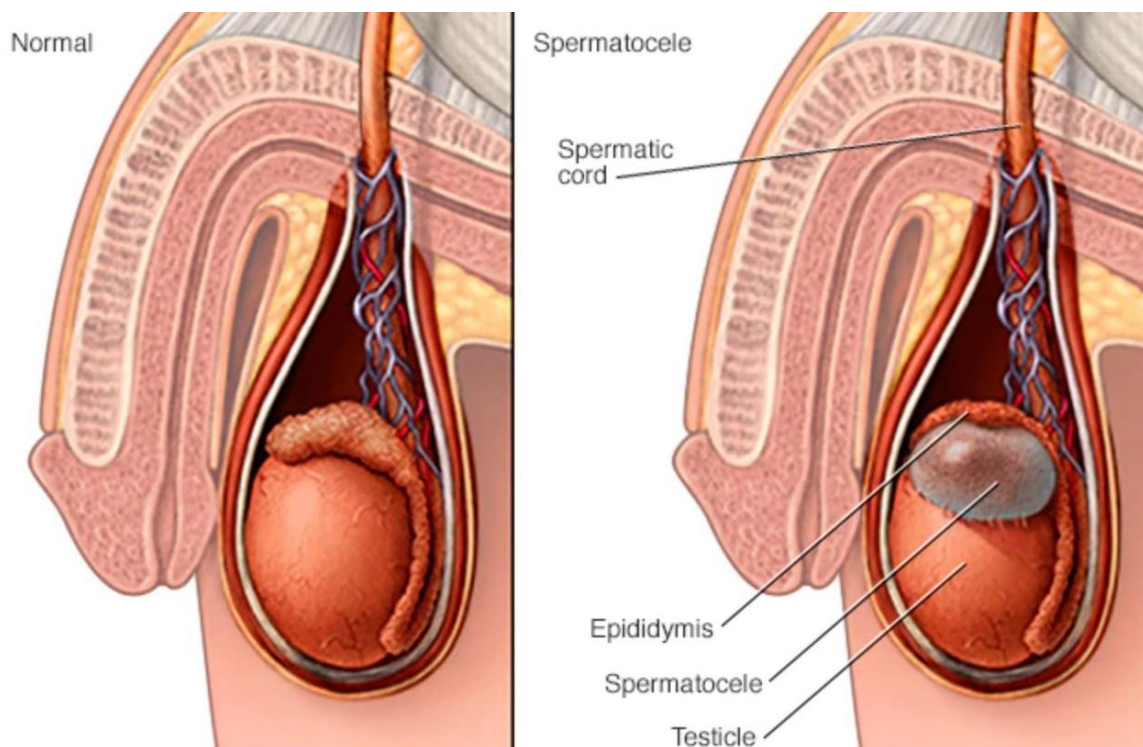


### Acquired hydrocele

- Scrotal fluid collection usually 2° to infection, trauma, tumor.
- If bloody → hematocele.

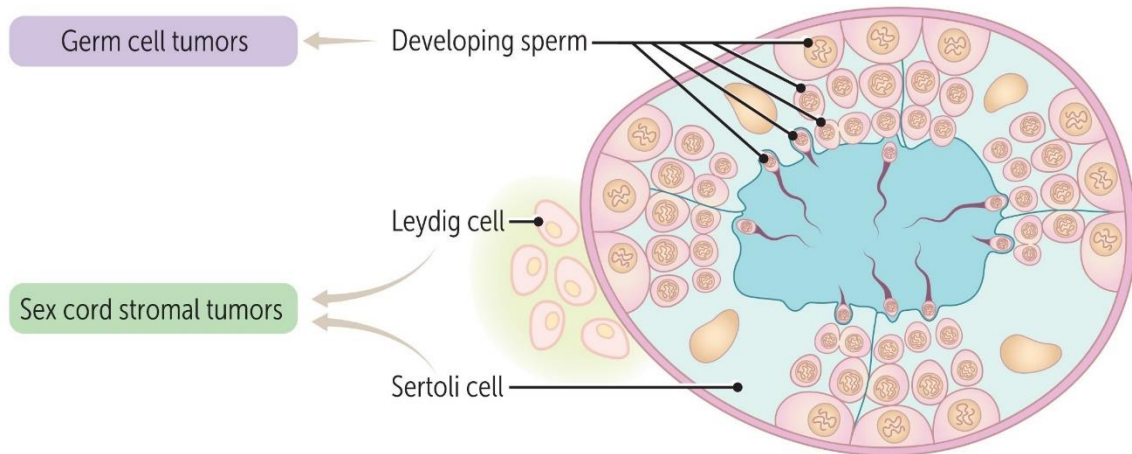
### Spermatocele

- Cyst due to dilated epididymal duct or rete testis.



### Testicular tumors

- Arise from **germ cells or sex cord-stroma**.
- Present as a **firm, painless testicular mass that cannot be transilluminated**.
- Usually not biopsied **due to risk of seeding the scrotum**; removed via **radical orchiectomy**.



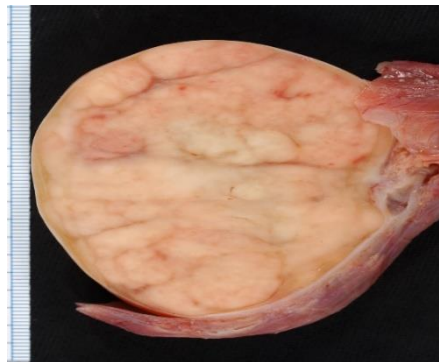### Germ cell tumors

- Most common type of testicular tumor (**account for ~ 95% of all testicular tumors**).
- Arise from germ cells that produce sperm.
- Usually occur in young men (**between 15-40 years of age**).
- Risk factors include **cryptorchidism and Klinefelter syndrome**.
- Mostly **malignant**.
- Divided into seminoma and nonseminoma:
  - Seminomas (55% of cases) are highly responsive to radiotherapy, **metastasize late**, and have an **excellent prognosis**.
  - Nonseminomas (45% of cases) show variable response to treatment and often **metastasize early and** have **variable prognosis**.
- Germ cell tumors are usually **mixed**.



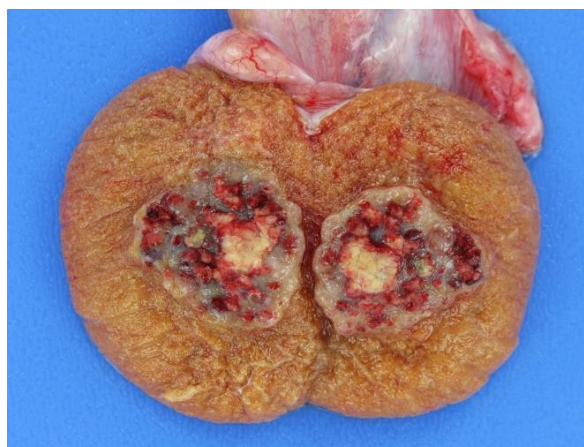### 1. Seminoma:

- Seminoma is a **malignant** tumor comprised of large cells with clear cytoplasm and central nuclei (resemble spermatogonia, "fried egg appearance"; forms a **Painless homogeneous mass with no hemorrhage or necrosis**.
- **Most common testicular tumor; resembles ovarian dysgerminoma.**
- **↑ placental ALP (PALP).**
- Good prognosis; responds to radiotherapy.



### 2. Embryonal carcinoma:

- Embryonal carcinoma is a **malignant** tumor comprised of **immature, primitive cells** that may produce glands; **forms a Painful hemorrhagic mass with necrosis**.
- **"Pure" embryonal carcinoma is rare**; most commonly mixed with other tumor types.
- May be associated with ↑ hCG and normal AFP levels when pure (↑ AFP when mixed).
- **Aggressive with early hematogenous spread (Worse prognosis than seminoma).**
- Chemotherapy may result in differentiation into another type of germ cell tumor (teratoma).





**3. Yolk sac (endodermal sinus) tumor:**

- Yolk sac (endodermal sinus) tumor is a malignant tumor that resembles yolk sac elements (Yellow, mucinous, Analogous to ovarian yolk sac tumor).
- Most common testicular tumor in **children**.
- Schiller-Duval bodies (glomerulus-like structures) are seen on histology.
- **AFP is characteristically elevated**.

**4. Choriocarcinoma:**

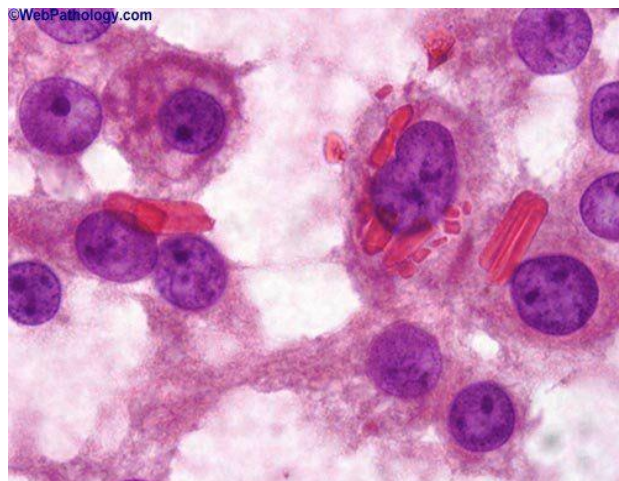
- Choriocarcinoma is a malignant tumor of syncytiotrophoblasts and cytotrophoblasts.
- Spreads early via blood (Hematogenous metastases to lungs and brain).
- **hCG** is characteristically elevated; may lead to **hyperthyroidism or gynecomastia** ( $\alpha$ -subunit of hCG is similar to that of FSH, LH, and TSH)

**5. Teratoma:**

- Teratoma is a tumor composed of mature fetal tissue derived from two or three embryonic layers.
- Unlike in females, **Mature teratoma in adult Males may be Malignant**. Benign in children.

**Sex cord stromal tumors**

- Tumors that resemble sex cord-stromal tissues of the testicle; usually **benign**.
- Leydig cell tumor usually **produces androgen or estrogens**, causing precocious puberty in children or gynecomastia in adults. Characteristic Reinke crystals may be seen on histology.
- Sertoli cell tumor is comprised of tubules and is **usually clinically silent**.



Malignant testicular neoplasms		
<b>Germ cell</b> (95%)	Seminoma	<ul style="list-style-type: none"> <li>Retain features of spermatogenesis</li> <li><math>\beta</math>-hCG, AFP usually negative</li> </ul>
	Nonseminoma	<ul style="list-style-type: none"> <li><math>\geq 1</math> partially differentiated cells: yolk sac, embryonal carcinoma, teratoma, and/or choriocarcinoma</li> <li><math>\beta</math>-hCG, AFP usually positive</li> </ul>
<b>Stromal</b> (5%)	Leydig	<ul style="list-style-type: none"> <li>Often produces excessive estrogen (gynecomastia) or testosterone (acne)</li> <li>Can cause precocious puberty</li> </ul>
	Sertoli	<ul style="list-style-type: none"> <li>Rare</li> <li>Occasionally associated with excessive estrogen secretion (eg, gynecomastia)</li> </ul>

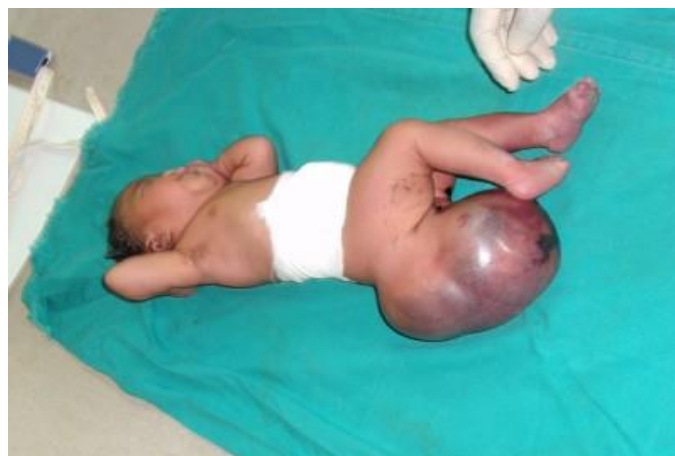AFP = alpha-fetoprotein.

### Testicular lymphoma

- Most common cause of a testicular mass in males > 60 years old; often bilateral.
- Not a 1° cancer; arises from metastatic lymphoma to testes.
- Malignant, aggressive.

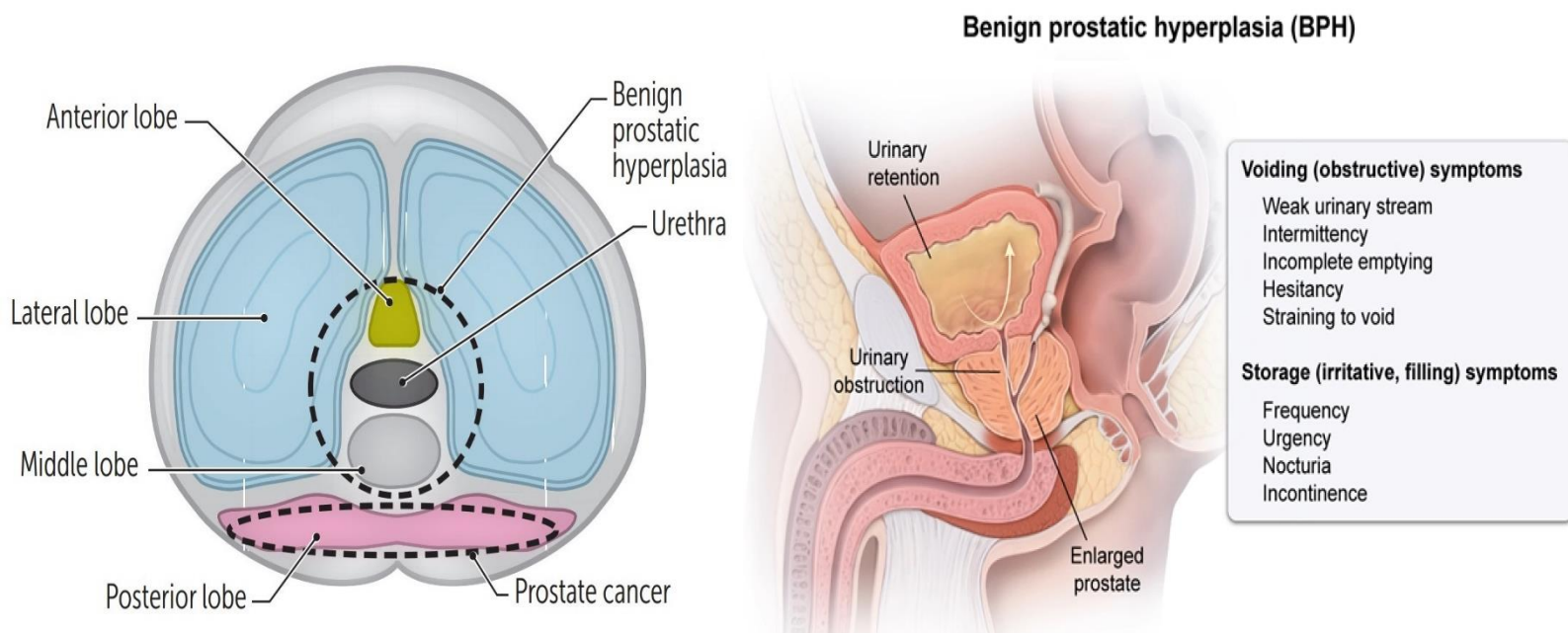
### Extragonadal germ cell tumors

- Arise in midline locations.
- In adults, most commonly in retroperitoneum, mediastinum, pineal, and suprasellar regions.
- In infants and young children, sacrococcygeal teratomas are most common.



## Prostate

- Small, round organ that lies at the base of the bladder encircling the urethra.
- Sits anterior to the rectum; posterior aspect of prostate is palpable by digital rectal exam (DRE).
- Consists of **glands and stroma**.
- **It secretes alkaline, milky fluid** that is added to sperm and seminal vesicle fluid to make semen.

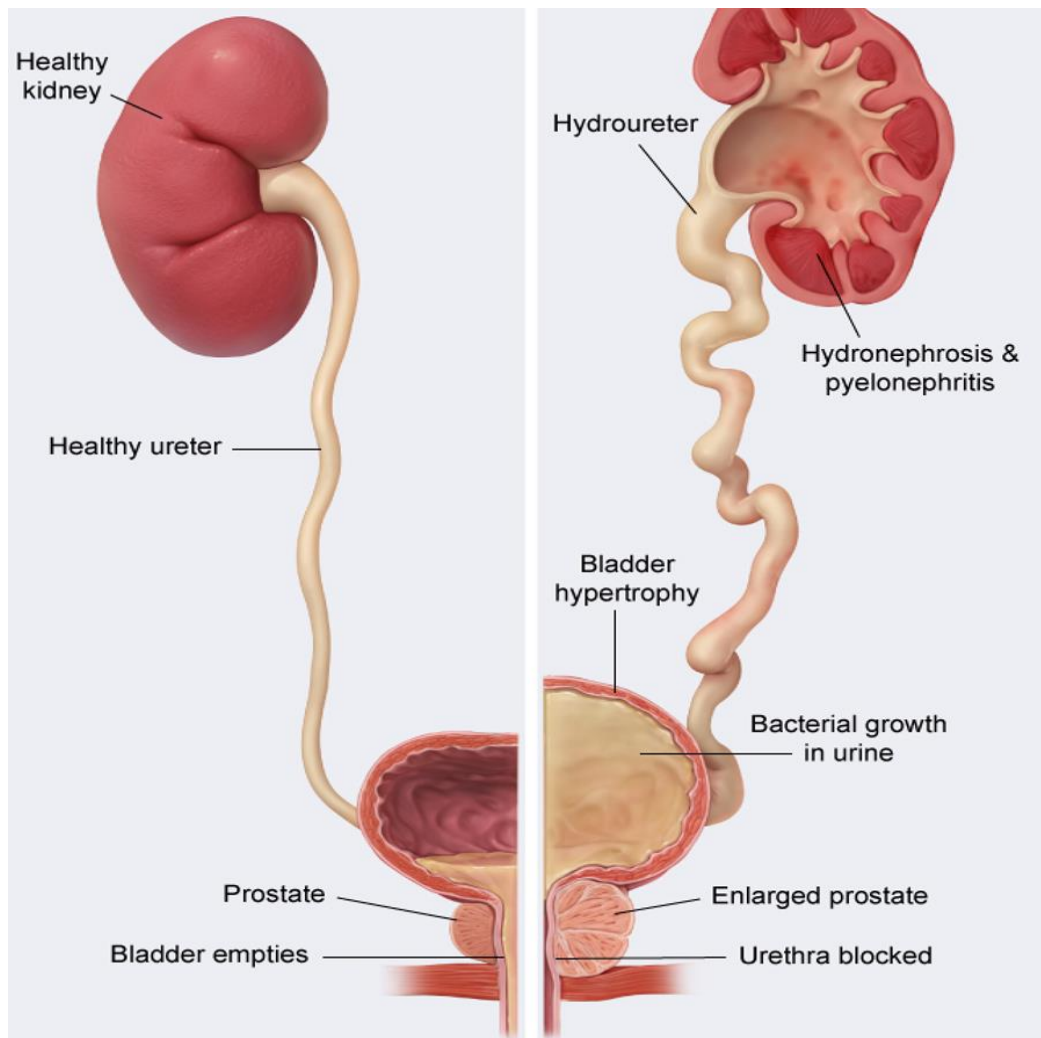


## Prostatitis

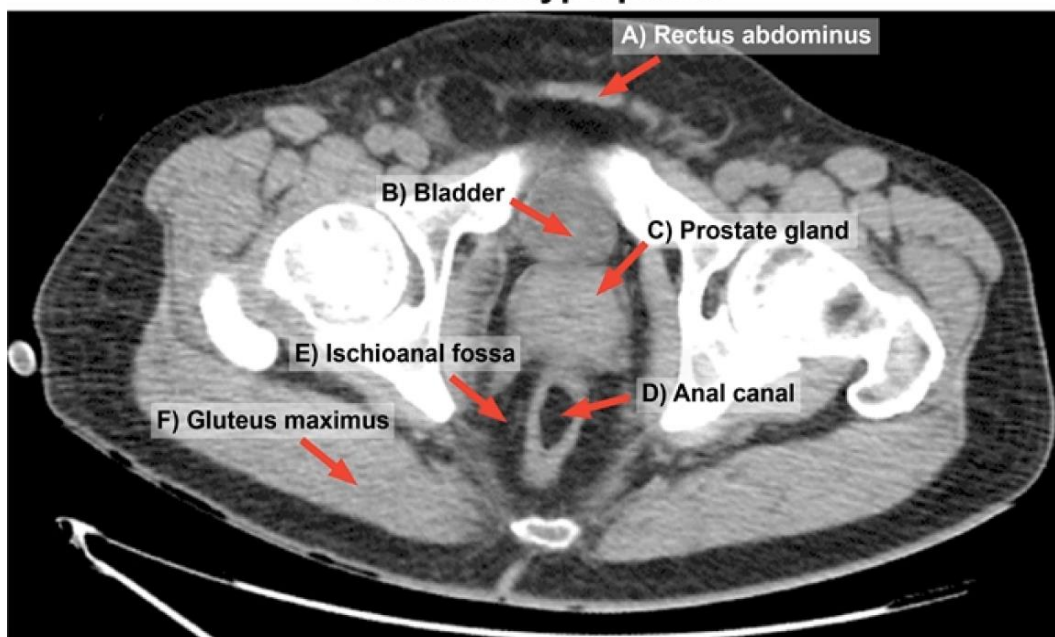
- Characterized by **dysuria, frequency, urgency, low back pain**.
- **Warm, tender, enlarged prostate**.
- Prostate is **tender and boggy on digital rectal exam**.
- **Acute bacterial prostatitis:** **Chlamydia trachomatis** and **Neisseria gonorrhoeae** are common causes in sexually active young adults. **Escherichia coli** and **Pseudomonas** are common causes in older adults.
- **Chronic prostatitis:** either bacterial or nonbacterial (2° to previous infection, nerve problems, chemical irritation).

### Benign prostatic hyperplasia (BPH)

- Hyperplasia of prostatic stroma and glands.
- Age-related change (**present in most men by the age of 60 years**); no increased risk for cancer.
- Related to dihydrotestosterone (DHT):
  - Testosterone is converted to DHT by 5  $\alpha$ -reductase in stromal cells.
  - DHT acts on the androgen receptor of stromal and epithelial cells resulting in hyperplasia.
- Occurs in **the central periurethral and transition zones of the prostate** (lateral and middle lobes), which **compress the urethra into a vertical slit**.
- **Clinical features:**
  - **Urinary complaints are the primary symptoms in BPH**, including urinary hesitancy, urgency, frequency, incomplete voiding, post-void leakage of urine, and nocturia. The residual urine due to incomplete bladder emptying during micturition can **act as a growth medium for pathogenic bacteria and increase the risk for urinary tract infection**.
  - Urinary retention leads to increased pressure in the urinary tract, causing characteristic morphological changes. The bladder wall hypertrophies, to increase its contractile force. **As urinary retention progresses, the ureters, renal pelvis, and calyces dilate and deform, leading to hydronephrosis**.
  - **The renal parenchyma ultimately becomes atrophic and scarred** due to reflux of urine and damage of renal tissue.
  - The condition should be promptly treated, as prolonged obstruction can cause **permanent damage and chronic renal failure**.
  - **Microscopic or gross hematuria** can sometimes arise in patients with BPH due to the **formation of new, friable blood vessels in the area of prostatic hyperplasia**.
- **Management:**
  - Diagnosis is made from the history and physical, including the digital rectal exam. On palpation, the prostate has **a rubbery, smooth consistency, in contrast to prostate cancer, where the gland is nodular and very firm**.
  - Prostate-specific antigen (PSA) is often **slightly elevated** due to the increased number of glands; PSA is made by prostatic glands and liquefies semen.
  - **$\alpha$ 1-antagonists** (terazosin, **tamsulosin**), which cause relaxation of smooth muscle; **5 $\alpha$ -reductase inhibitors** (finasteride) which reduce hormonal influence on the prostate by preventing the conversion of testosterone to dihydrotestosterone.



### Prostatic hyperplasia





## Prostate adenocarcinoma

- Malignant proliferation of prostatic glands.
- **Most common cancer in men**; 2nd most common cause of cancer-related death.
- Risk factors include age, race (**African Americans** > Caucasians > Asians), and diet high in **saturated fats**.
- Prostatic carcinoma is most often **clinically silent**.
- **Usually arises in the peripheral, posterior region of the prostate**, hence, does not produce urinary symptoms early on.
- Because the tumor is located on the periphery of the prostate, it is easily detected on digital rectal examination **as an asymmetric nodular enlargement of the prostate**.
- **Significant elevation** of prostate-specific antigen (PSA) support the diagnosis but are not present in all cases. Confirmation generally requires **transrectal biopsy**.
- **Spread to lumbar spine or pelvis is common; results in osteoblastic metastases that present as low back pain and increased serum alkaline phosphatase** (due to bone metastases), PSA, and prostatic acid phosphatase (PAP).
- Prostatectomy is performed for localized disease; advanced disease is treated with hormone suppression to reduce testosterone and DHT. Continuous GnRH analogs (**leuprolide**) shut down the hypothalamus (LH and FSH are reduced). **Flutamide** acts as a competitive inhibitor at the androgen receptor.
- Prostatectomy may have a slight benefit over radiation in terms of survival. The most common complications of prostatectomy are:
  - **Erectile dysfunction**.
  - **Urinary incontinence**.

Comparison of benign prostatic hyperplasia & prostate cancer		
	BPH	Prostate cancer
<b>Risk factors</b>	• Age >50	• Age >40, <b>African American</b> & family history
<b>Affected part</b>	• <b>Central</b> portion (transitional zone)	• Usually <b>peripheral</b> zone of prostate but can be anywhere
<b>Examination</b>	• Symmetrically enlarged & smooth prostate • Can have elevated PSA	• Asymmetrically enlarged, <b>nodules</b> & firm prostate • Markedly elevated PSA

BPH = benign prostatic hyperplasia; PSA = prostate-specific antigen.



## ❖ N.B:

- Cancers of the pelvis, including the prostate, spread to the lumbosacral spine via the vertebral venous plexus (VVP).
- The VVP communicates with a number of venous networks, including the prostatic venous plexus, which receives the venous supply from the prostate, penis, and bladder.
- It runs up the entire spinal column and connects with the venous supply of the brain via a valveless system, which allows for bidirectional flow and regulation of intracranial pressure.
- This venous connection to the cerebral circulation may help explain the propensity of tumors to metastasize to the brain.

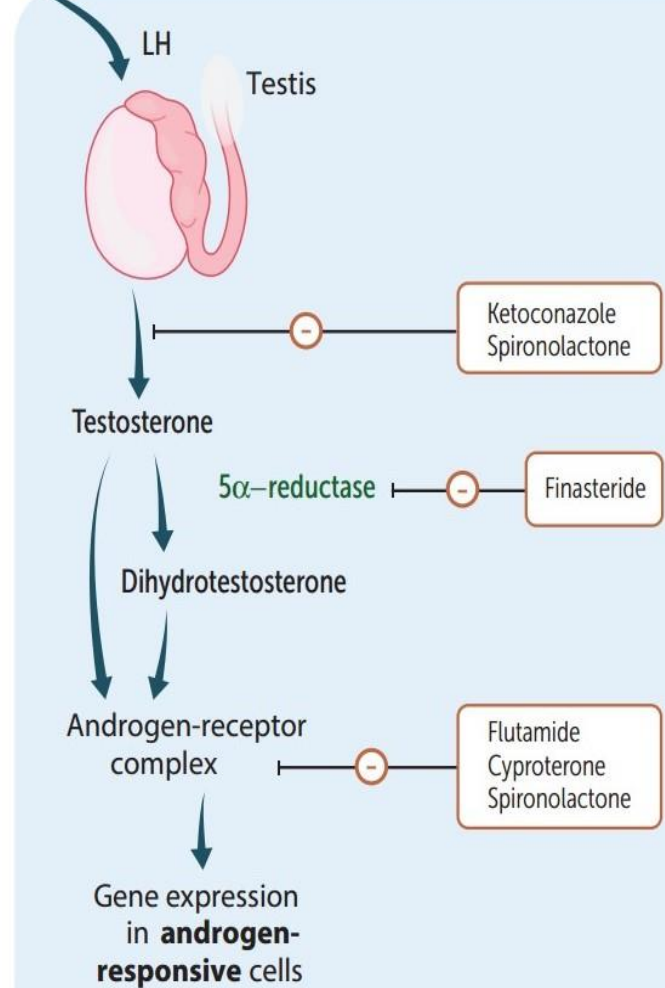
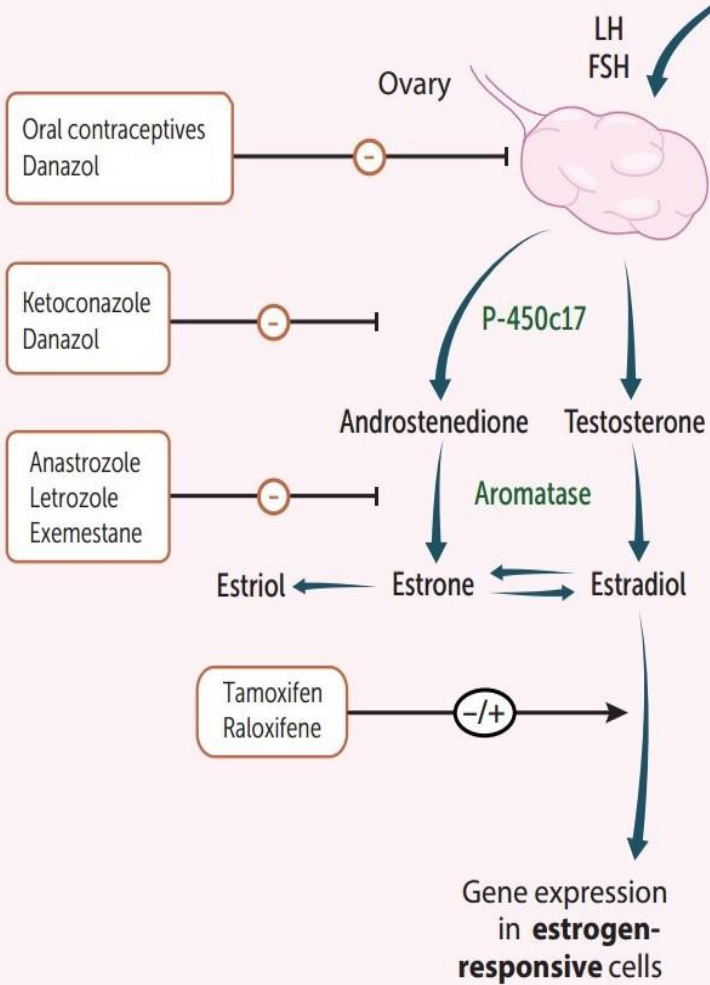
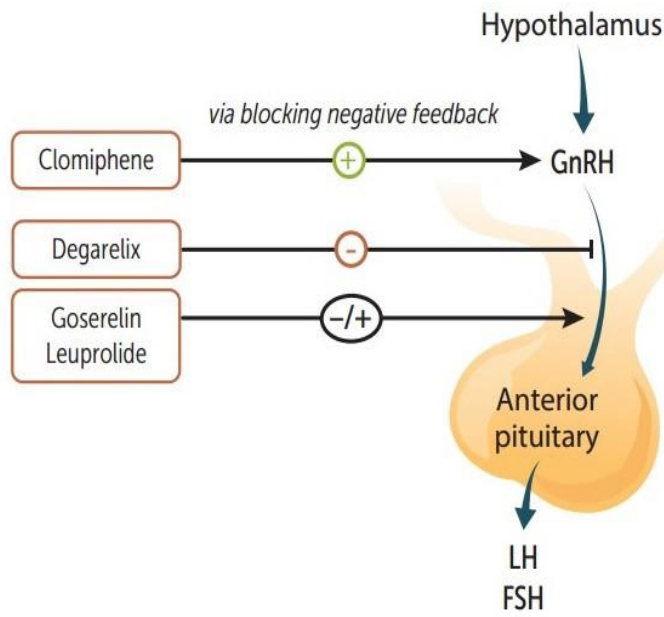
❖ In a nutshell:

- Most common testicular tumor → seminoma.
- Most common testicular tumor in infant and children up to 3yrs of age → yolk sack tumor.
- Most common testicular tumor in men over age 60 → testicular lymphoma.
- Most common cancer in men → prostate cancer.
- Most common cause of urinary obstruction in men → BPH.



## CHAPTER 5

# Pharmacology



### Goserelin, Leuprolide

- Mechanism of action:
  - GnRH analogs.
  - When used in **pulsatile** fashion act as GnRH **agonists**.
  - When used in **continuous** fashion first **transiently act as GnRH agonists (tumor flare)**, but subsequently act as **GnRH antagonists** (downregulate GnRH receptor in pituitary → ↓FSH/LH).
- Clinical use:
  - Uterine fibroids, endometriosis, precocious puberty, **prostate cancer (continuous)**, infertility (pulsatile).
- Adverse effects:
  - Hypogonadism, ↓ libido, erectile dysfunction, nausea, vomiting.

### Degarelix

- Mechanism of action:
  - GnRH antagonist.
  - **No start-up flare.**
- Clinical use: Prostate cancer.
- Adverse effects: Hot flashes, liver toxicity.

### Estrogens

- Drugs: Ethinyl estradiol, DES, mestranol.
- Mechanism of action: Bind estrogen receptors.
- Clinical use:
  - Hypogonadism or ovarian failure, menstrual abnormalities (combined OCPs), **hormone replacement therapy in postmenopausal women (to relieve menopausal symptoms and prevent osteoporosis)**; use in men with androgen-dependent prostate cancer.
- Side effects:
  - **↑ risk of endometrial cancer (when given without progesterone)**, bleeding in postmenopausal women, clear cell adenocarcinoma of vagina in females exposed to DES in utero, **↑ risk of thrombi**.

- Contraindications:
- ER ⊕ breast cancer, history of DVTs, tobacco use in women > 35 years old.

### Selective estrogen receptor modulators

#### A. Clomiphene (Fertility pills):

- Mechanism of action:
- Antagonist at estrogen receptors in **hypothalamus**.
- Prevents normal feedback inhibition and ↑ release of LH and FSH from pituitary, which stimulates **ovulation**.
- Clinical uses: Used to **treat infertility due to anovulation (PCOS)**.
- Side effects:
- May cause **hot flashes**, visual disturbances, ovarian enlargement, **multiple simultaneous pregnancies**.

#### B. Tamoxifen:

- Antagonist at breast; agonist at bone, uterus.
- ↑ **risk of thromboembolic events and endometrial cancer**.
- Used to treat and prevent recurrence of ER/PR ⊕ breast cancer.

#### C. Raloxifene:

- Antagonist at breast, uterus; agonist at bone.
- ↑ **risk of thromboembolic events but no increased risk of endometrial cancer (vs tamoxifen)**; used primarily to treat osteoporosis.

Drug	Bone	Breast	Endometrium
Tamoxifen	Agonist	Antagonist	Agonist
Raloxifene	Agonist	Antagonist	Antagonist

### Aromatase inhibitors

- Drugs: **Anastrozole**, letrozole, exemestane.
- Mechanism of action: **Inhibit peripheral conversion of androgens to estrogen**.
- Clinical use: **ER ⊕ breast cancer in postmenopausal women**.



## Hormone replacement therapy

- Used for relief or prevention of menopausal symptoms (hot flashes, vaginal atrophy), osteoporosis ( $\uparrow$  estrogen  $\rightarrow$   $\downarrow$  osteoclast activity).
- Unopposed estrogen replacement therapy  $\uparrow$  risk of endometrial cancer, so progesterone is added.
- Possible increased cardiovascular risk.

## Progestins

- Drugs:
  - **Levonorgestrel**, **medroxyprogesterone**, etonogestrel, norethindrone, megestrol.
- Mechanism of action:
  - Bind progesterone receptors,  $\downarrow$  growth and  $\uparrow$  vascularization of endometrium, thicken cervical mucus.
- Clinical use:
  - Contraception (forms include pill, intrauterine device, implant, depot injection), endometrial cancer (inhibit hyperplasia), abnormal uterine bleeding (stabilizes endometrium).

## Antiprogesterin

- Drugs: **Mifepristone**, ulipristal.
  - Mechanism of action: **Competitive inhibitors of progestins at progesterone receptors.**
  - Clinical use:
    - Termination of pregnancy (mifepristone with misoprostol); emergency contraception (ulipristal).
- ❖ N.B:
1. Mifepristone is an abortifacient approved by the FDA for clinical use.
    - It can be used for therapeutic abortions up to 49 days after conception.
    - Mifepristone is a **progesterone antagonist** with an affinity for the progesterone receptor five times that of natural progesterone.
    - Progesterone is necessary for implantation and maintenance of pregnancy.
    - When its effects are antagonized by mifepristone, **there is decidual necrosis and expulsion of the products of conception.**
    - Additionally, the anti-progestin effects of mifepristone stimulate the release of endogenous prostaglandins and sensitize the myometrium to the effects of the hormone.
    - The success rate of mifepristone at inducing medical termination of pregnancy is about 80%; however, **the success rate is higher when mifepristone is combined with the prostaglandin analog, misoprostol.**

2. Trastuzumab is a monoclonal antibody used in the treatment of breast cancer caused by tumor cells that overexpress human epidermal growth factor receptor-2 (HER2).
  - By binding to HER2, trastuzumab blocks downstream signaling that promotes cellular proliferation and thereby encourages malignant cell apoptosis.
  - The major adverse effect of trastuzumab is a risk of cardiotoxicity, likely because HER2 signaling plays a role in minimizing oxidative stress on cardiomyocytes and preserving cardiomyocyte function.

### Combined contraception

- Drugs: Progestins and ethinyl estradiol; forms include pill, patch, vaginal ring.
- Mechanism of action:
  - Estrogen and progestins inhibit LH/FSH and thus prevent estrogen surge.
  - No estrogen surge → no LH surge → no ovulation.
  - Estrogen suppress ovulation, progestin prevent implantation.
  - Progestins also inhibit endometrial proliferation → endometrium is less suitable to the implantation of an embryo.
  - Progestins cause thickening of cervical mucus, thereby limiting access of sperm to uterus.
- Side effects:
  - Breakthrough menstrual bleeding, breast tenderness, and weight gain.
  - Additionally, there is a risk of more serious, though rare, events, such as deep vein thrombosis, pulmonary embolism, ischemic stroke, and myocardial infarction.
- Contraindications:
  - Smokers > 35 years old (↑ risk of cardiovascular events), patients with ↑ risk of cardiovascular disease (including history of venous thromboembolism, coronary artery disease, stroke), migraine (especially with aura), breast cancer.
- The absolute contraindications to the use of OCPs are:
  - Prior history of thromboembolic event or stroke.
  - History of an estrogen-dependent tumor.
  - Women over age 35 years who smoke heavily.
  - Pregnancy.

## ❖ N.B:

- ↓ Contraceptive effectiveness when used with enzyme (P450) inducers.

## Copper intrauterine device

▪ Mechanism of action:

- Produces **local inflammatory reaction toxic to sperm and ova, preventing fertilization and implantation;** hormone free.

▪ Clinical use:

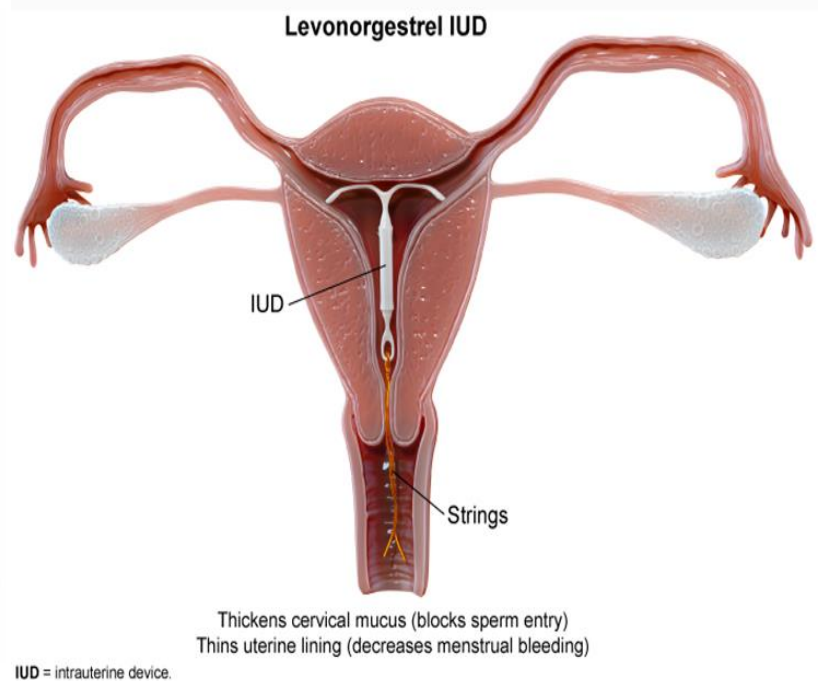
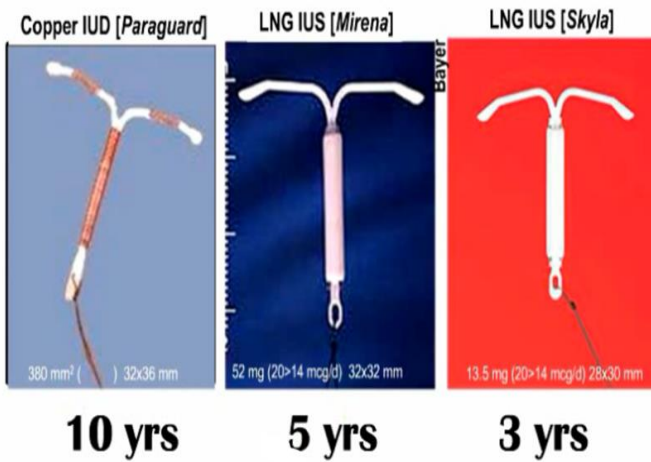
- Long-acting reversible contraception.
- **Most effective emergency contraception.**

▪ Adverse effects:

- Heavier or longer menses, dysmenorrhea.
- Risk of PID with insertion (contraindicated in active pelvic infection).

## Intrauterine Contraception

in the United States (as of January 2013)



## Tocolytics

- Medications that **relax the uterus**; include **terbutaline ( $\beta_2$ -agonist action)**, nifedipine (Ca channel blocker), indomethacin (NSAID).
- Used to ↓ contraction frequency in preterm labor and allow time for administration of steroids (to promote fetal lung maturity) or transfer to appropriate medical center with obstetrical care.

**Danazol**

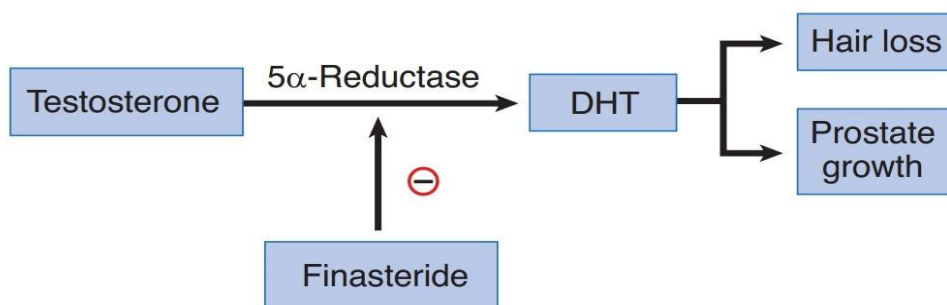
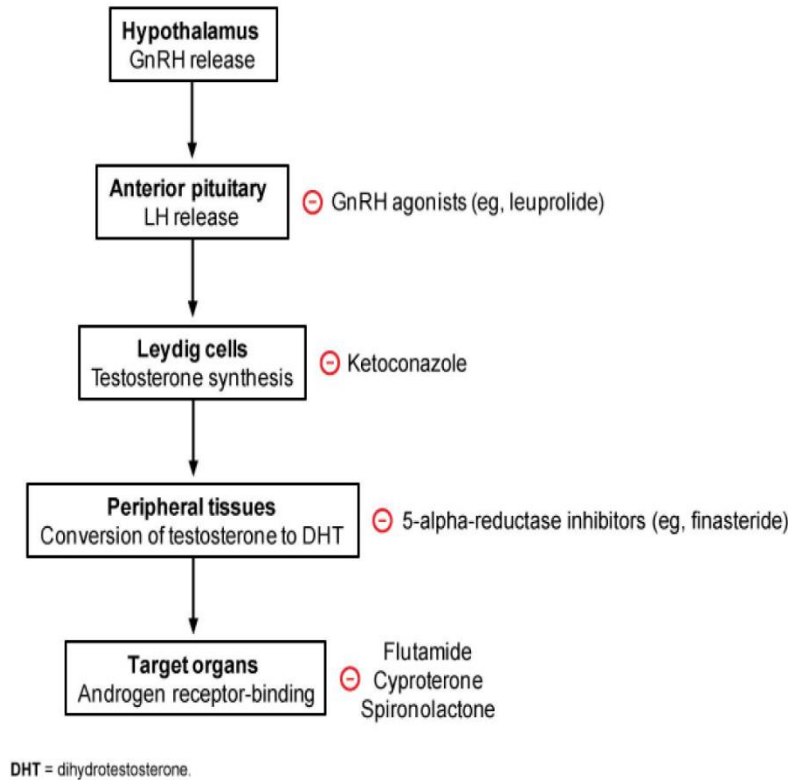
- Mechanism of action:
  - **Synthetic androgen** that acts as partial agonist at androgen receptors.
- Clinical use: Endometriosis, hereditary angioedema.
- Side effects:
  - Weight gain, edema, acne, hirsutism, masculinization, ↓ HDL levels, hepatotoxicity.

**Testosterone, methyltestosterone**

- Mechanism of action: Agonists at androgen receptors.
- Clinical use:
  - Treat hypogonadism and promote development of 2° sex characteristics; stimulate anabolism to promote recovery after burn or injury.
- Adverse effects:
  - Causes masculinization in females; ↓ intratesticular testosterone in males by inhibiting release of LH (via negative feedback) → gonadal atrophy.
  - Premature closure of epiphyseal plates.
  - ↑ LDL, ↓ HDL.

## Antiandrogens

### Antiandrogen therapy



#### A. Finasteride:

- **5α-reductase inhibitor** (↓ conversion of testosterone to DHT).
- **Used for BPH and male pattern baldness.**
- **Adverse effects:** gynecomastia (the excess testosterone is then available for conversion to estrogens by aromatase) and sexual dysfunction.

## B. Flutamide, bicalutamide, apalutamide, enzalutamide:

- Nonsteroidal competitive inhibitor at androgen receptors.
- Used for prostate carcinoma.

## C. Ketoconazole:

- Inhibits steroid synthesis (inhibits 17,20-desmolase).

## D. Spironolactone:

- Inhibits steroid binding, 17 $\alpha$ -hydroxylase, and 17,20-desmolase.

## ❖ N.B:

1. Ketoconazole and spironolactone are used for polycystic ovarian syndrome to reduce androgenic symptoms.
  - Both have side effects of gynecomastia and amenorrhea.
2. Men with prostate cancer who receive androgen-deprivation therapy (orchiectomy, long-acting GnRH agonists, androgen receptor inhibitors) can develop gynecomastia due to dramatic (>95%) reductions in circulating testosterone (with lesser reductions in estrogens).
  - Treatment with tamoxifen, a selective estrogen receptor modulator that acts as an estrogen antagonist in the breast, can reduce the risk of gynecomastia in these patients.

## Tamsulosin

- $\alpha$ 1-antagonist used to treat BPH by inhibiting smooth muscle contraction.
- Selective for  $\alpha$ 1A, D receptors (found on prostate) vs vascular  $\alpha$ 1B receptors (cause orthostatic hypotension).

## Phosphodiesterase type 5 inhibitors

- Drugs:
  - Sildenafil, vardenafil, tadalafil.
  - Sildenafil, vardenafil, and tadalafil fill the penis.
- Mechanism of action:
  - Inhibit PDE-5  $\rightarrow$   $\uparrow$  cGMP  $\rightarrow$  prolonged smooth muscle relaxation in response to NO  $\rightarrow$  blood flow in corpus cavernosum of penis,  $\downarrow$  pulmonary vascular resistance.
- Clinical use: Erectile dysfunction, pulmonary hypertension, BPH (tadalafil only).



- Adverse effects:
  - Headache, flushing, dyspepsia, cyanopia (blue-tinted vision).
  - Risk of life-threatening hypotension in patients taking nitrates.
  - “Hot and sweaty,” but then Headache, Heartburn, Hypotension.

### Minoxidil

- Mechanism of action: Direct arteriolar vasodilator.
- Clinical use: Androgenetic alopecia; severe refractory hypertension.

